LA TETRALOGIE DE FALLOT

1. Généralités
2. Chirurgie du Fallot « régulier »
3. Chirurgie du Fallot « irrégulier »
4. Indications opératoires
5. Autres considérations
6. Conclusion

Histoire du Fallot = histoire de la chir. des congénitaux

- Fallot, 1888
- Blalock, 194
- Palliatif
- Correction c
- Congénitaux

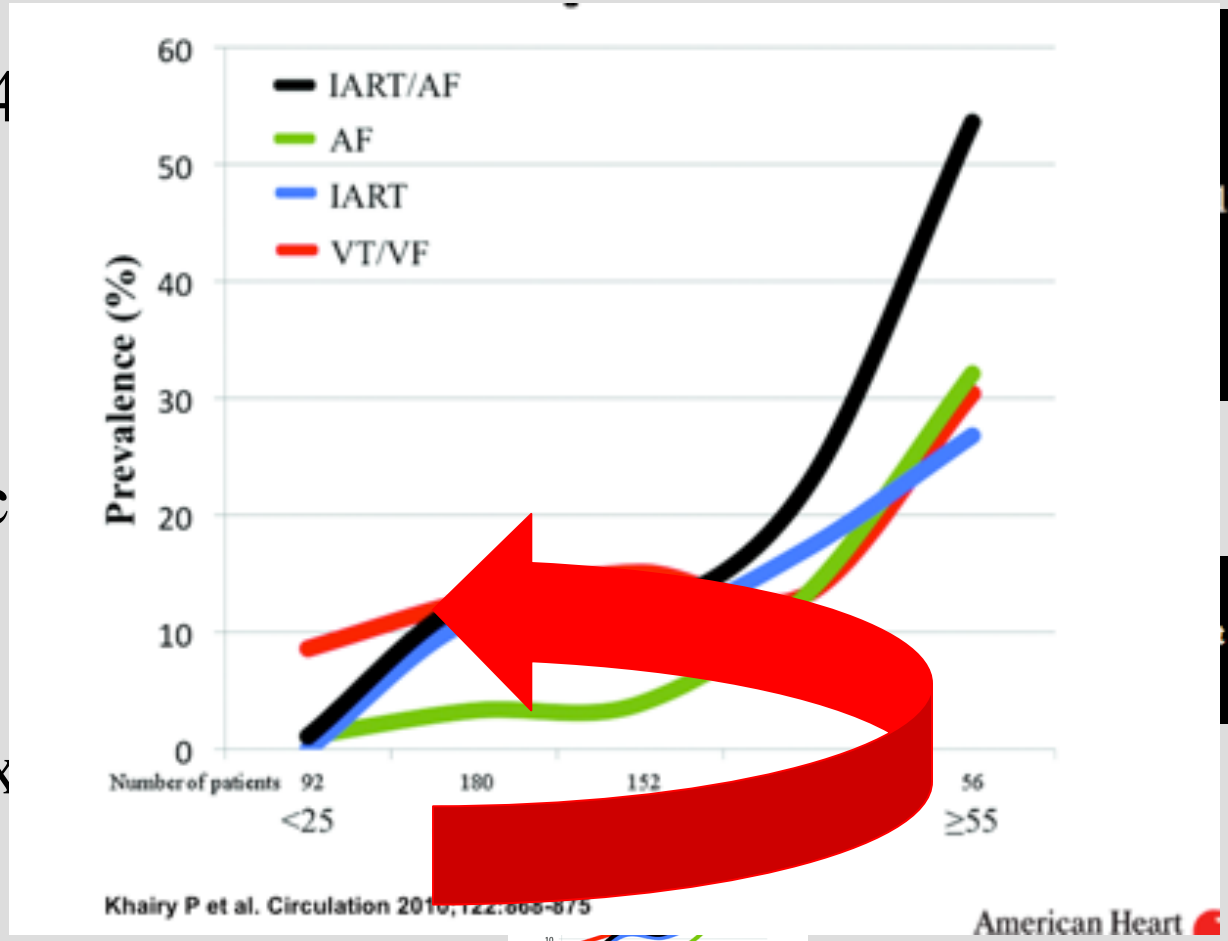

12

pulmonary atresia. J

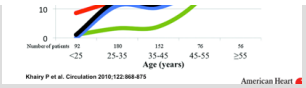

Sténose voie de sortie VD

Dextro-position aortique

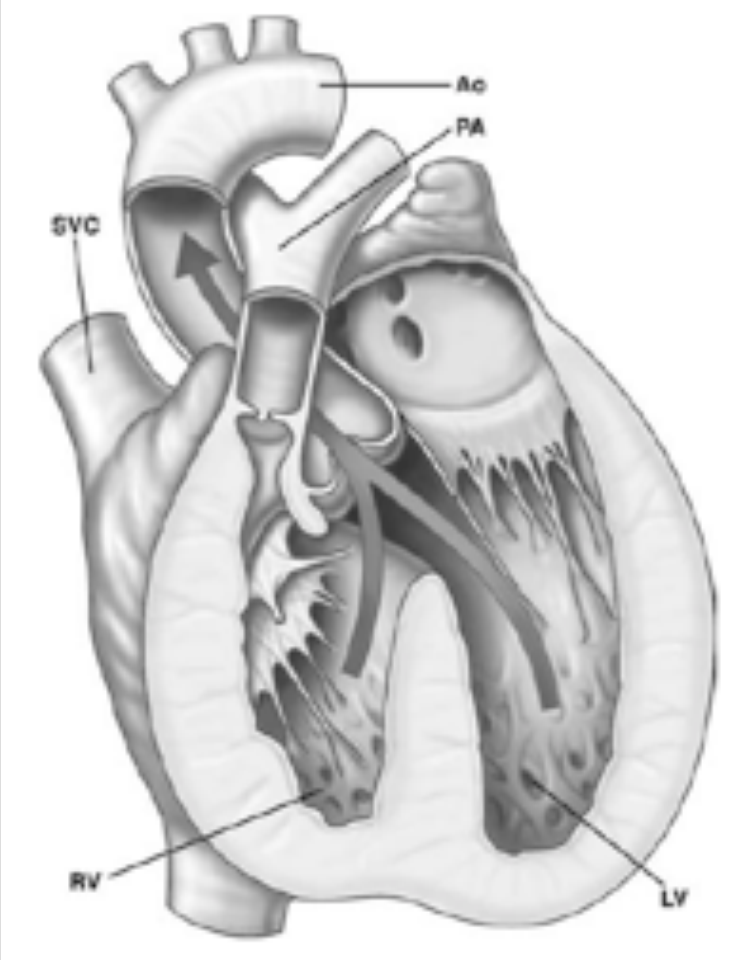

CIV

Hypertrophie VD

La CIV

Unique, périmembraneuse,
par **mal-alignement du septum conal**

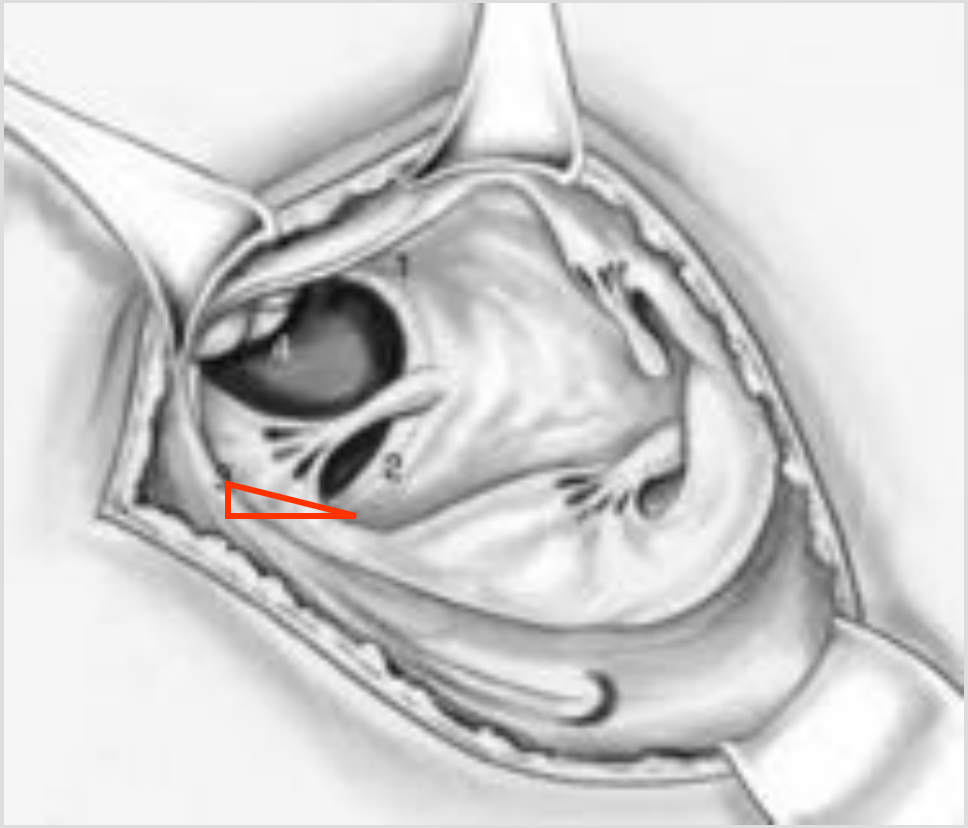

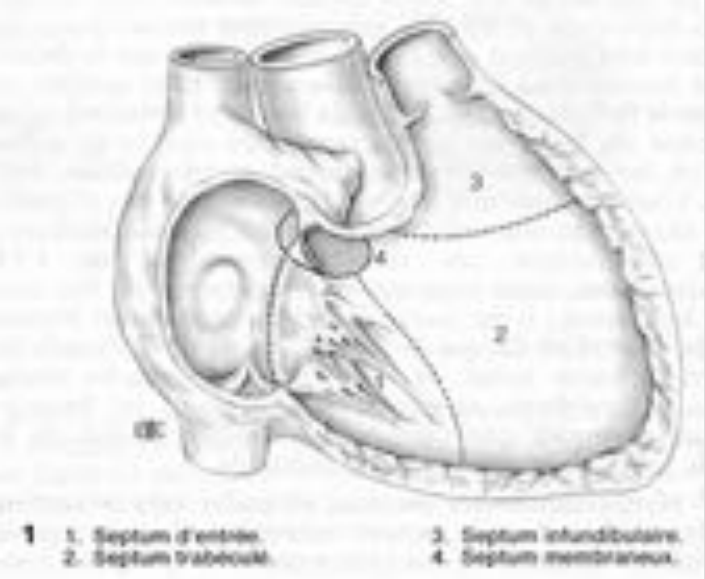

Voie de conduction

La sténose de la voie droite

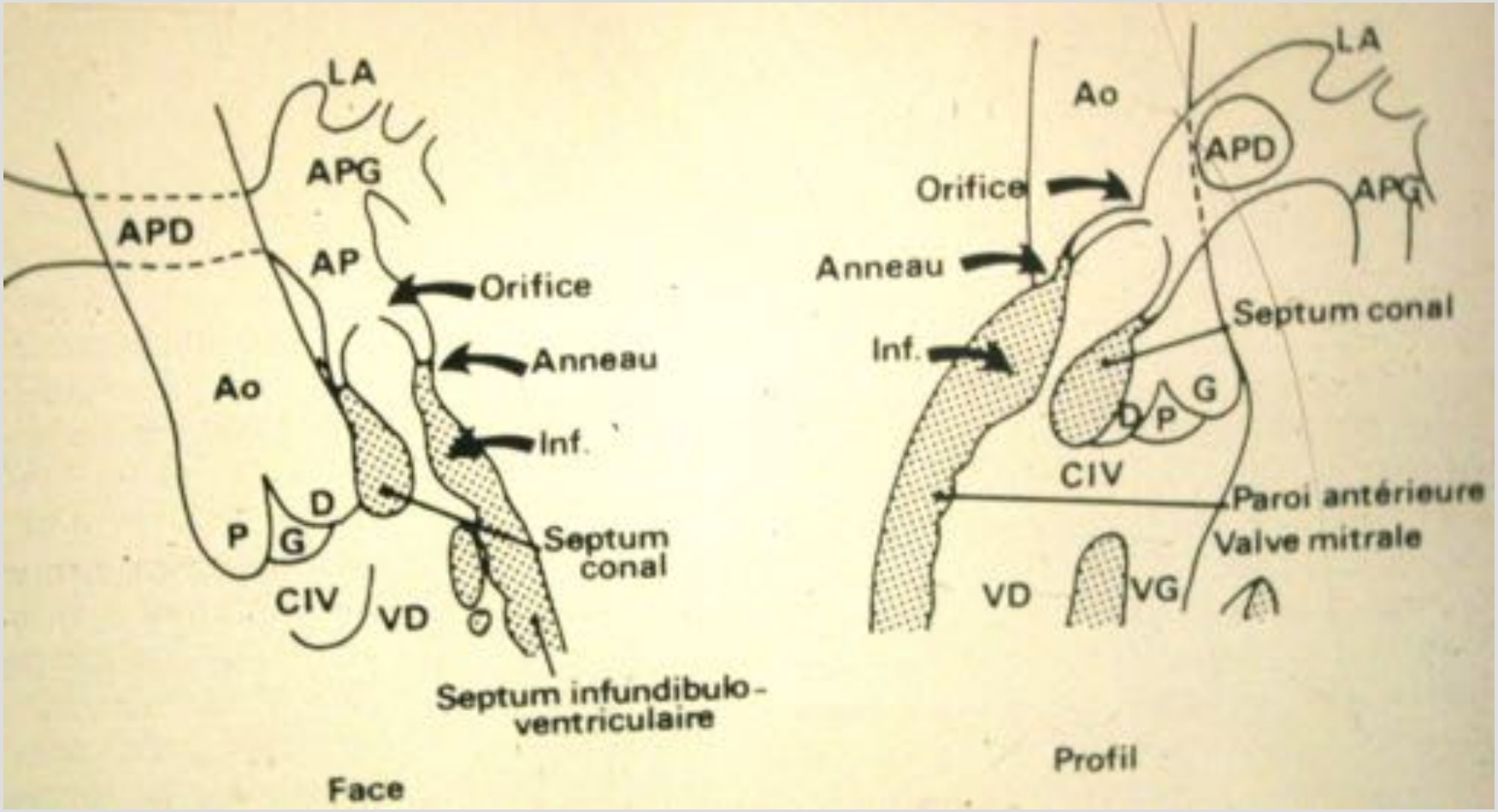

FREQUENCE
Branches
10 %
Tronc
50 %
Valves et anneau
75 %
Infundibulum
70 %

Lésions associées

Anomalie coronaire

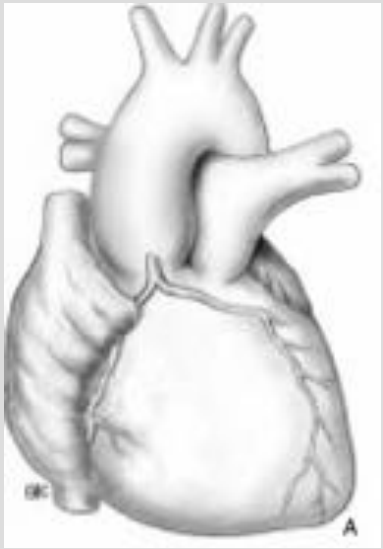

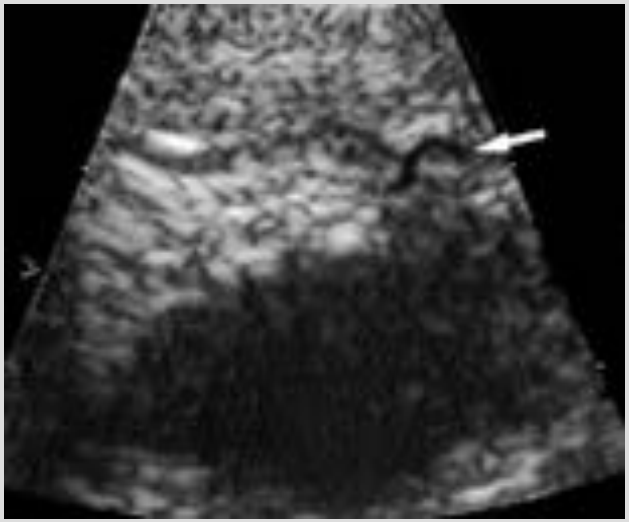

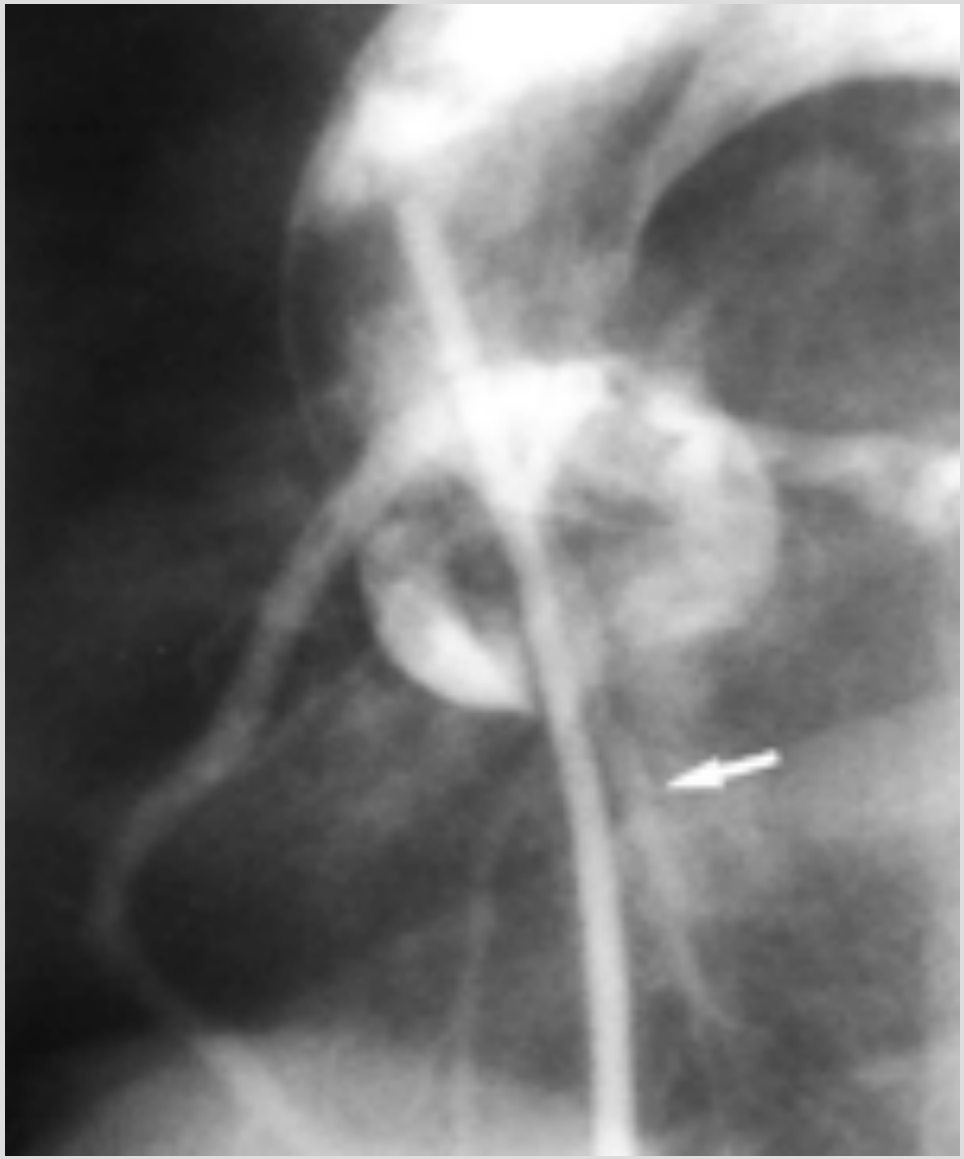

Anomalie coronaire

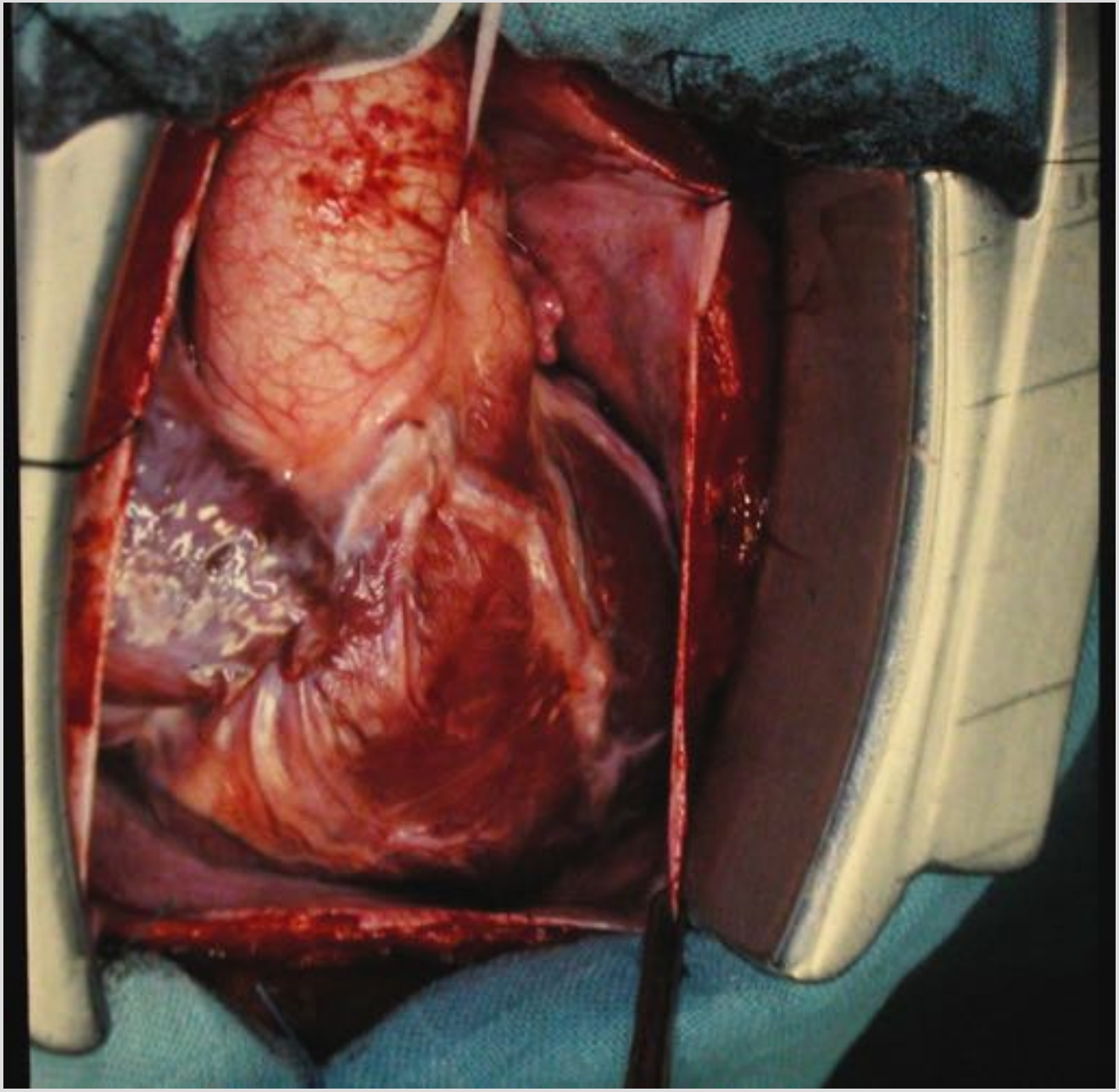

Anomalie coronaire

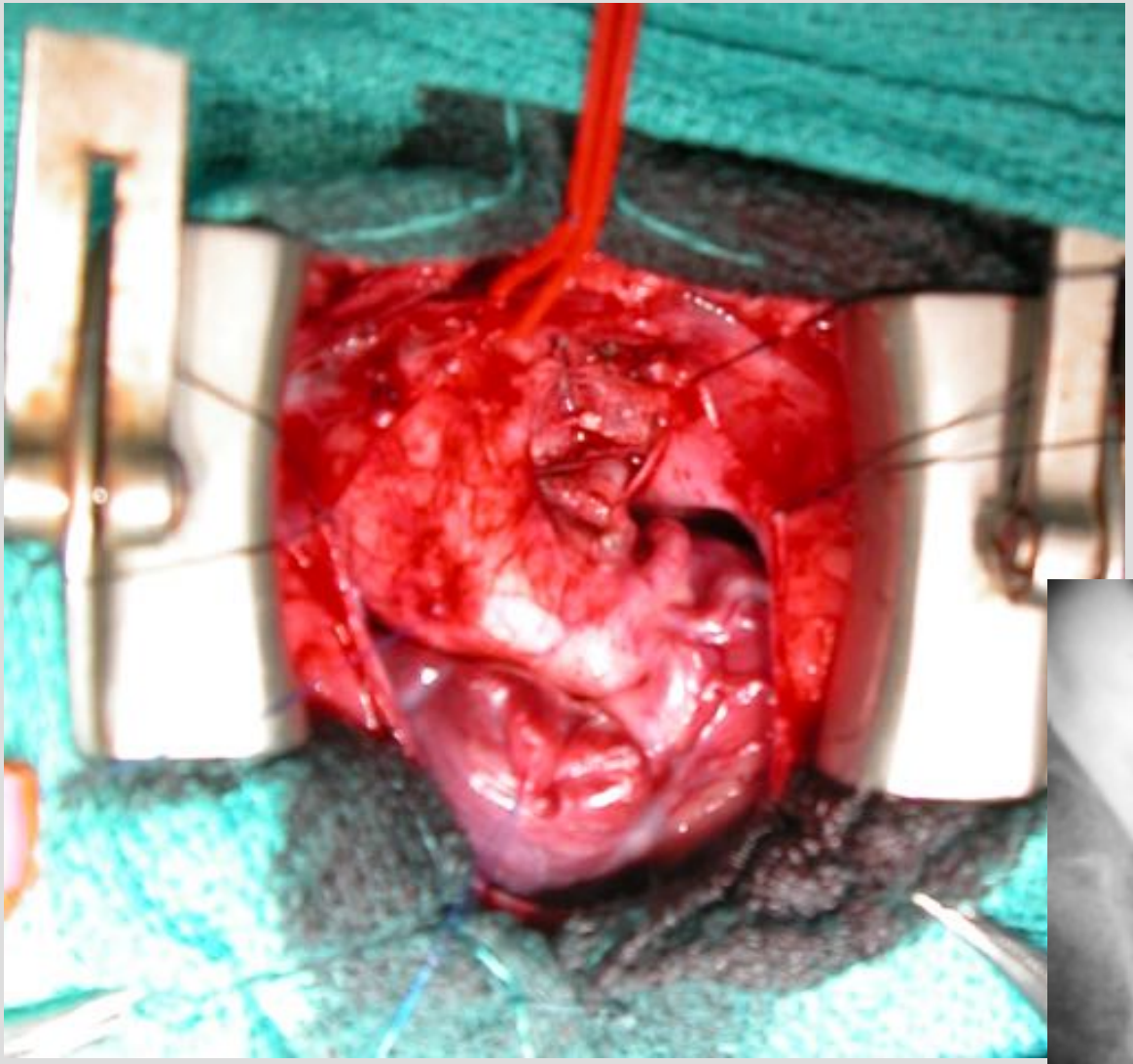

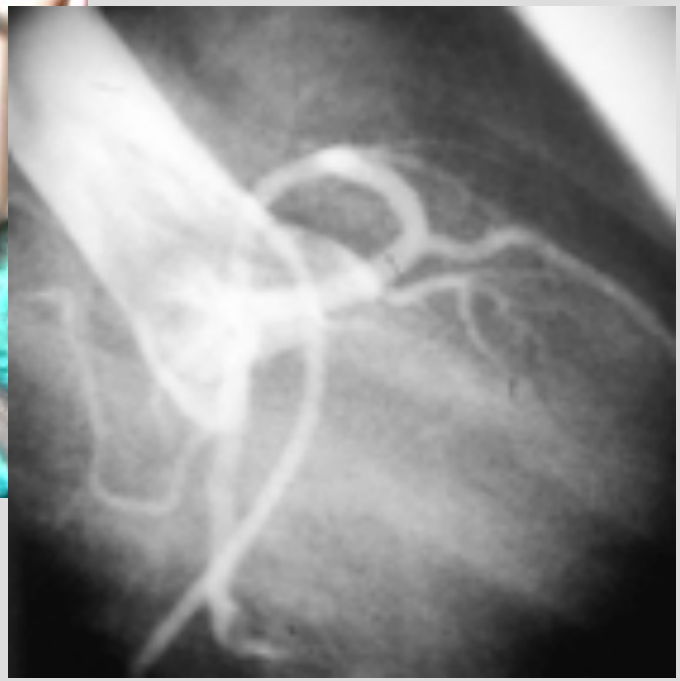

Anomalie coronaire

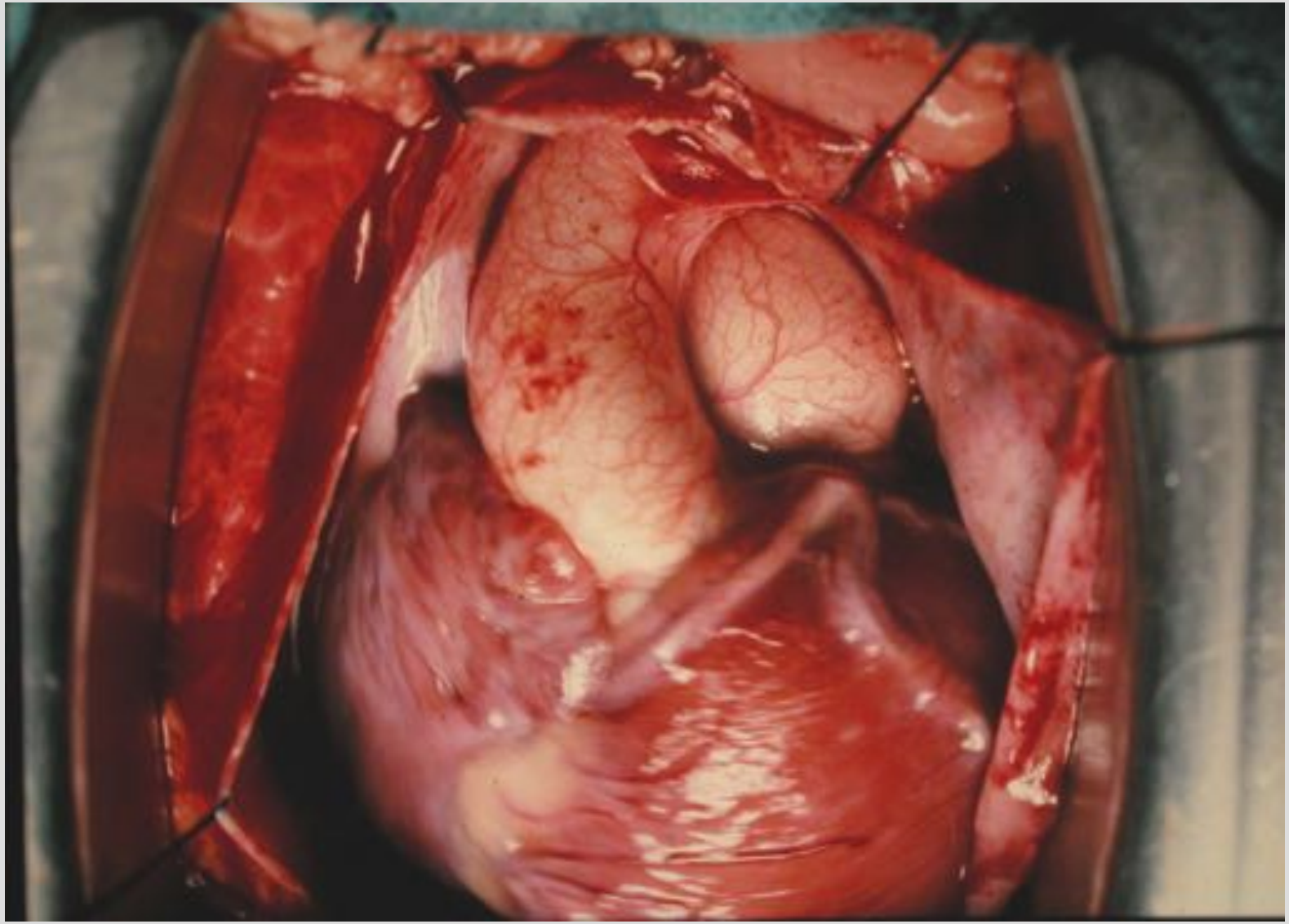

CIV multiples

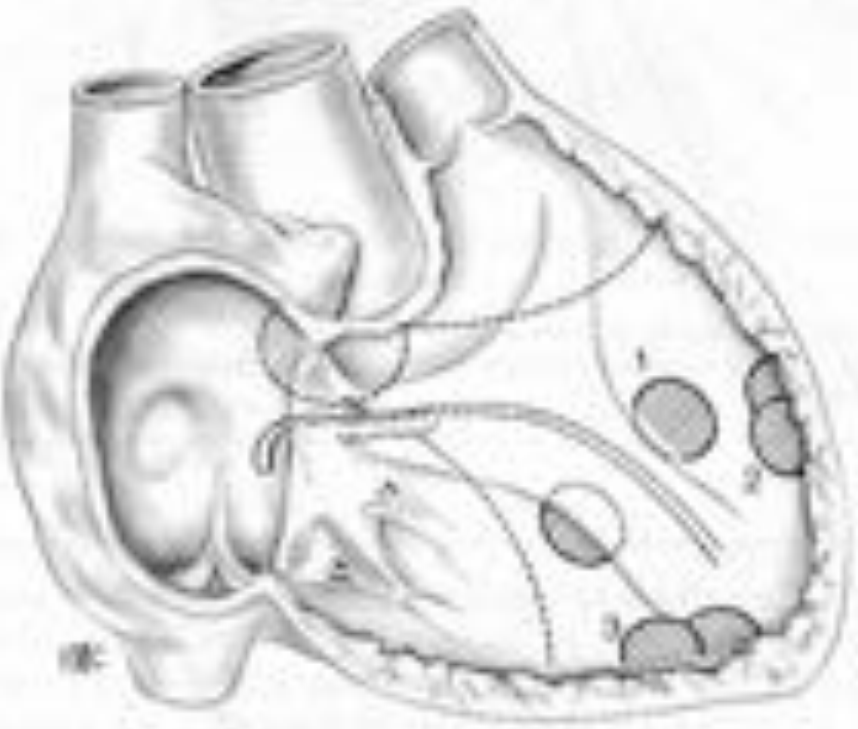

5 Communications interventriculaires (CIV) du septum musculaire trabéculé.
1. CIV musculaires trabéculées centrales.
2. CIV musculaires trabéculées marginales antérieures.
3. CIV musculaires trabéculées marginales postérieures.

Anomalie des branches pulmonaires

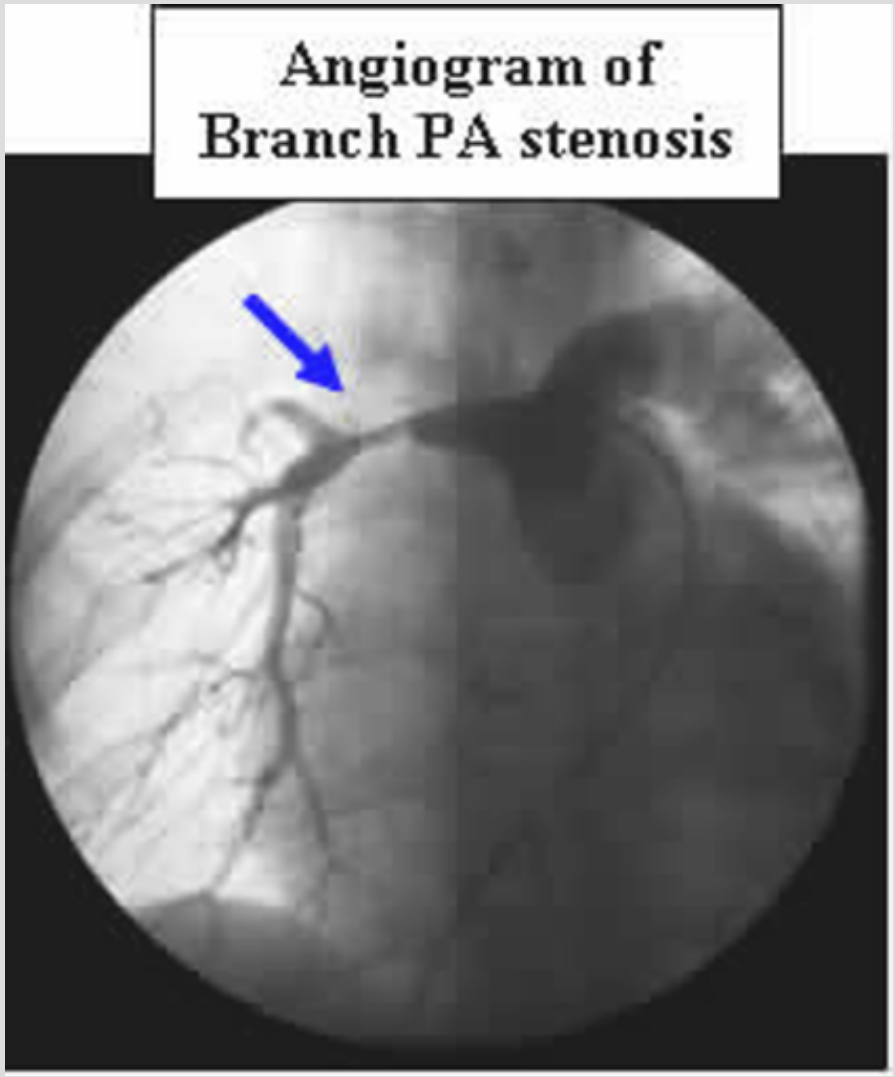

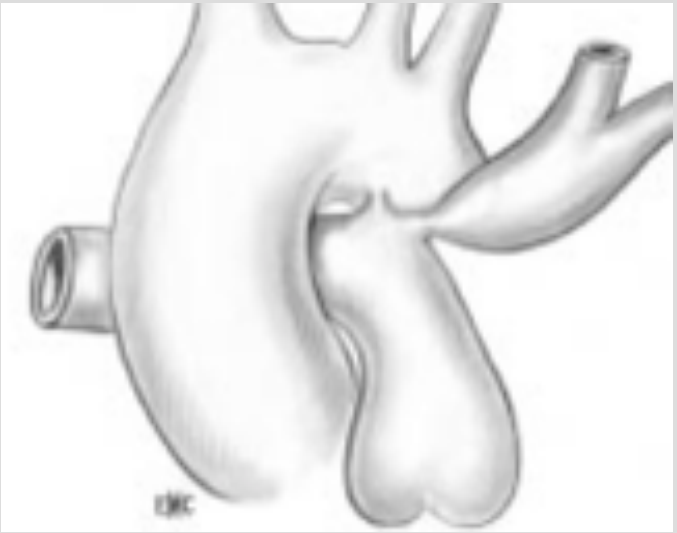

Persistance du canal artériel

CIA

Anomalie des valves atrio-ventriculaires

Crosse Ao. à droite

Veine cave sup. gauche

F4 Agénésie des valves pulmonaires

Anomalies chromosomiques et génétiques

environ 20%

- Microdélétion 22q11
- Trisomie 21
- Anomalies vertébrales, anales, tachéo-oesophagienne

Hypoplasie des artères pulmonaires plus fréquentes chez les enfants syndromiques

Fallot « régulier »

CIV unique

AP belles

Implantation coronaire normale

Fallot « irrégulier »

Principe thérapeutique

- **Traitement palliatif**: anastomose de BT

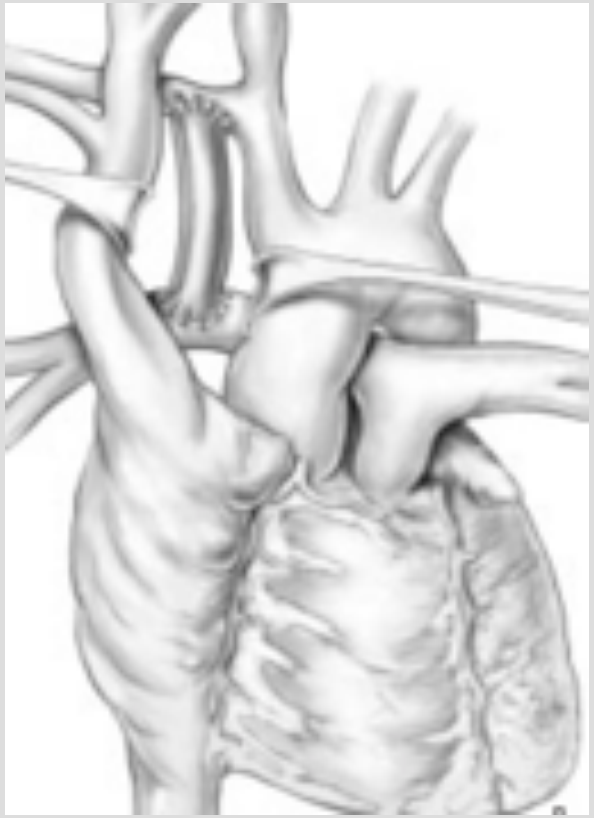

- **Correction complète**: fermeture CIV, ouverture voie de sortie VD

2- chirurgie du Fallot « régulier »

Préambule: préparation anesthésique et chirurgicale concomitantes

hyper-réactivité infundibulaire,
éviter un malaise anoxique

- **Sternotomie prudente**
- Thymectomie
- prélèvement d'un patch de péricarde autologue
- Inspection soigneuse du massif cardiaque
- Canulation aortique et veineuse (x2)
- Contrôle éventuel d'une anastomose palliative

Fermeture de la CIV

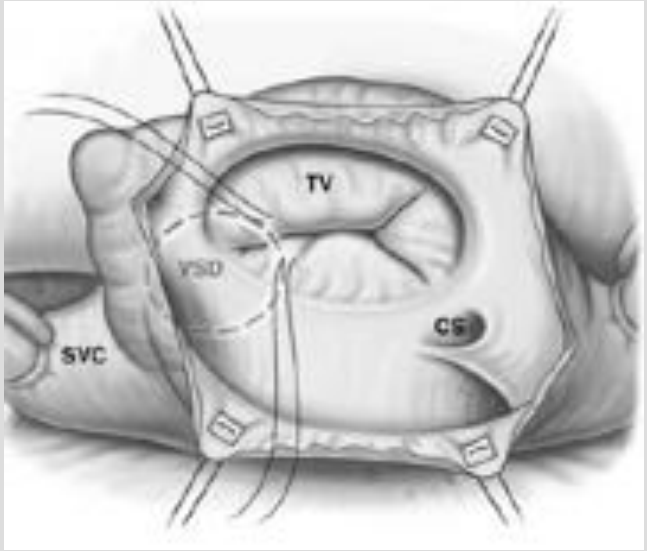

Élargissement de la voie droite

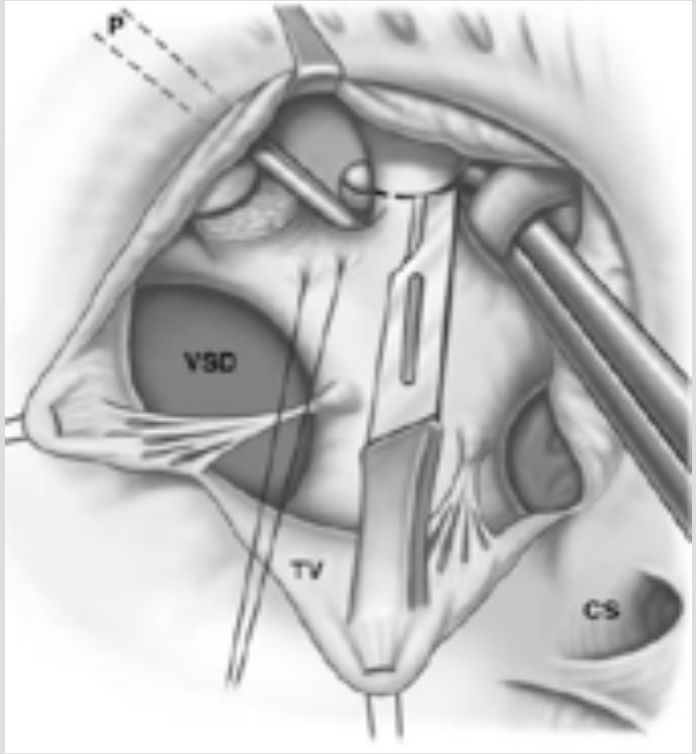

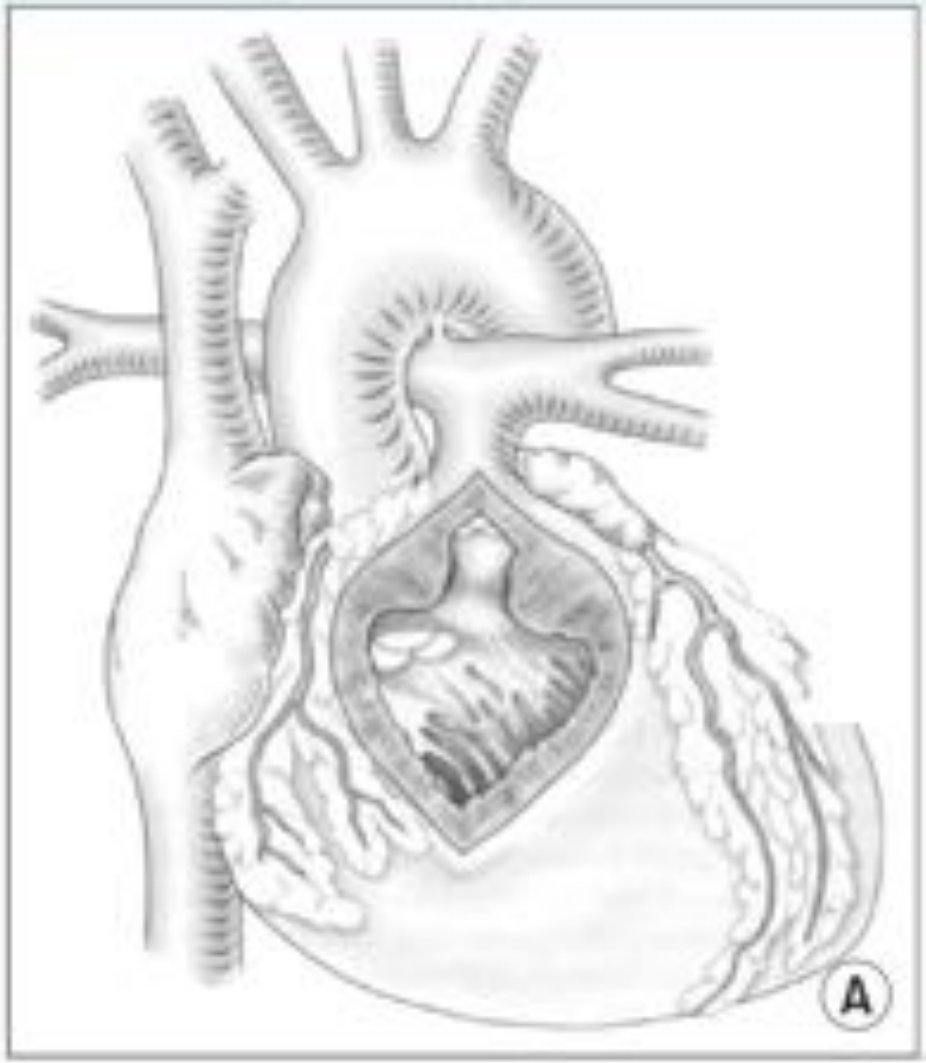
A

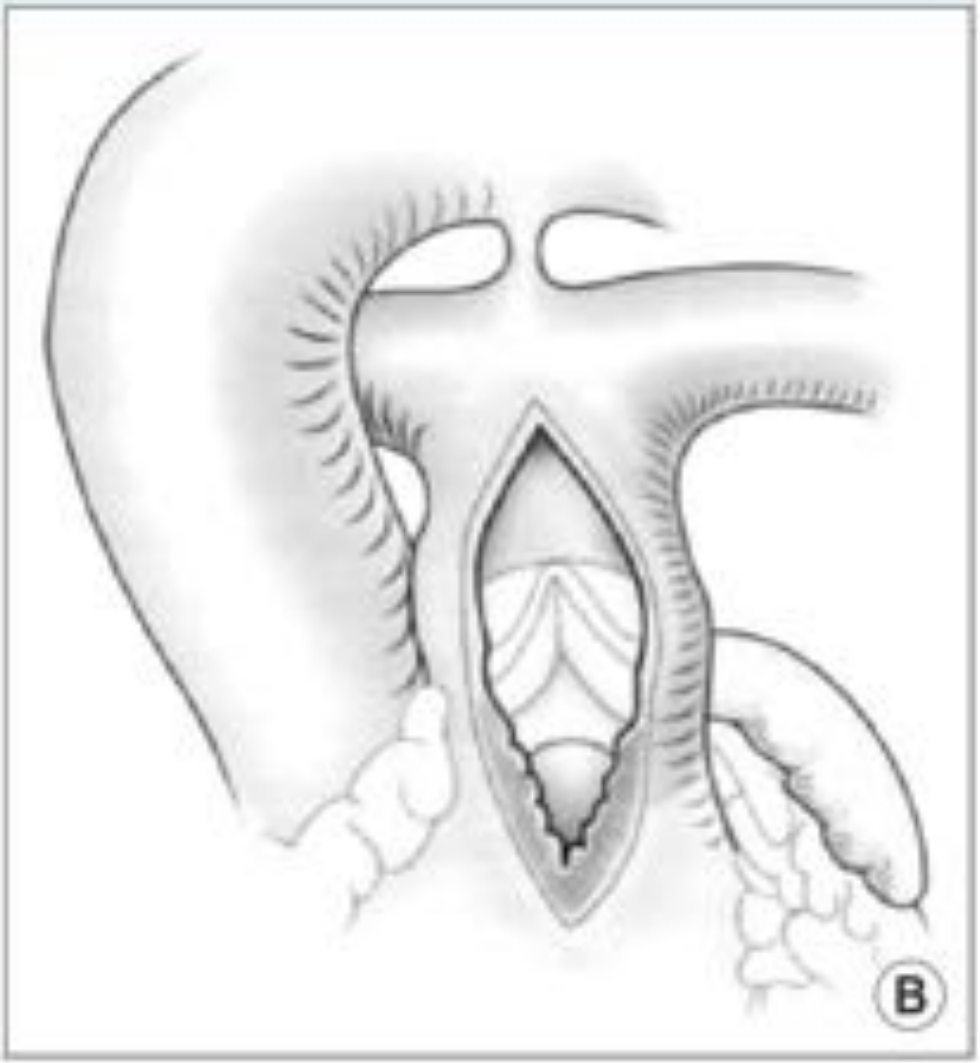
B

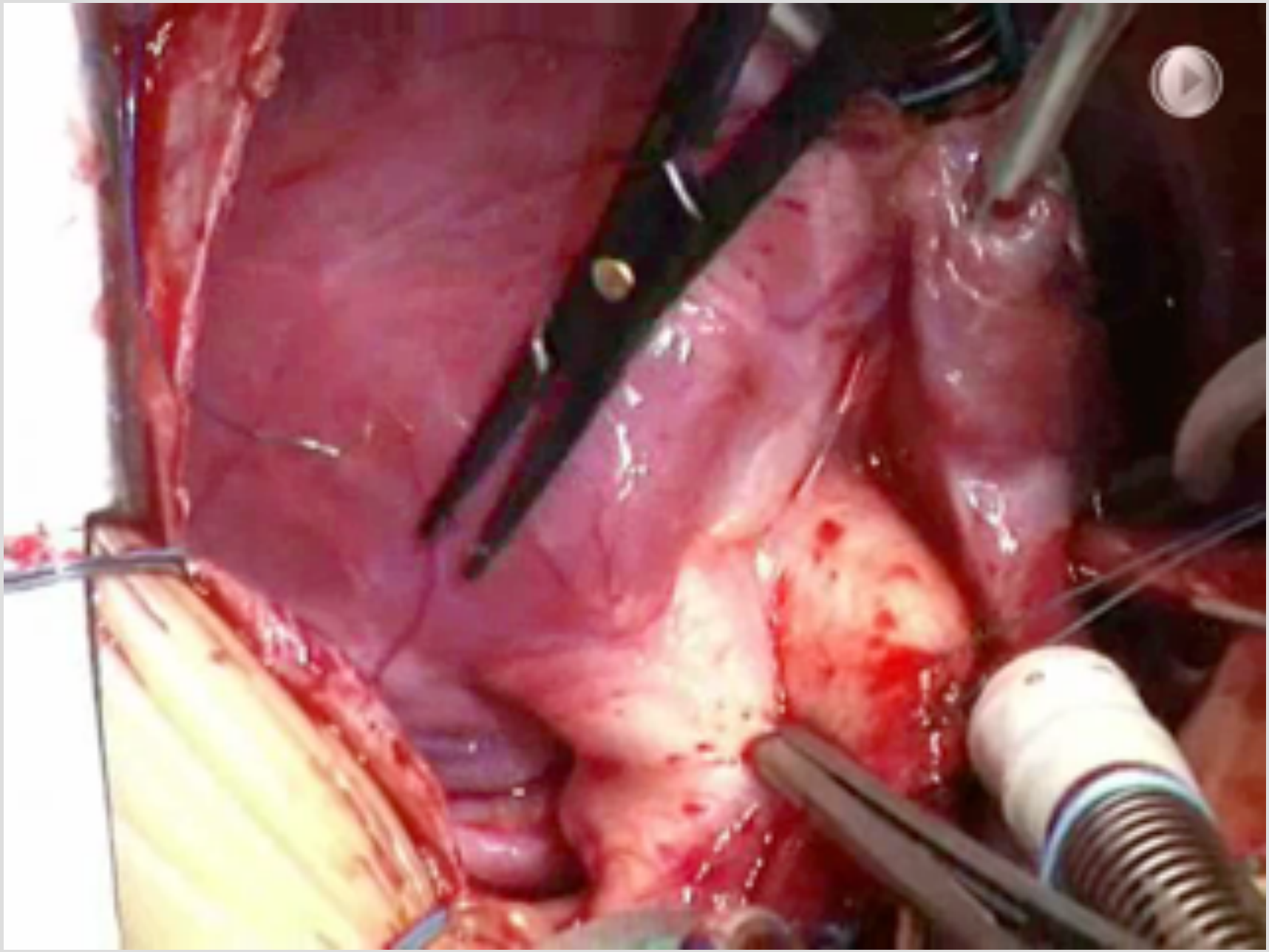

Stratégie chirurgicale

atriotomie

CIV FOP

Myomectomie infundibulaire par voie trans-atriale

Artériotomie pulm

Commissurotomie?

Ouverture de l'anneau pulmonaire?

Myomectomie infundibulaire par voie trans-pulmonaire

Patch pulmonaire

Patch trans-annulaire +/- monocusp

Patch infundibulaire/conservation anneau

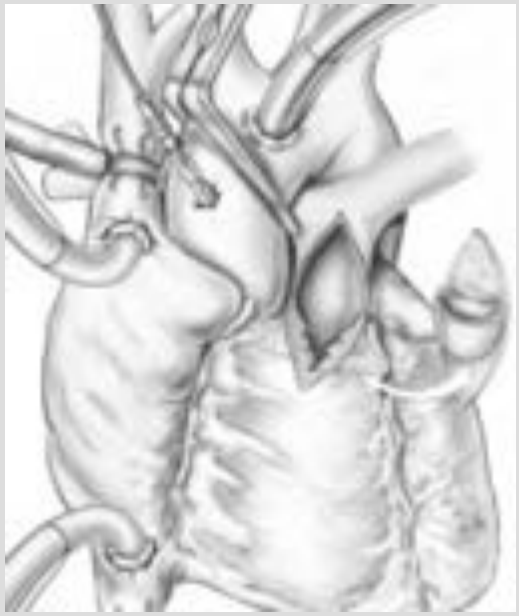

- Taille du patch??, ni trop large, ni trop étroit
- Âge et potentiel de croissance, degré de sténose sous-jacente

sortie de CEC et réanimation post-opératoire

Évaluation immédiate des résultats en per-opératoire (mesure des pressions, ETO, écho épicardique) et en post-op immédiat (écho)

- Monitorage POG et PAP
- Adaptation du remplissage, prévention de la surcharge pulmonaire (diurèse, inotropes)
- Prévention et traitement des poussées d'IVD

Rapport de pressions
Pressions étagées
Saturations veineuses
Retrait cathéter

3- chirurgie du Fallot « irrégulier »

Anomalie coronaire

Anomalie des branches pulmonaires

CIV multiples

CIA

Anomalie des valves atrio-ventriculaires

!!! Bilan pré-opératoire exhaustif obligatoire !!!

Crosse Ao. à droite

Veine cave sup. gauche

Persistance du canal artériel

Écho, KT, TDM, IRM

malposition coronaire

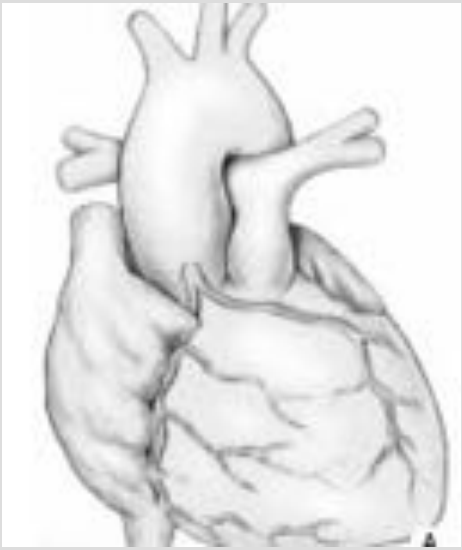

2 situations:

1. Découverte pré-opératoire
2. Découverte per-opératoire

2 solutions:

1. Possibilité de « contourner l'obstacle »
2. Anastomose systémico-pulmonaire ; tube valvulé VD-AP

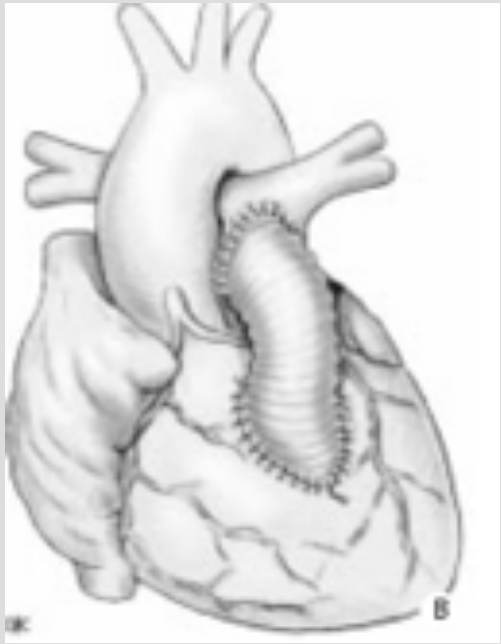

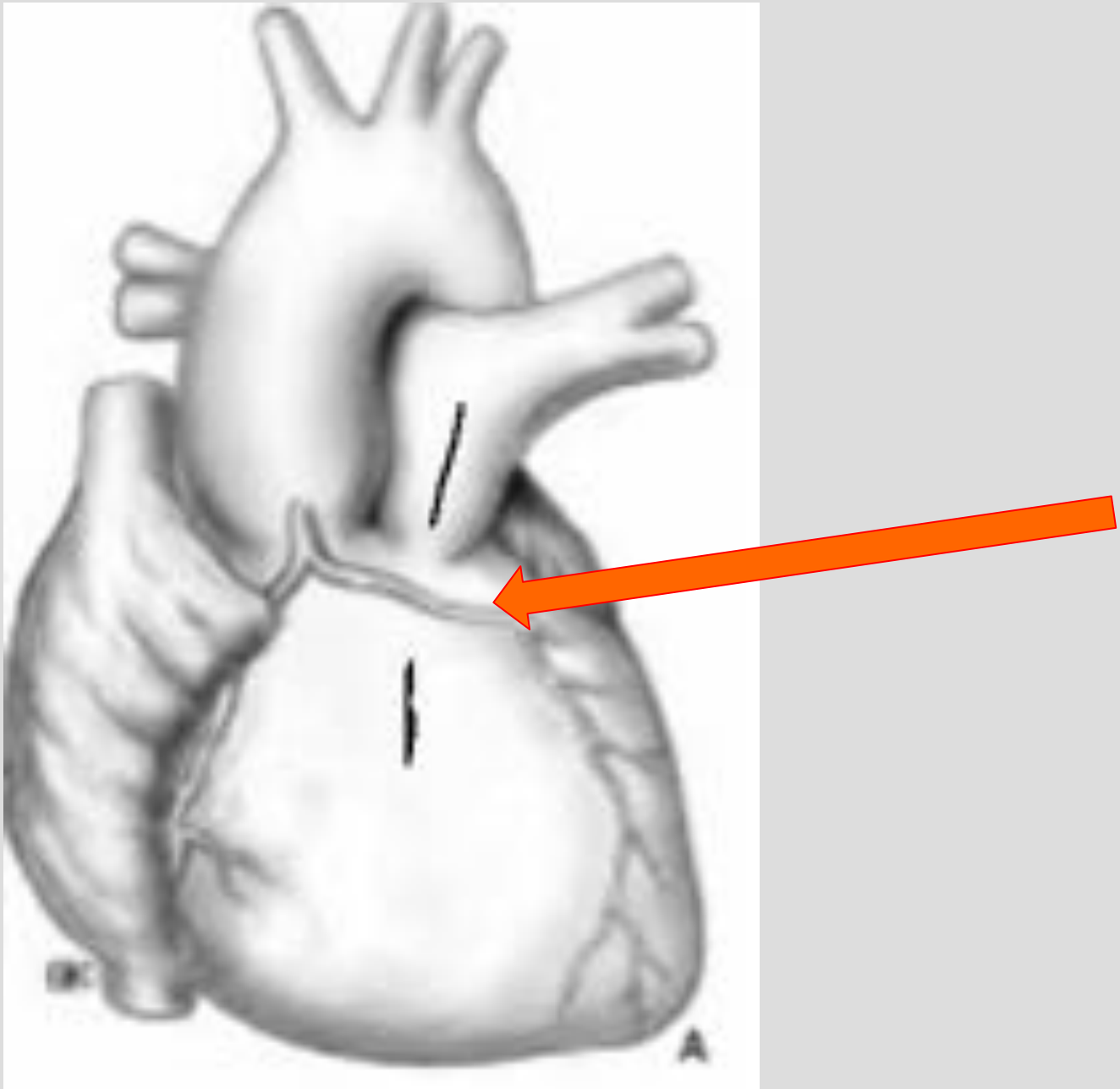
A

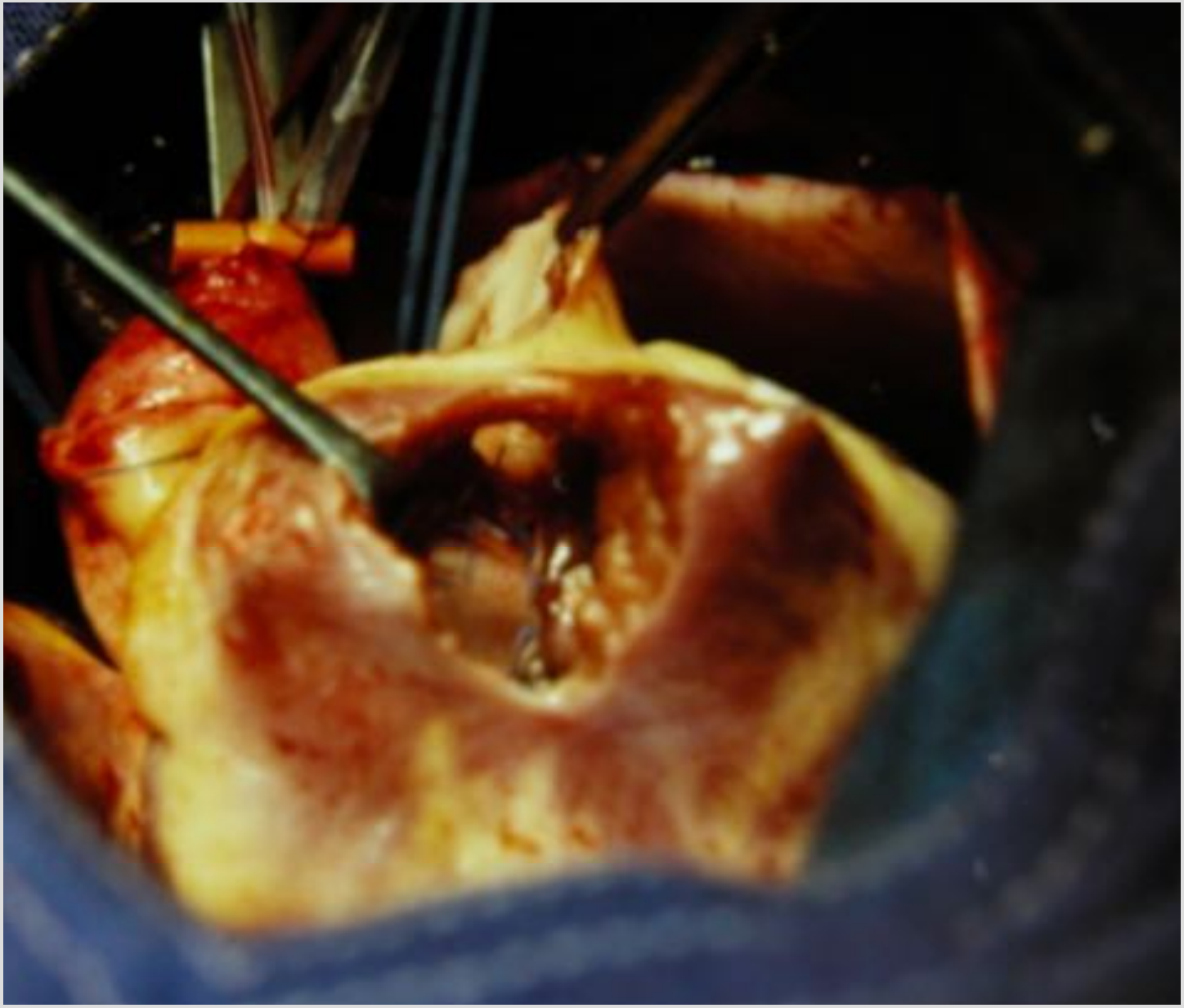

Hypoplasie des artères pulmonaires

Plastie élargie:

- Anneau; patch valvulé ou non
- Tronc de l' AP
- APG et/ou APD

Homogreffe (complète ou patch)

stent

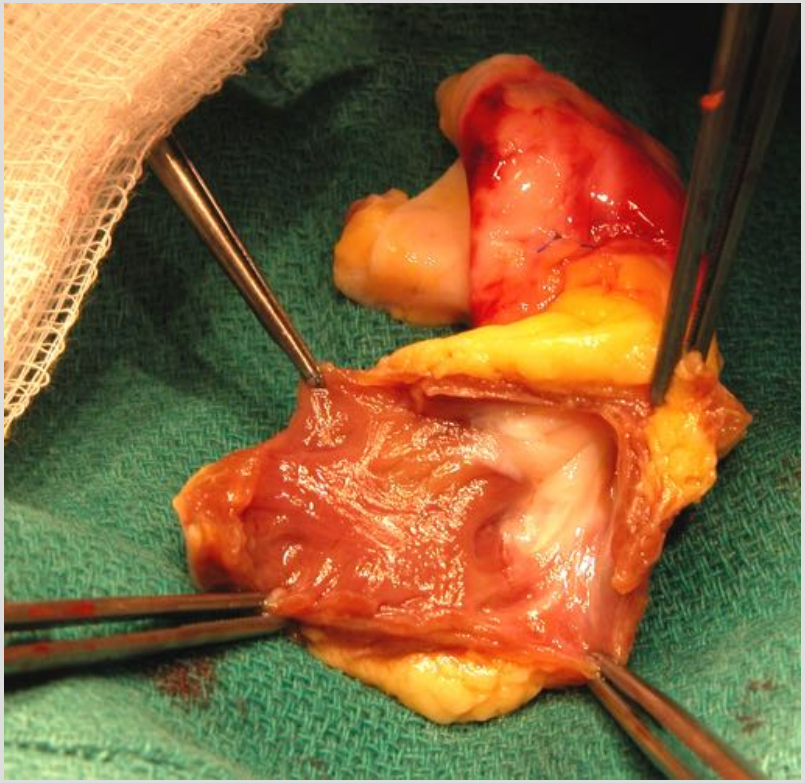

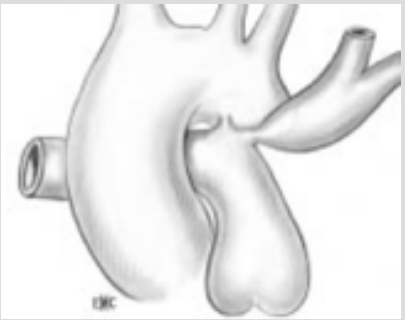

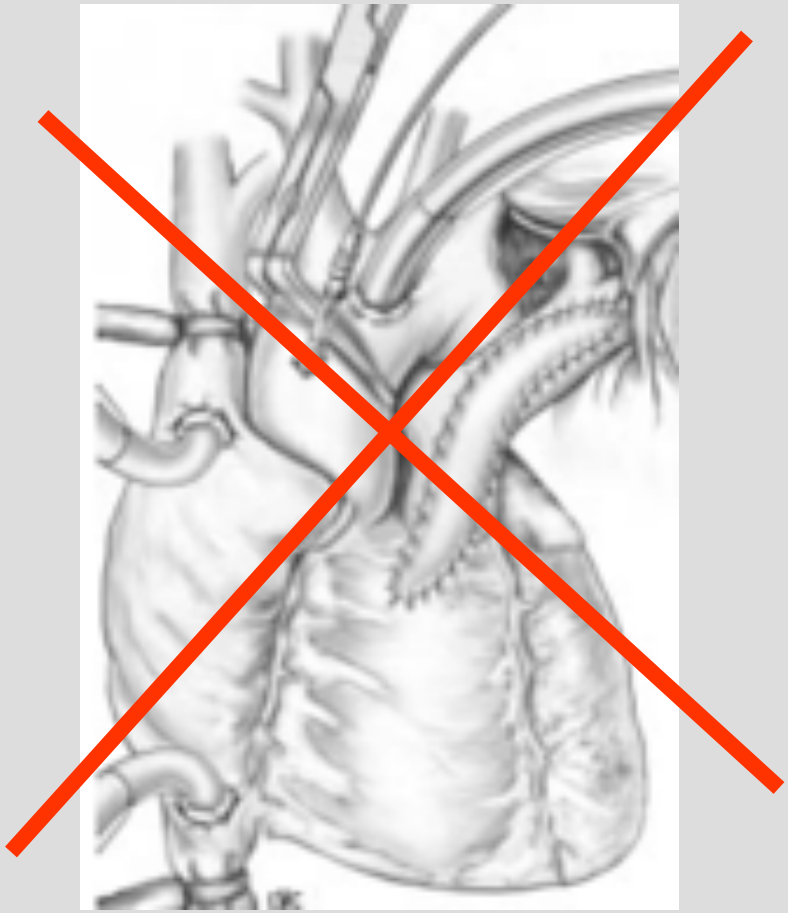

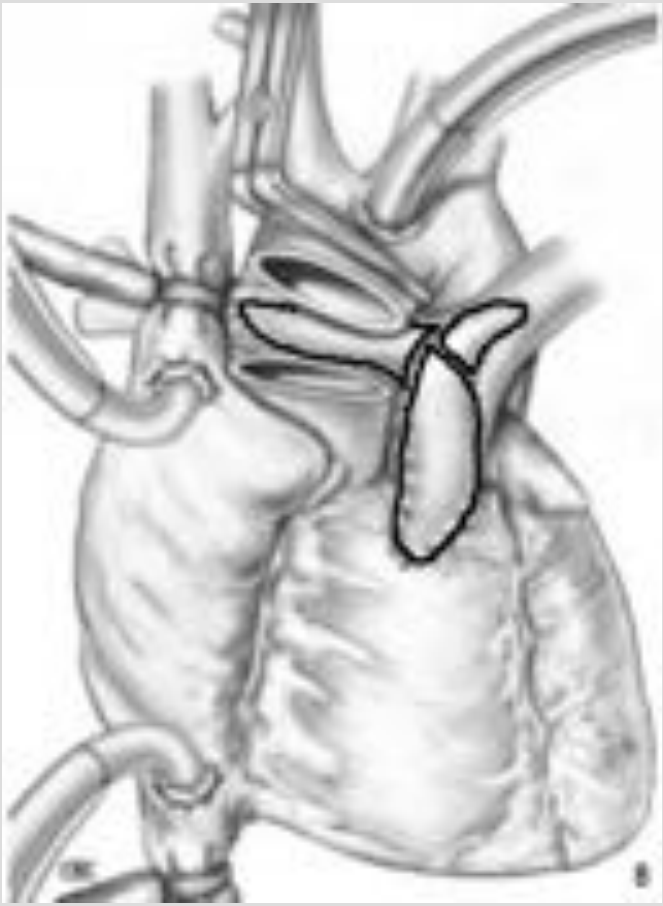

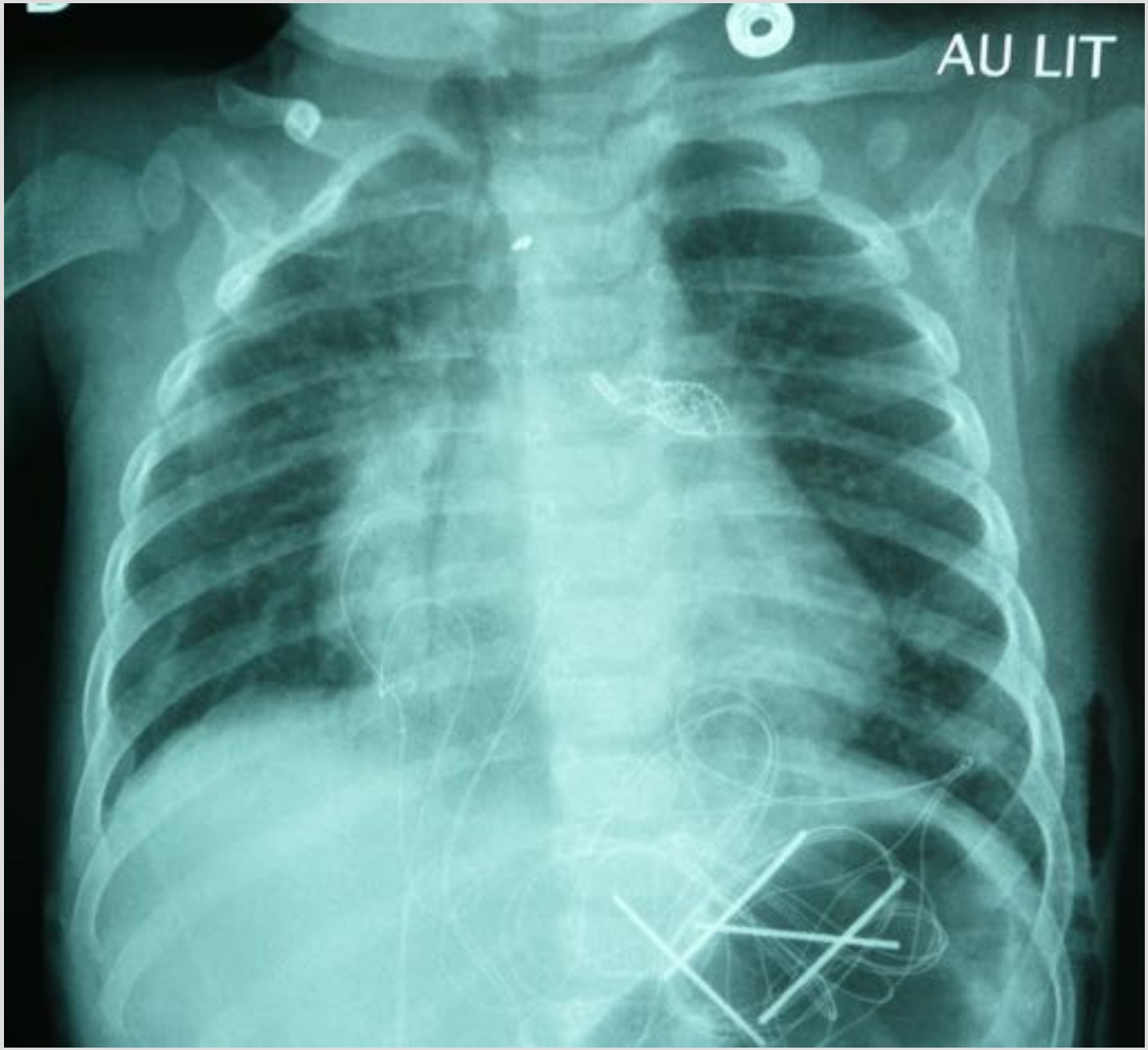
AU LIT

CIV multiples

- Fermeture « classique »
- Procédures hybrides

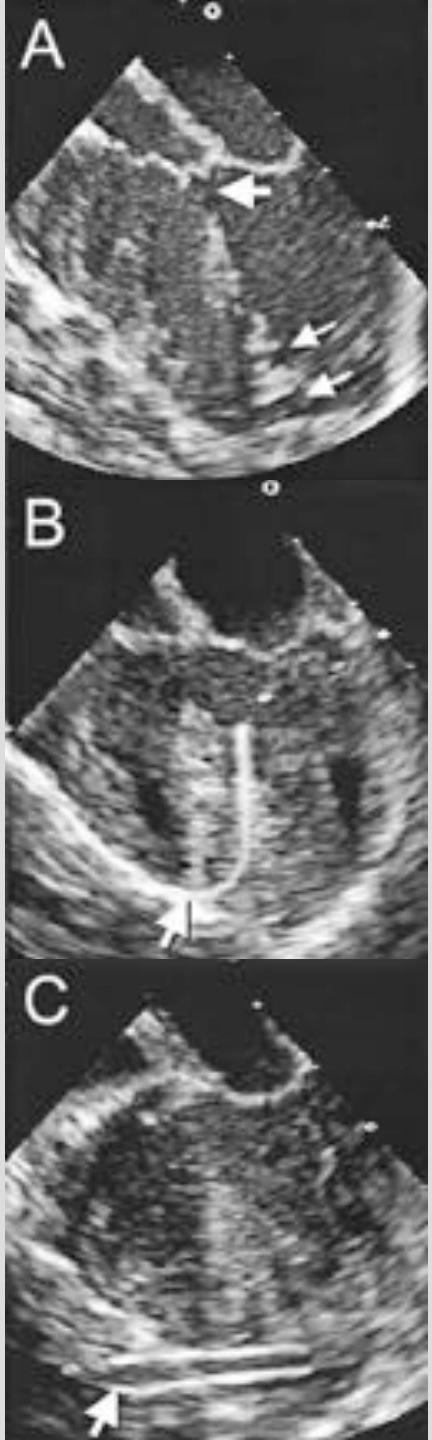

4-indications opératoires

Désaturation < 70 à 80 %

Intérêts d'une correction complète précoce:

- Effets cyanose chronique
- Élimine les csq d'un shunt systémico-pulm.
- Excision musculaire du VD, en diminuant l'hypertrophie du VD
- Incidence des troubles du rythme à long terme

Mortalité précoce: 1 à 5%

	Total (n)	Alive n (%)
TOF (All)		
< 1 month	61	60 (98)
> 1 month < 1 year	266	260 (98)
> 1 year	72	69 (96)
Total	399	389 (97)
TOF with PS		
< 1 month	37	36 (97)
> 1 month < 1 year	236	231 (98)
> 1 year	55	52 (96)
Total	328	319 (97)
TOF with PA		
< 1 month	24	24 (100)
> 1 month < 1 year	15	14 (93)
> 1 year	9	9 (100)
Total	48	47 (98)

Table 29.2 Hospital survival after complete repair for tetralogy of Fallot, University of Michigan,* January 1993–November 2004 (n = 399).

Diagnostic anté-natal

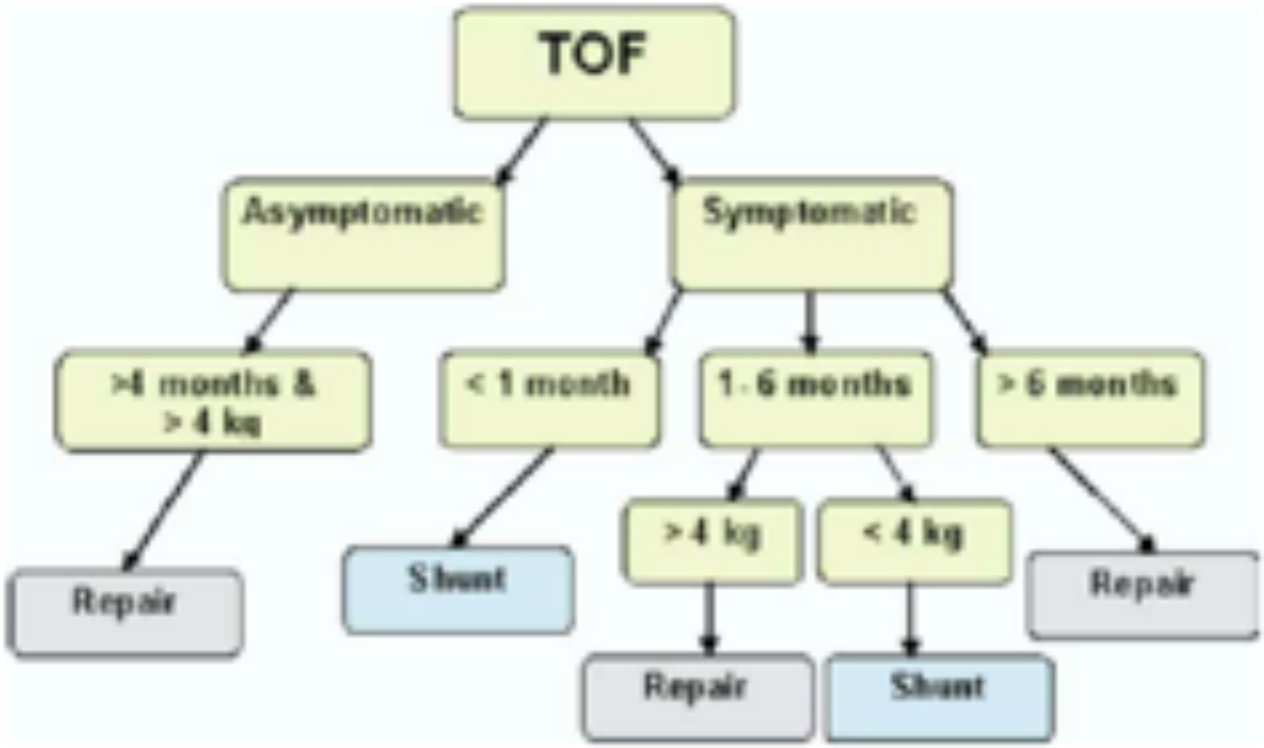

Figure 3 Flow diagram to illustrate the strategy of TOF repair.

perioperative factors on outcomes in children aged less than 18 months after repair of tetralogy of Fallot. J Thorac Cardiovasc Surg 126:703-710, 2003

5- autres considérations

Other mandatory points

Autres éléments importants

Eviter au maximum les problèmes de troubles du rythme et de la conduction

Rythm and conduction issues

Préserver les axes ilio-fémoraux

Preservation vascular accesses

Préparer une re-intervention et/ ou une valvulation

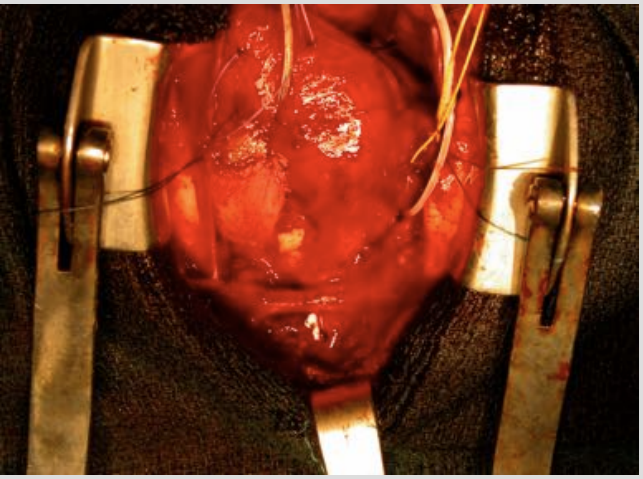

Op reports; coronary?

Away from the midline

Goretex membrane

Complications post-opératoire immédiates

- Gradient VD-AP
  - Où? Combien????
- Lésion du tissu de conduction (BAV)
  - Séquence A-V +++
- CIV résiduelle
  - Potentiellement très grave
- CIA/FOP/Cyanose

De toute façons >>>> IVD diastolique >>>> Sd oedemato-ascitique

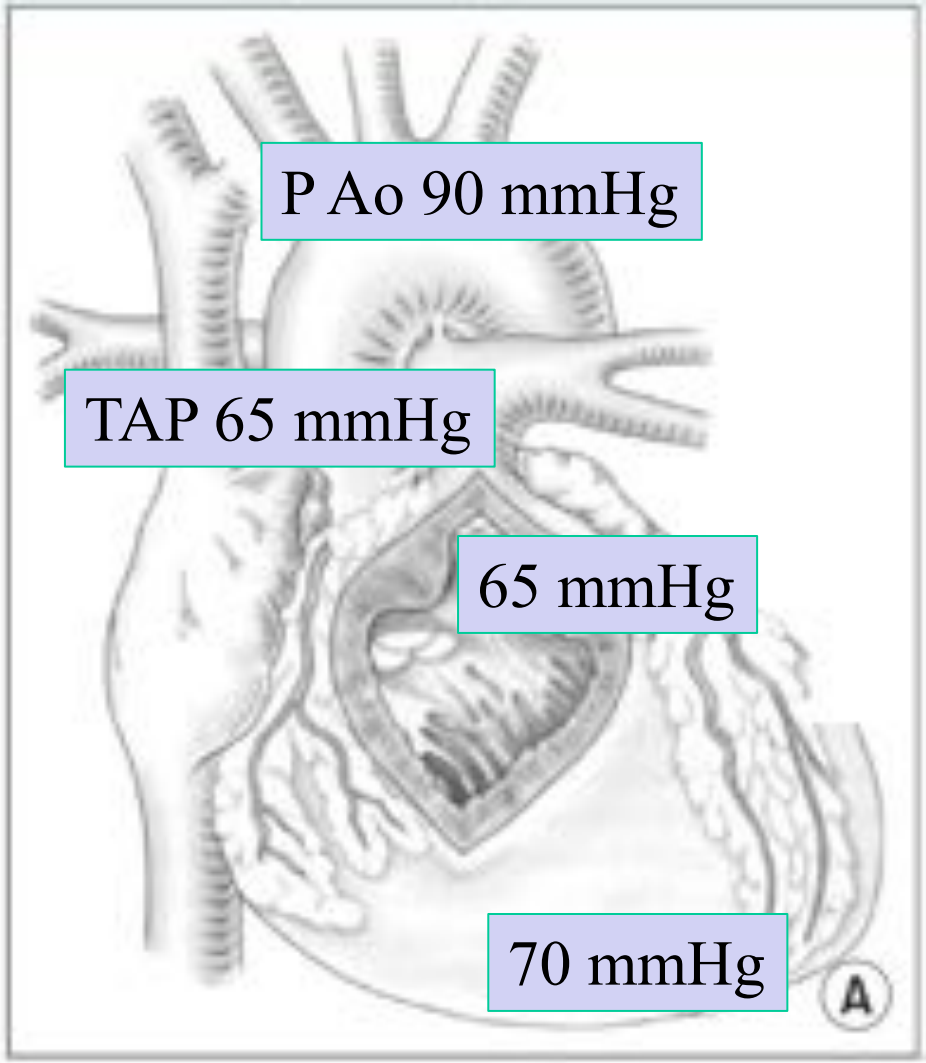
P Ao 90 mmHg
TAP 65 mmHg
65 mmHg
70 mmHg
A

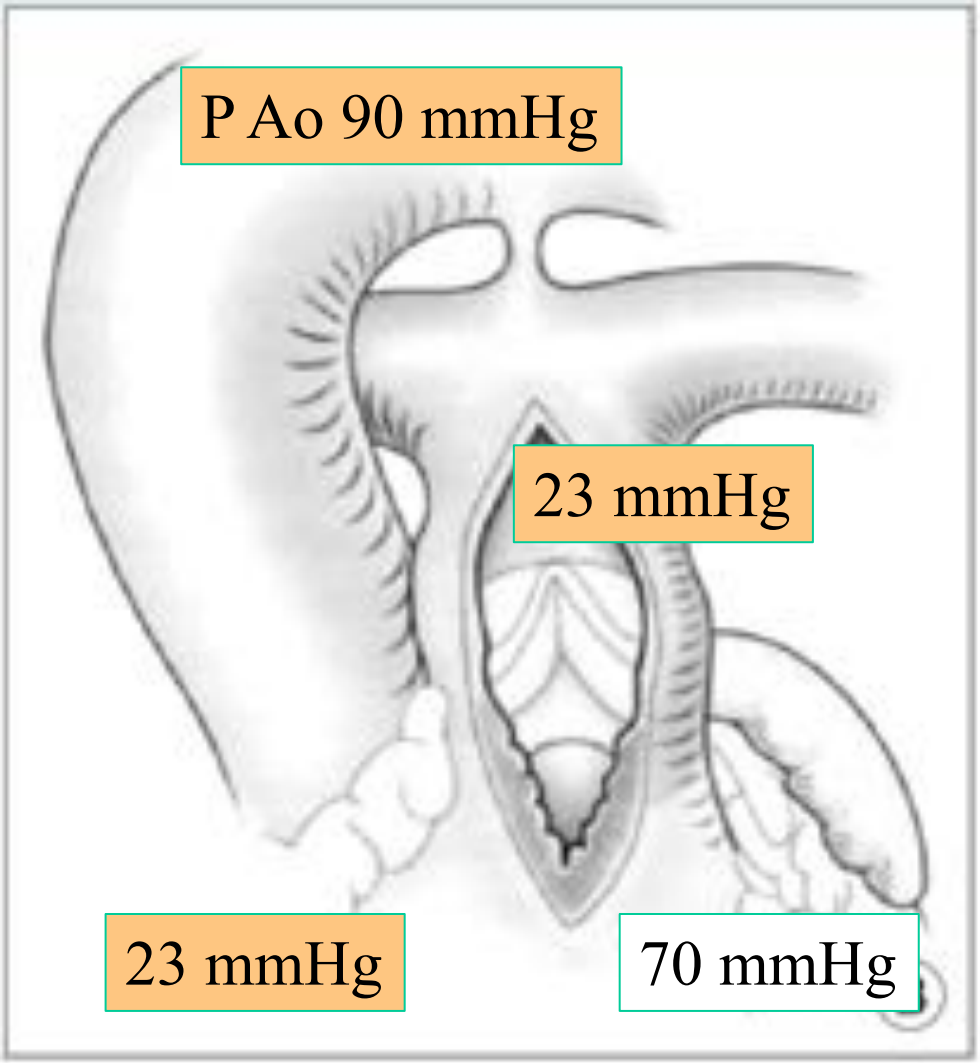
P Ao 90 mmHg
23 mmHg
23 mmHg
70 mmHg

70 mmHg

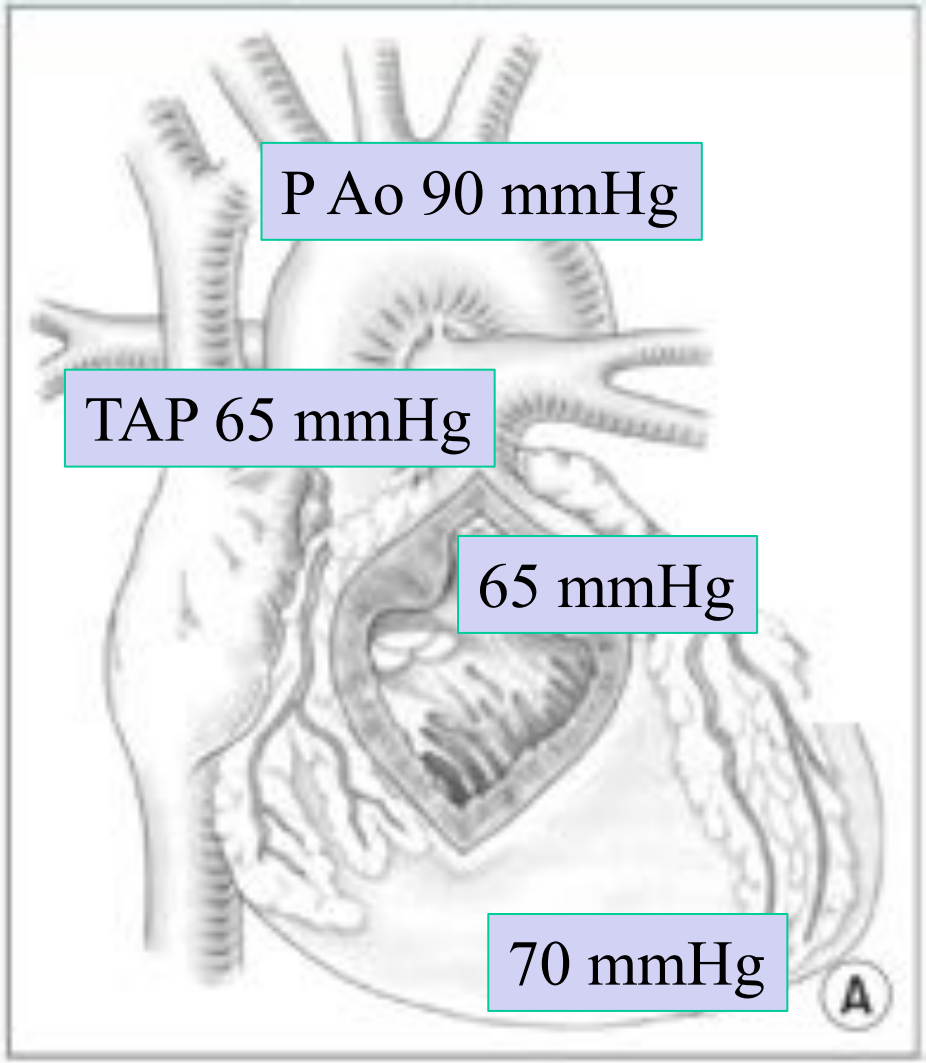
P Ao 90 mmHg
TAP 65 mmHg
65 mmHg
70 mmHg
A

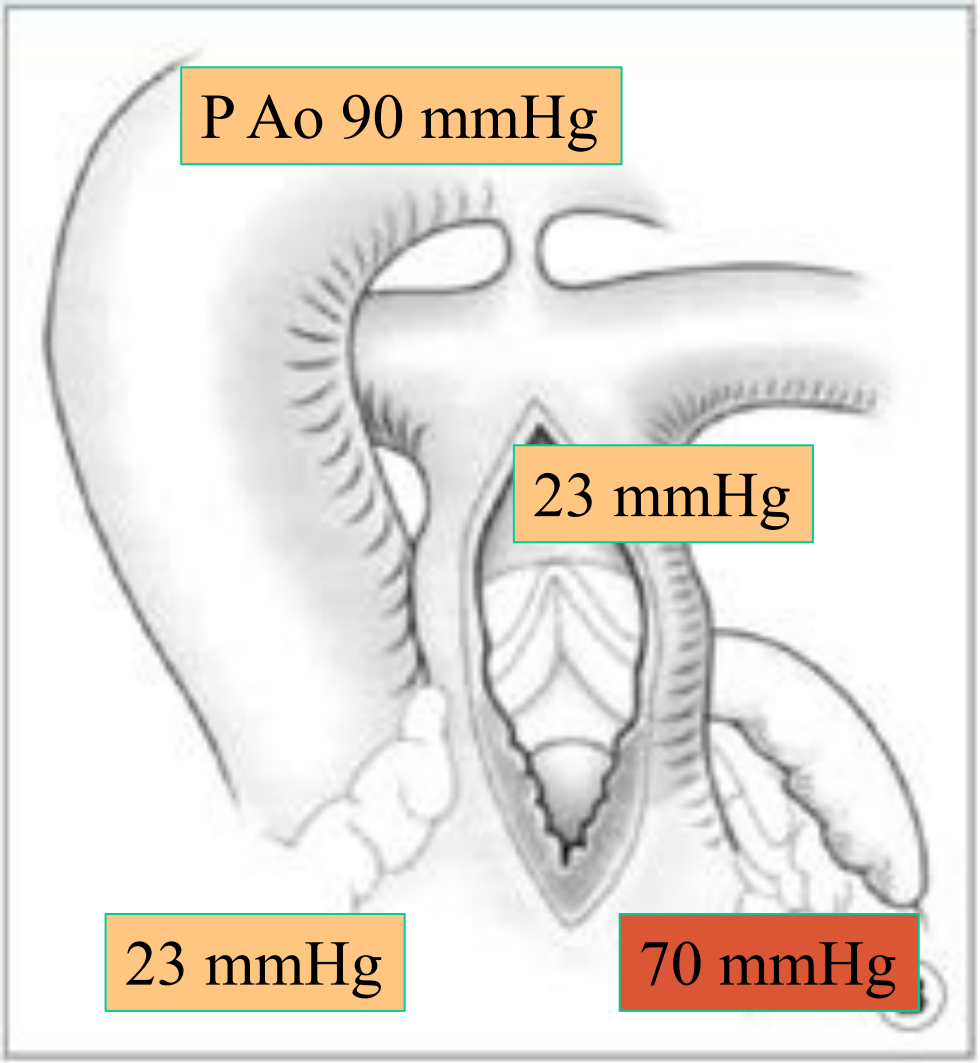
P Ao 90 mmHg
23 mmHg
23 mmHg
70 mmHg

70 mmHg

Complications post-opératoire immédiates

- Gradient VD-AP
  - Où? Combien????
- Lésion du tissu de conduction (BAV)
  - Séquence A-V +++
- CIV résiduelle
  - Potentiellement très grave
- CIA/FOP/Cyanose

De toute façons >>>> IVD diastolique >>>> Sd oedemato-ascitique

REOPERATION IN ADULTS WITH REPAIR OF TETRALOGY OF FALLOT: INDICATIONS AND OUTCOMES

Table II. *Major hemodynamic indications for reoperation**

Primary lesion	*n*	%
RVOT complications	45	75
Severe pulmonary regurgitation	24	40
Conduit failure	13	22
RVOT obstruction	5	8
Severe PR and RVOT obstruction	3	5
VSD patch leak (Qp/Qs > 1.5)	6	10
Severe tricuspid regurgitation	3	5
Patent Blalock-Taussig shunt	3	5
Others	3	5

Erwin N. Oechslin, MD

From the Toronto Congenital Cardiac Centre for Adults, The Toronto Hospital, Toronto, Ontario, Canada.

The Journal of Thoracic and Cardiovascular Surgery
Volume 118, Number 2

REOPERATION IN ADULTS WITH REPAIR OF TETRALOGY OF FALLOT: INDICATIONS AND OUTCOMES

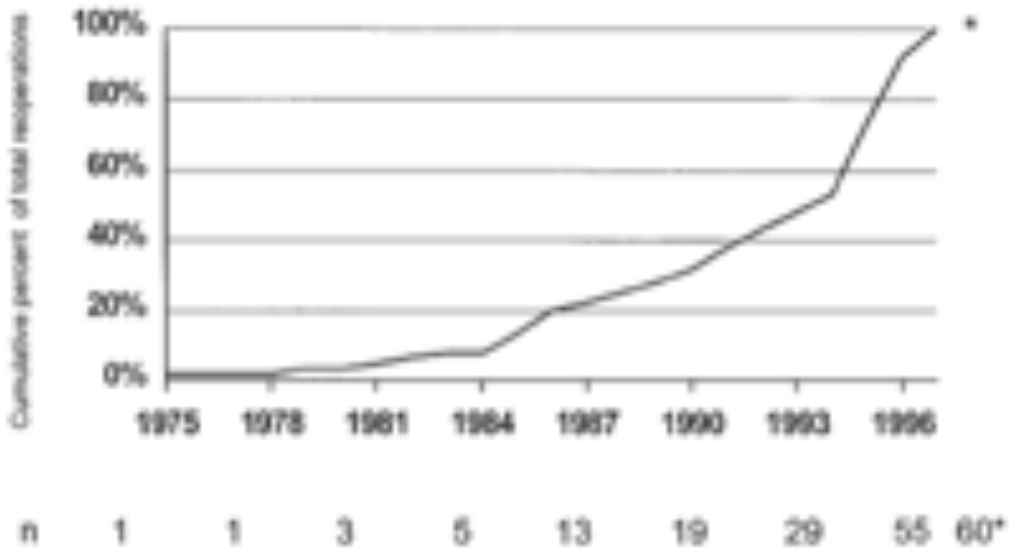

Fig 3. Cumulative percent of reoperations from 1975 until March 1997. There is a marked increase of reoperations in recent years. *N* indicates numbers of reoperations. *Asterisk* denotes March 31, 1997.

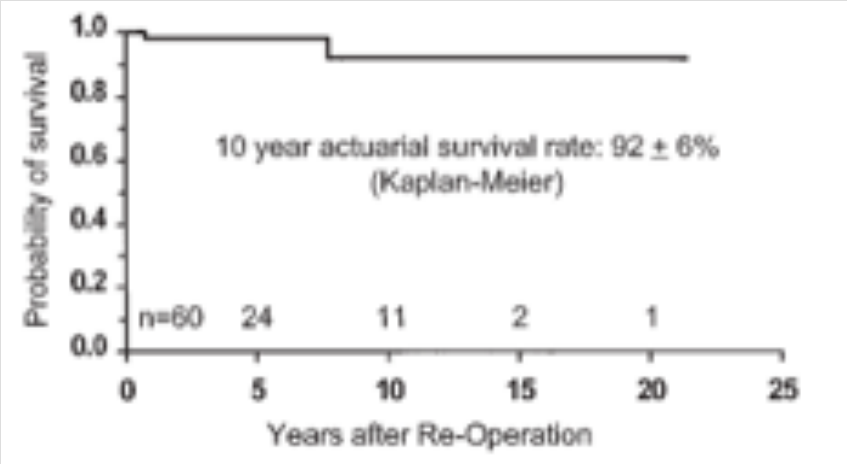

Complications tardives

- Re-sténose voie de sortie VD (infundibulum, anneau, AP)
- Insuffisance de la valve pulm.

+++ Insuffisance de la valve pulmonaire +++

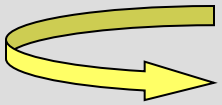
Dilatation du VD

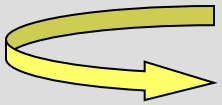
Insuffisance tricuspide

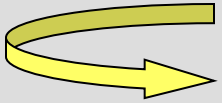
Troubles du rythme

+++ Insuffisance de la valve pulmonaire +++

3. Moyens thérapeutiques?

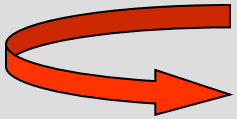

Valvulation pulmonaire

Chirurgicale

- homogreffe

Percutanée

Nécessité d'un « support » tubulaire

Pediatric Cardiac Surgery Annual

Valve-Sparing Options in Tetralogy of Fallot Surgery

Emile Bacha

Current strategies in tetralogy of Fallot repair: pulmonary valve sparing and evolution of right ventricle/left ventricle pressures ratio☆

Lorenzo Boni[a,*], Enrique Garcia[a], Lorenzo Galletti[a], Ana Pérez[a], Dolores Herrera[a], Victoria Ramos[b], Stefano M. Marianeschi[a], Juan V. Comas[a]

[a]Pediatric Cardiac Institute of Doce de Octubre University Hospital, Madrid, Spain
[b]Pediatric Intensive Care Unit of Doce de Octubre University Hospital, Madrid, Spain

European Journal of Cardio-thoracic Surgery 35 (2009) 885–890

Actuarial freedom from re-operation for RVOTO recurrence.

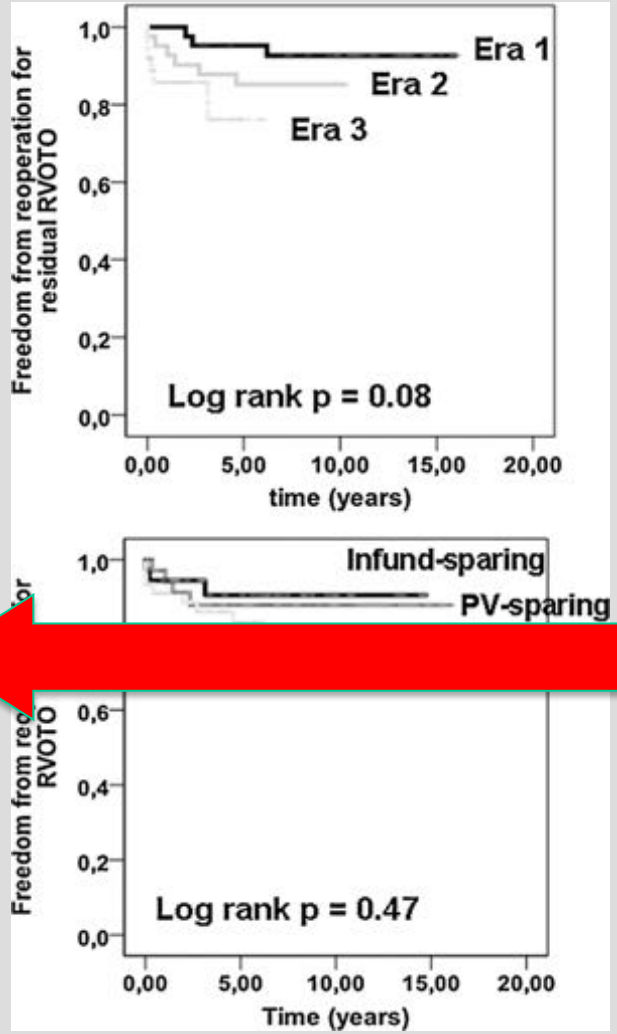

Re-opérations pour sténose pulmonaire

Early valvulation

(Mise en place d'un conduit valvé)

Bové T et al. Eur J Cardiothorac Surg 2012;41:126-133

© The Author 2011. Published by Oxford University Press on behalf of the European Association for Cardio-Thoracic Surgery. All rights reserved

EUROPEAN JOURNAL OF CARDIO-THORACIC SURGERY

Complications post-opératoire immédiates

- Gradient VD-AP
  - Où? Combien????
- Lésion du tissu de conduction (BAV)
  - Séquence A-V +++
- CIV résiduelle
  - Potentiellement très grave
- Dysfonction pulmonaire
  - Revascularisation?, surcharge?, hyper débit?
- CIA/FOP/Cyanose

De toutes façons >>>> IVD diastolique >>>> Sd oedemato-ascitique

6- conclusion

Cardiopathie fréquente

Complexité étagée

Pronostic à 10 ans favorable

Le réanimateur n’a pas droit à l’erreur!

Growth Up Congenital Heart Disease

Évaluation à l’ âge adulte, évaluation et traitement des complications tardives