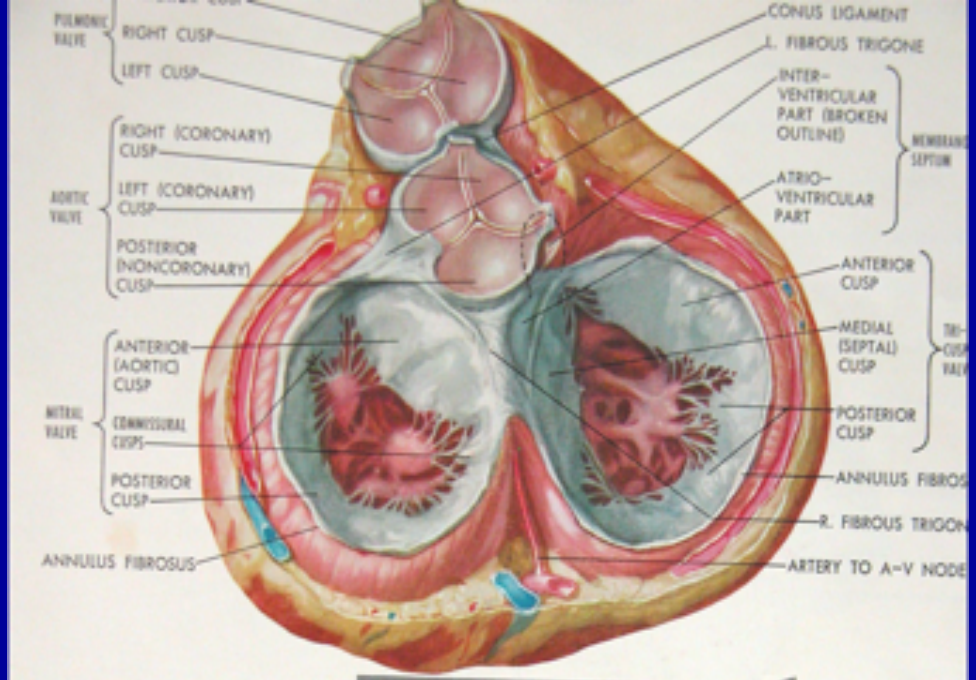

THE HEART IN DIASTOLE: VIEWED FROM BASE WITH ATRIA REMOVED

F. Netter M.D.
©CIBA

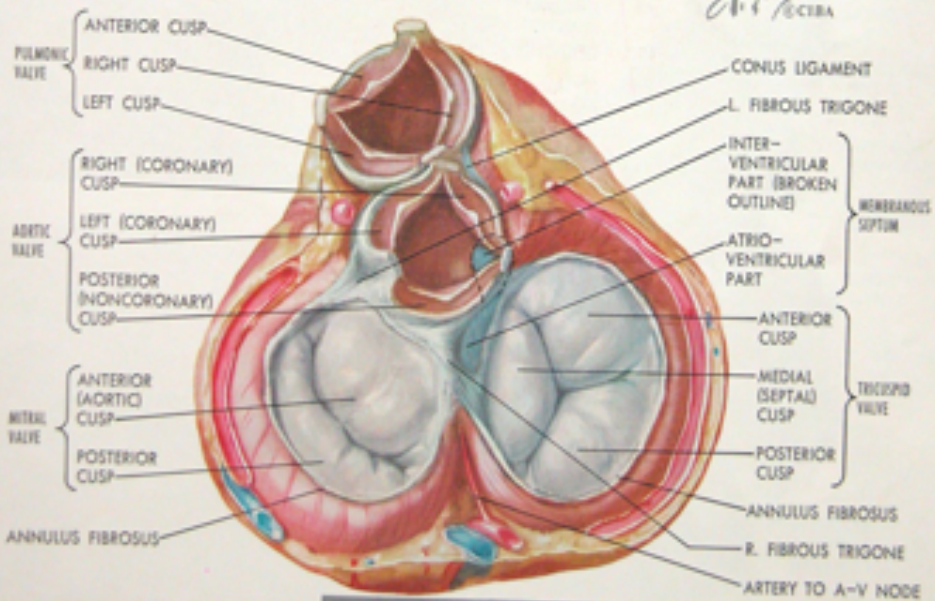

THE HEART IN SYSTOLE: VIEWED FROM BASE WITH ATRIA REMOVED

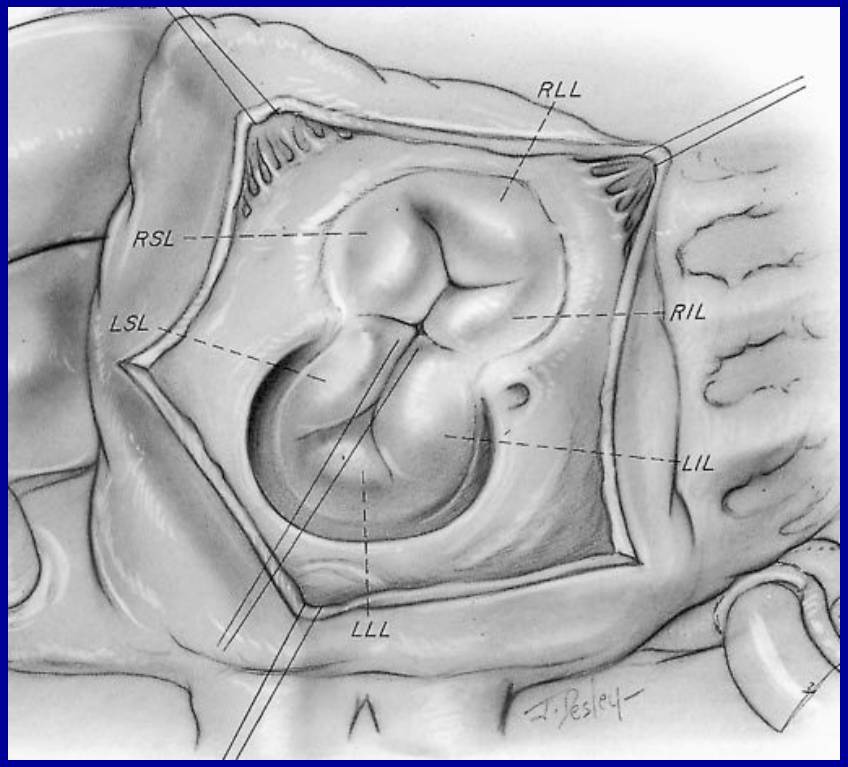
RLL
RSL
LSL
RIL
LIL
LLL

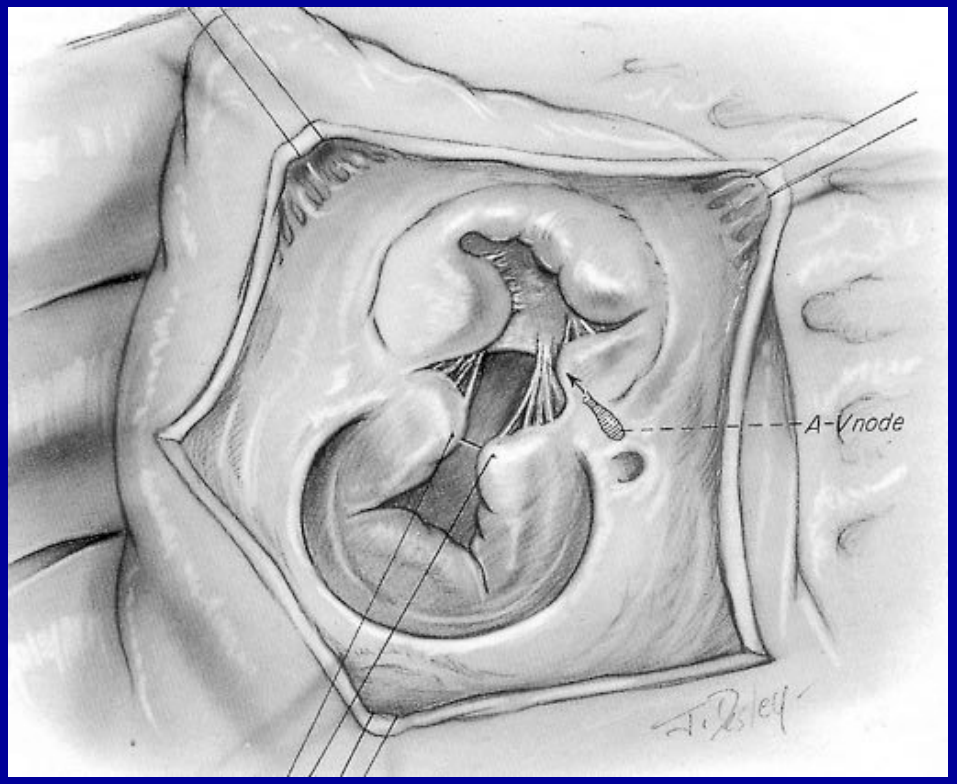
A-V node

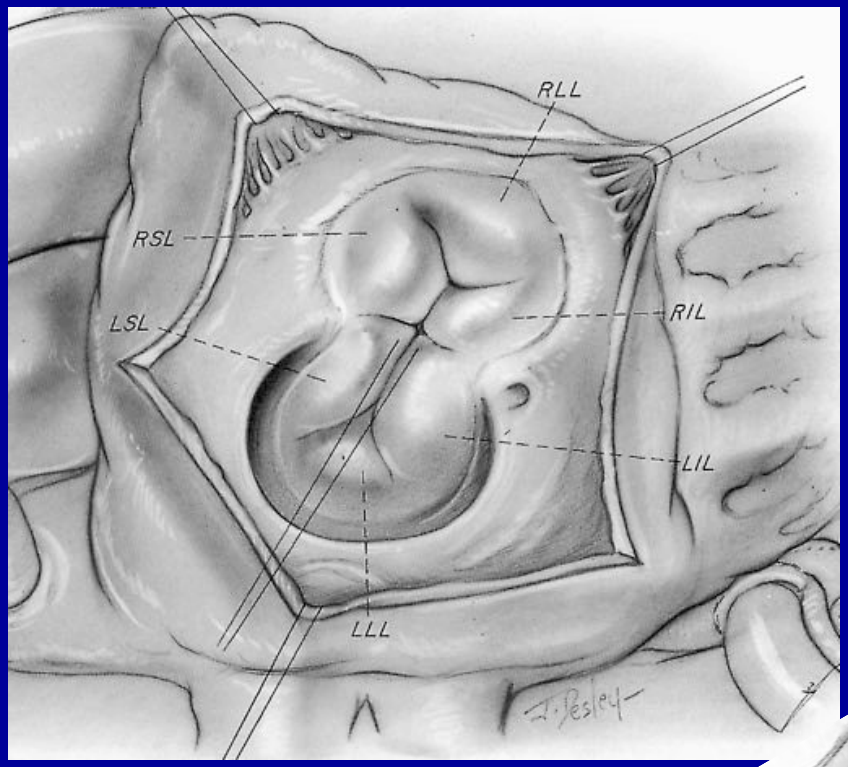
RLL
RSL
LSL
RIL
LIL
LLL

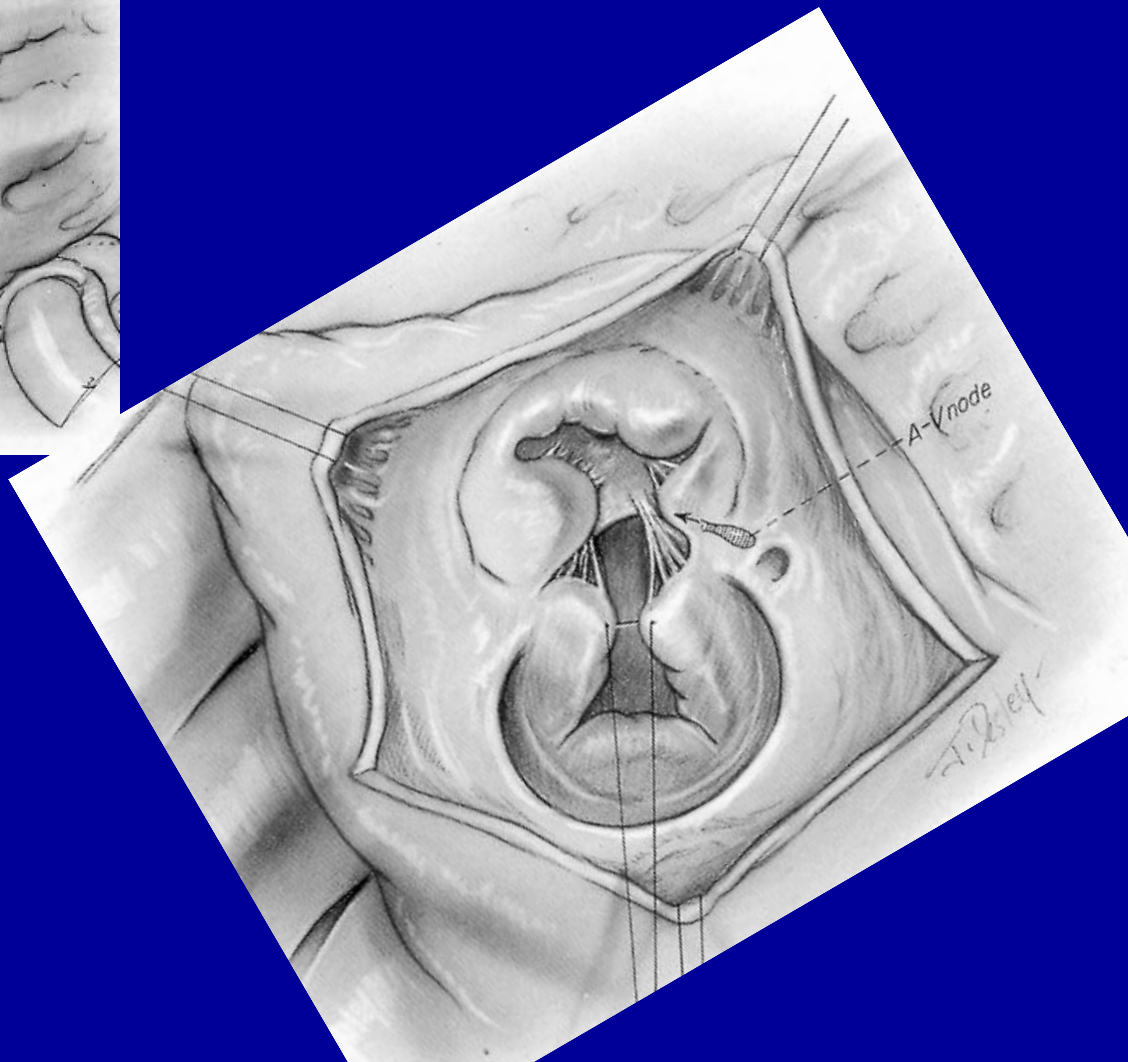
A-V node

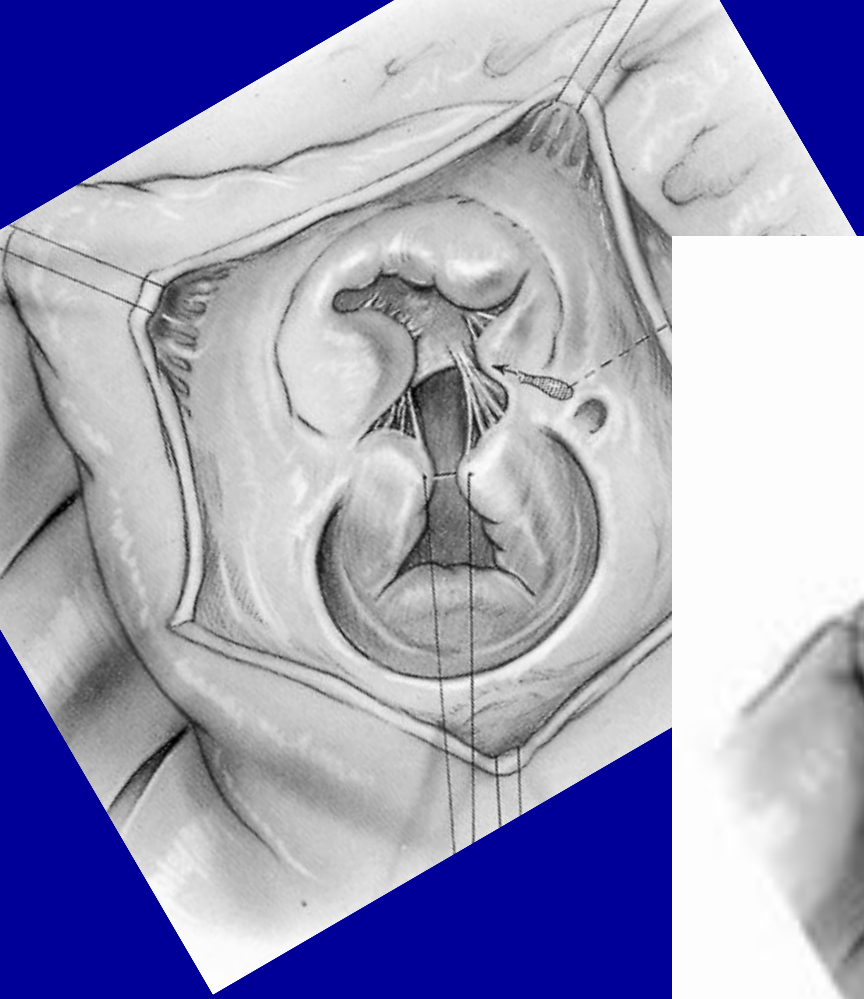

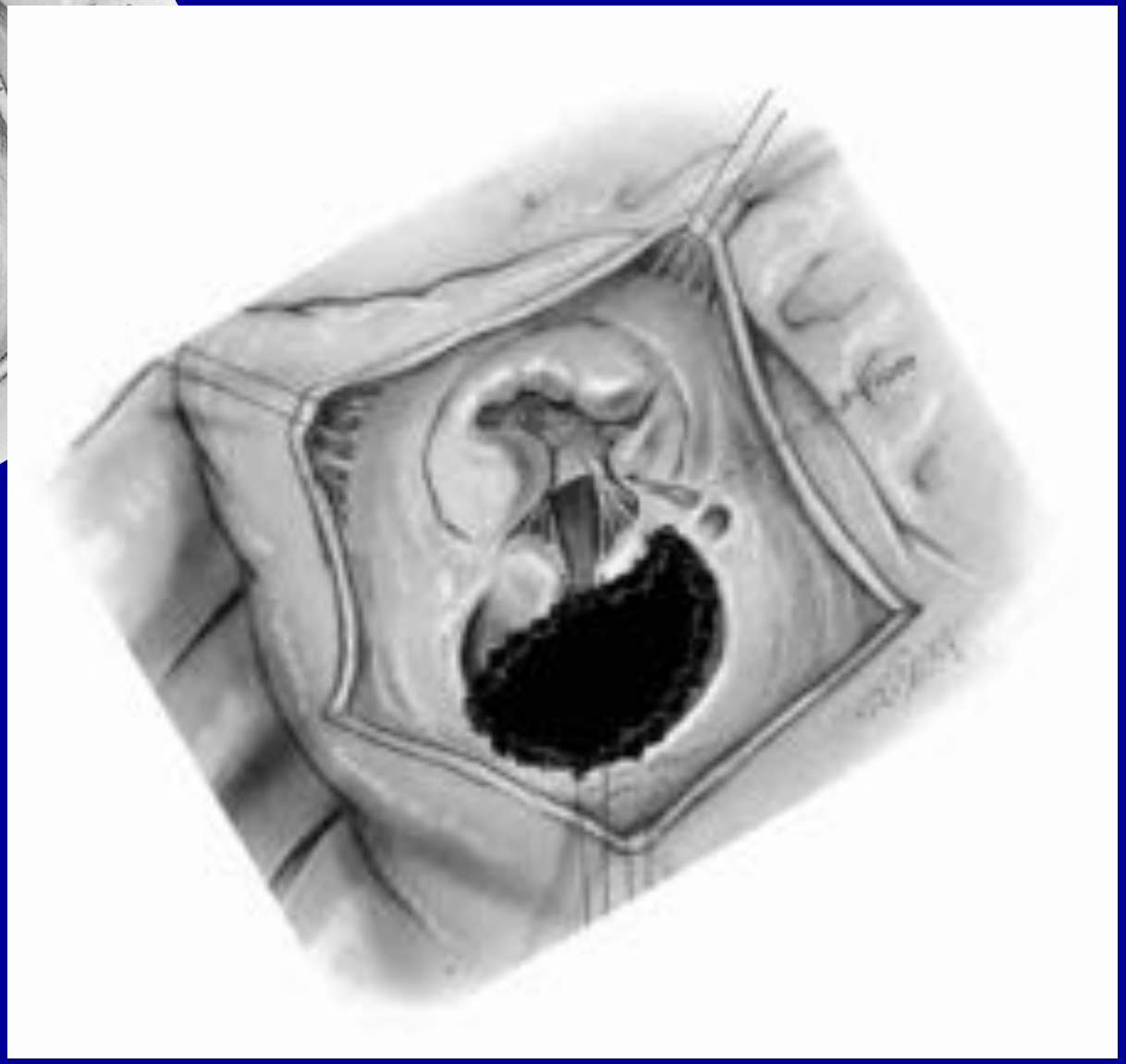

Rastelli: types A & C

CHIRURGIE DU CAVC

Types de correction

A - Opération de Rastelli classique (1 patch auriculo-ventriculaire)

* Division valve commune antérieure
* Division valve commune postérieure
* Patch sur rebord droit de la CIV
* Composantes valvulaires attachées au patch

B - Correction avec 2 patches (ventriculaire, auriculaire)

C - Correction type Wilcock, Nicholson, Nunn….

* « transformation » en CAV partiel

«Properly used all techniques appear to provide good results…»
KIRKLIN, BARRATT-BOYES, 1993, p 720

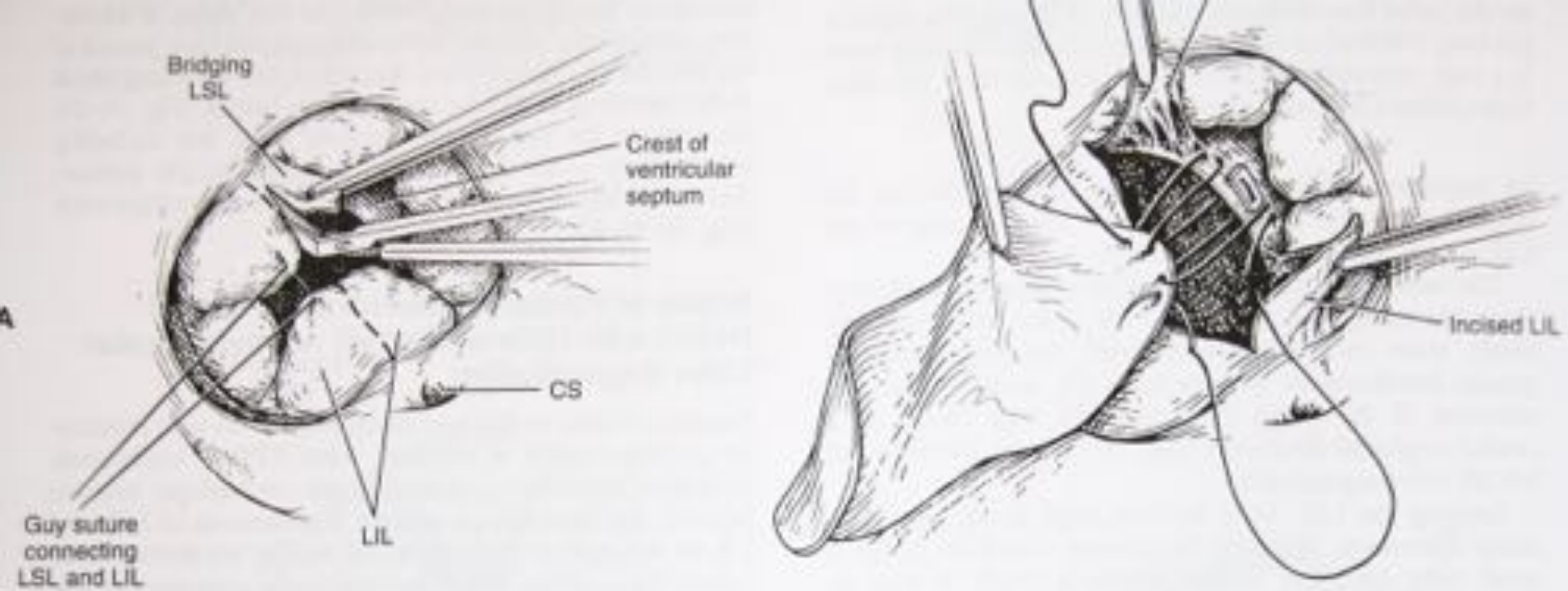

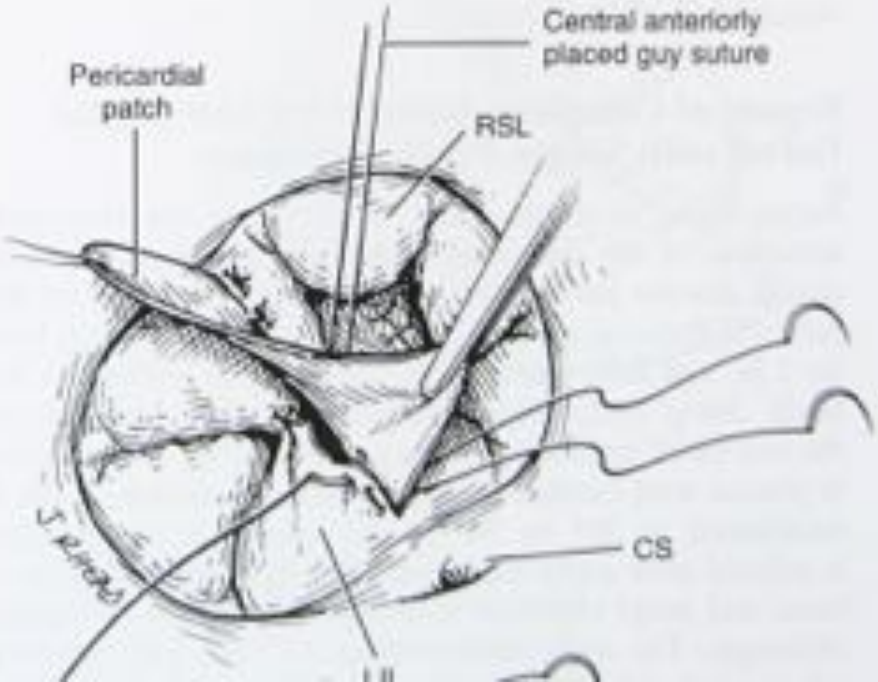

Figure 20-23 Complete atrioventricular (AV) septal defect repair, single-patch technique. **A**, Right atriotomy is made as for two-patch technique and AV valves are inspected. Saline is infused into ventricles as for two-patch technique, and apposition point of left superior leaflet *(LSL)* and left inferior leaflet *(LIL)* is identified as the leaflets float up to their systolic position. A fine guy suture is placed for alignment and left loose. Frequently, the bridging LSL or LIL is incised to gain access to the anterior portion of interventricular defect. Later, each cut edge of the superior leaflet will be attached to pericardial patch at its waist. **B**, Fresh or glutaraldehyde-treated pericardial patch is trimmed partially after measuring height and width of interventricular communication. Generally, the ventricular portion of the patch is attached to the right side of crest of ventricular septum using a continuous suture initiated at the deepest aspect (midpoint) of the rim of the ventricular septal defect. Usual precautions are taken as in the two-patch technique to avoid the bundle of His at posterior–inferior aspect of ventricular defect. **C**, AV leaflets, both left and right, are attached to pericardial patch at appropriate

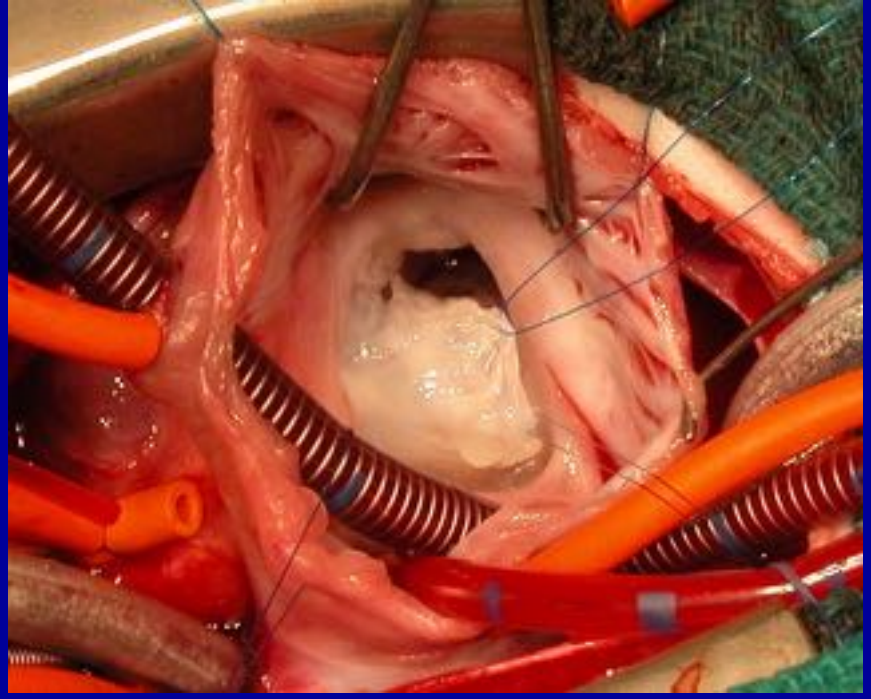

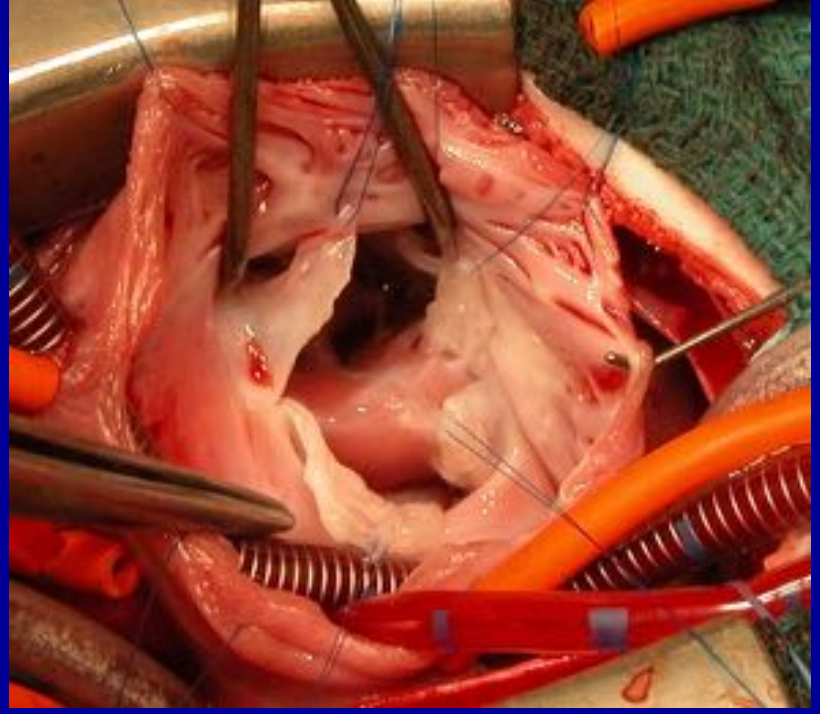

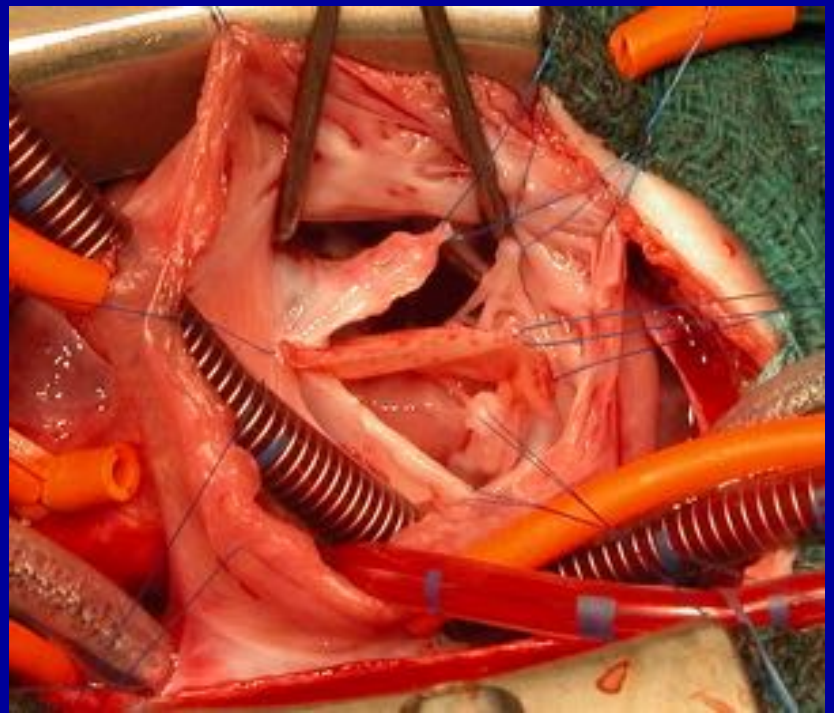

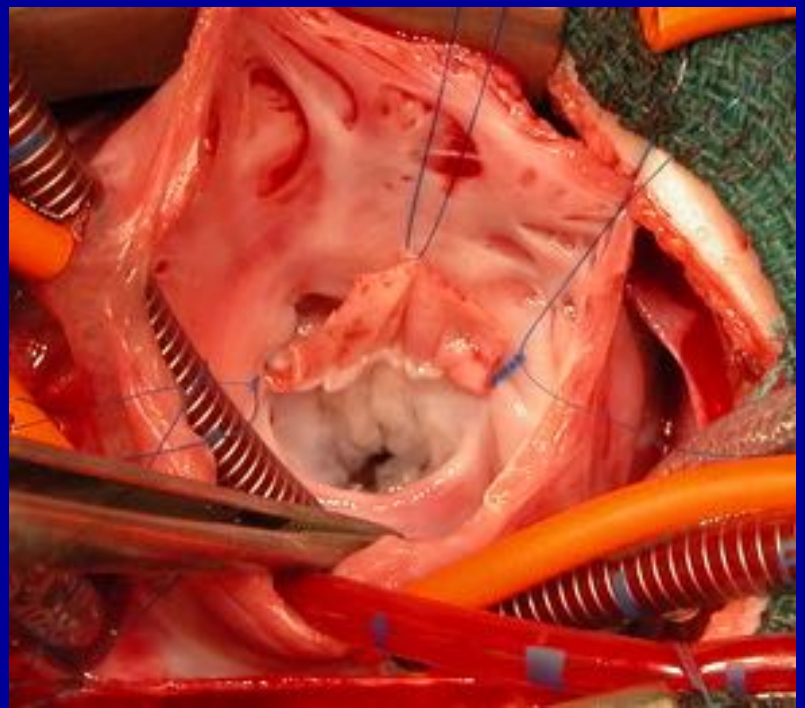

CHIRURGIE DU CAVC

Le tissu nodal et la conduction

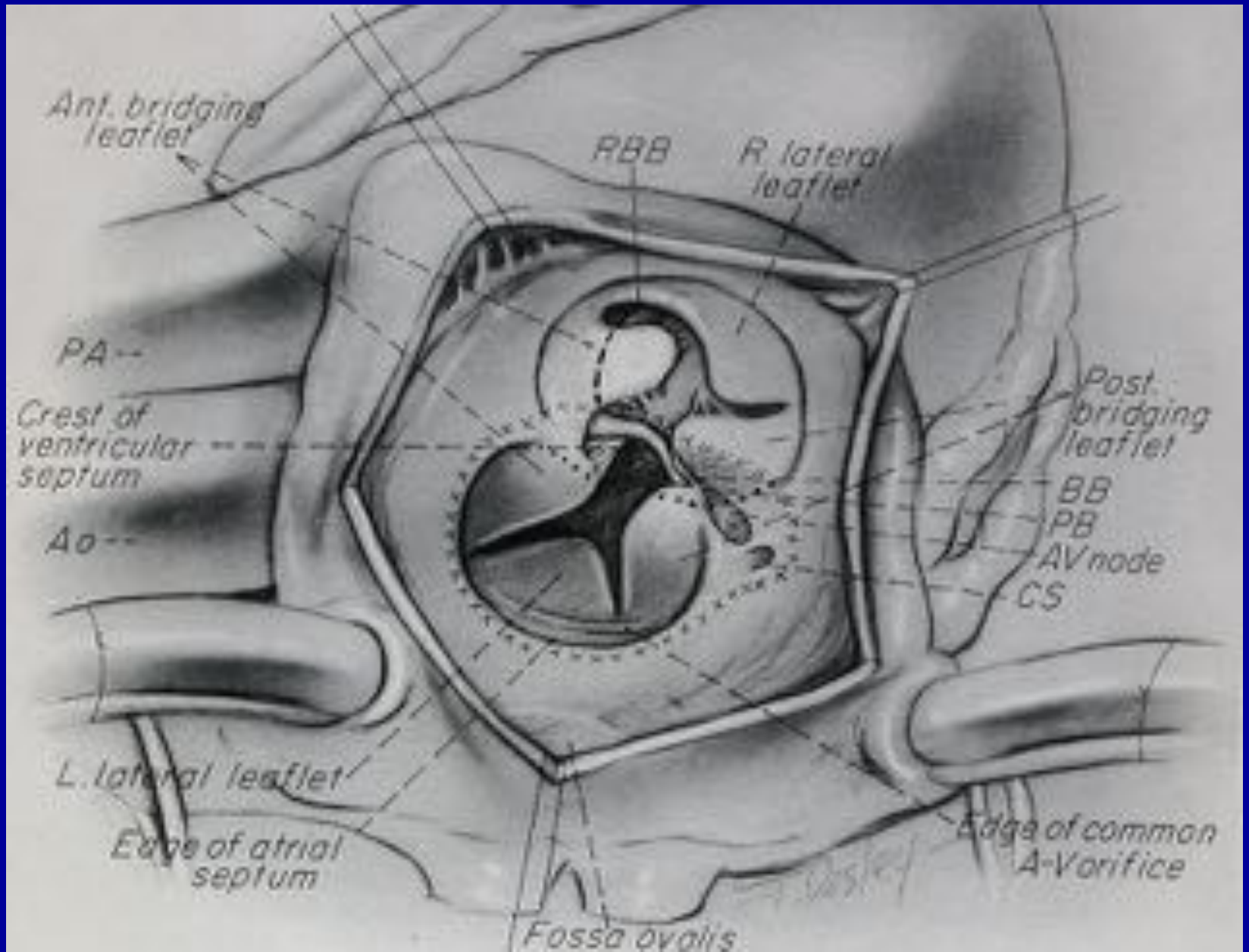

AV septal defect

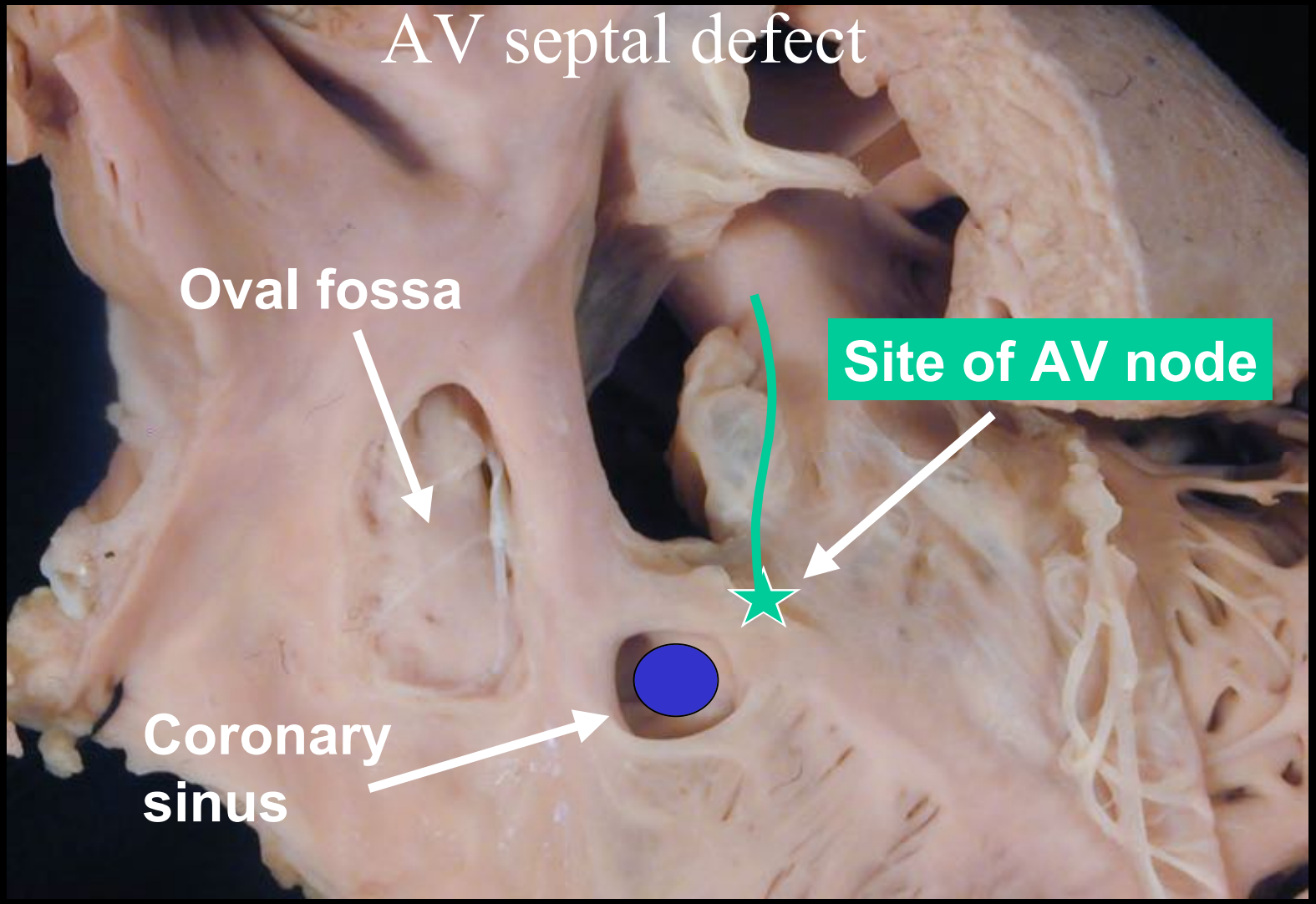

CAVC/CAVp cloisonnement atrial

Eviter le tissu de conduction; 2 possibilités

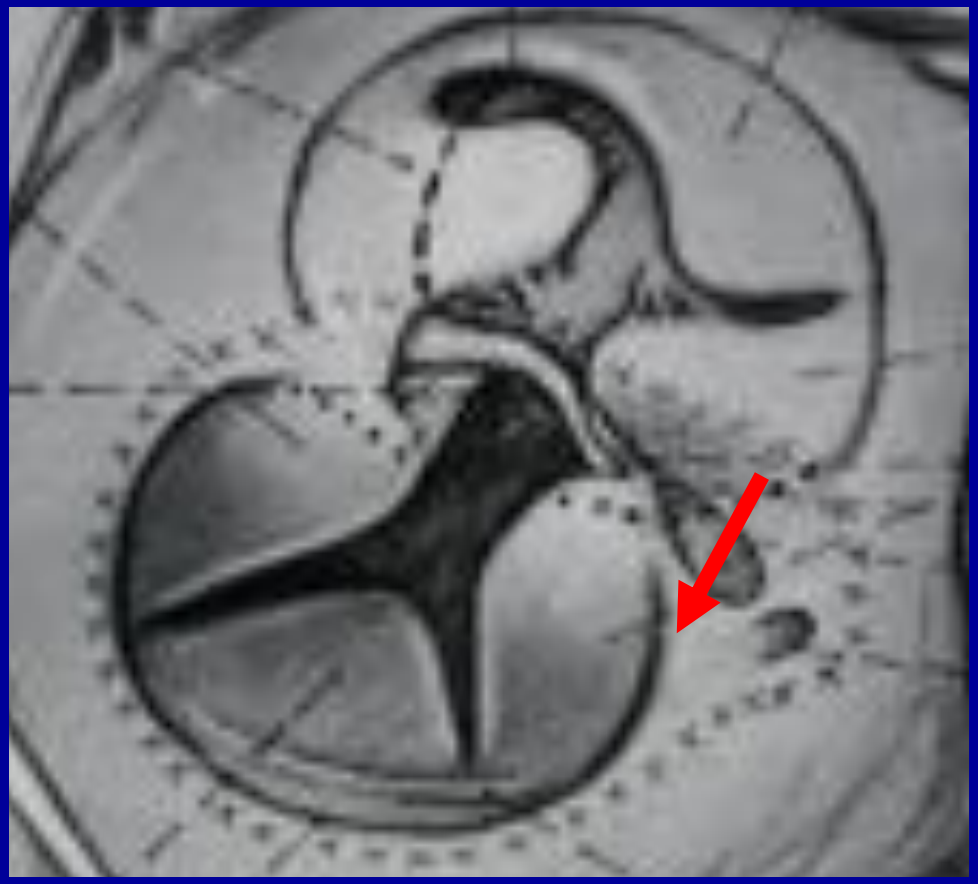

- La valve « mitrale » -
La « fente » - commissure septale?

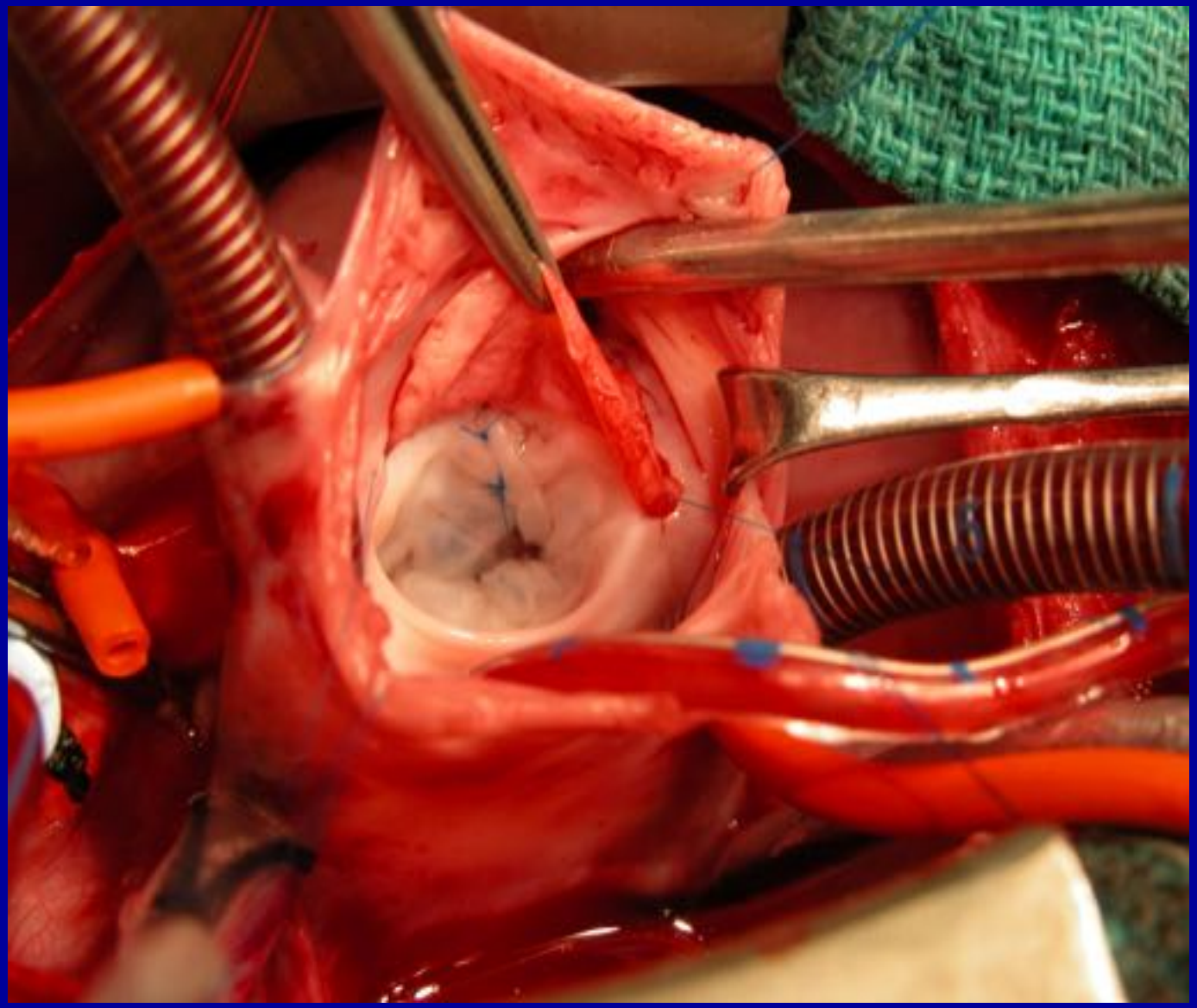

Valves of Heart in Diastole

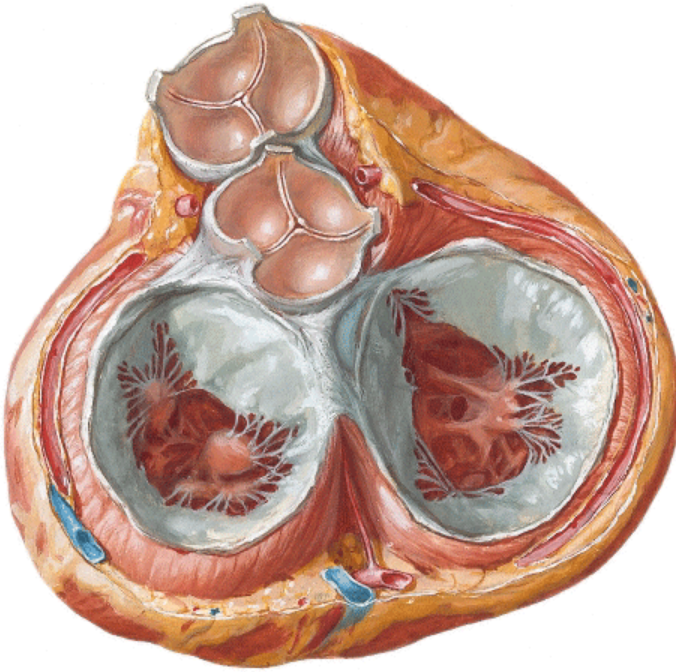

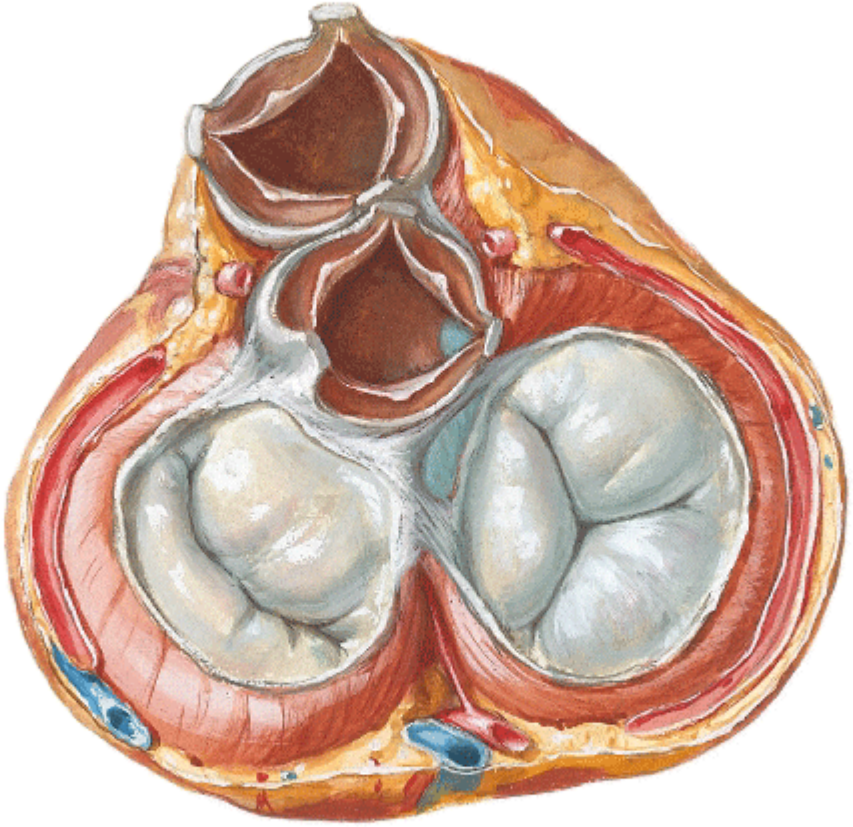

Valves of Heart in Diastole

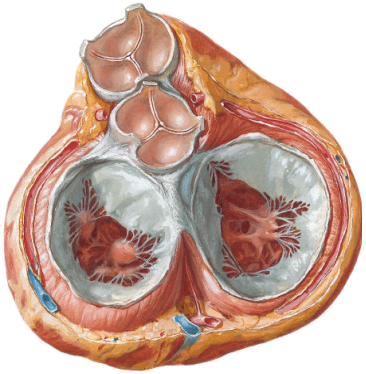

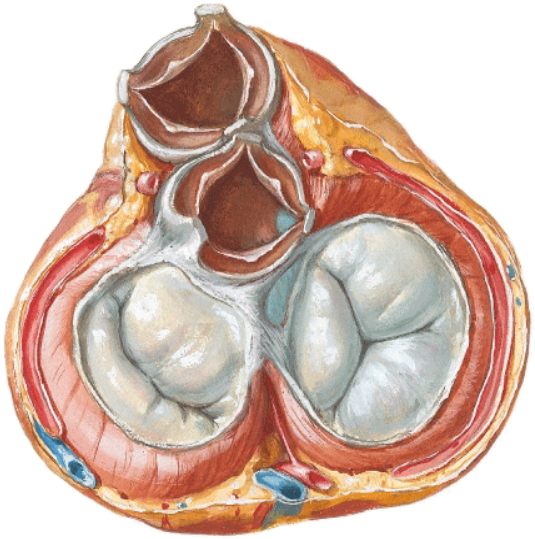

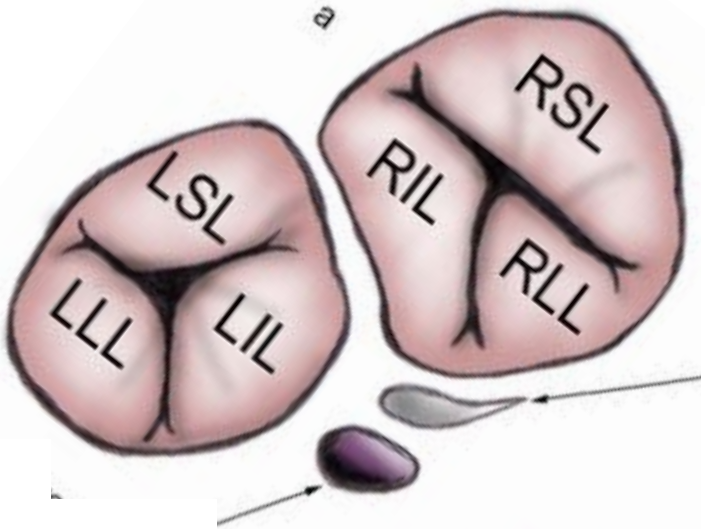

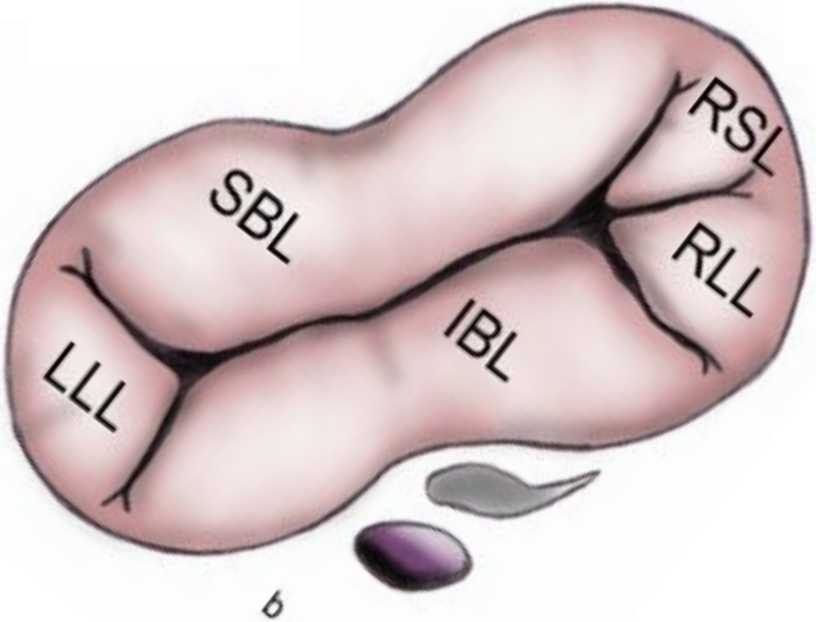

CHIRURGIE DU CAVC

- La valve « mitrale » -
La « fente » ou commissure septale

A - Suture systématique

B - Abstention (concept tri-valvulaire)

C - Suture partielle, élective

D - Suture impossible (valve en parachute potentielle)

E - Gestes complémentaires

* Commissuroplastie
* Annuloplastie

F - Remplacement valvulaire

CAVC : la valve AV gauche

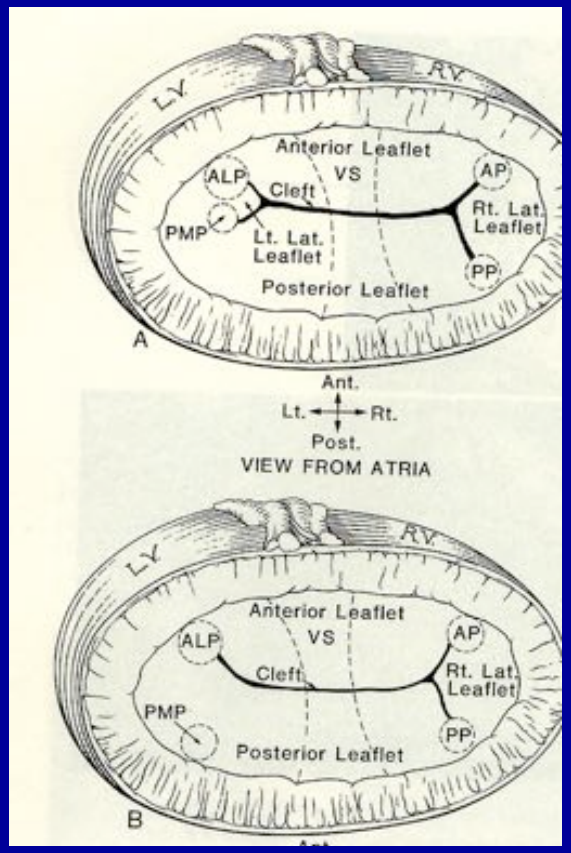

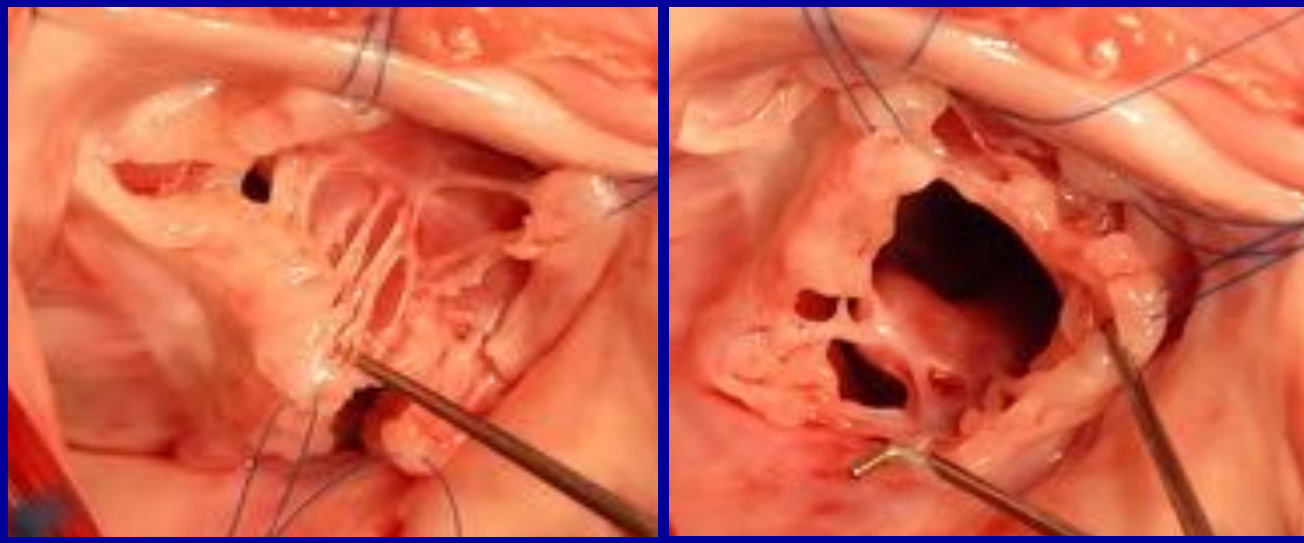

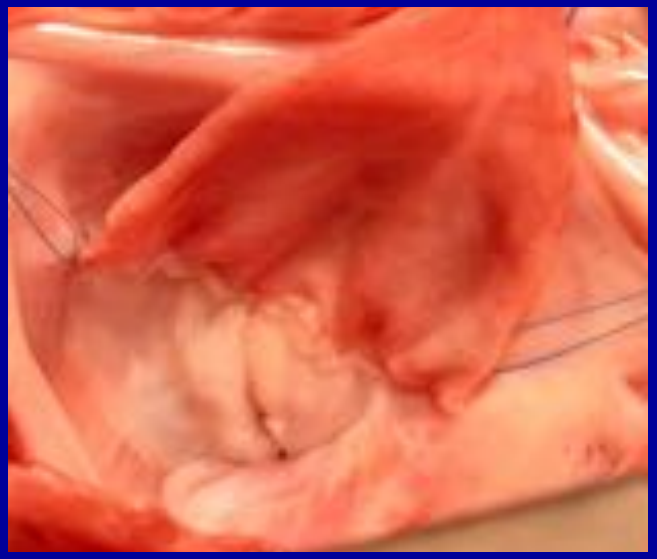

CAVC : la valve AV gauche après patch IV

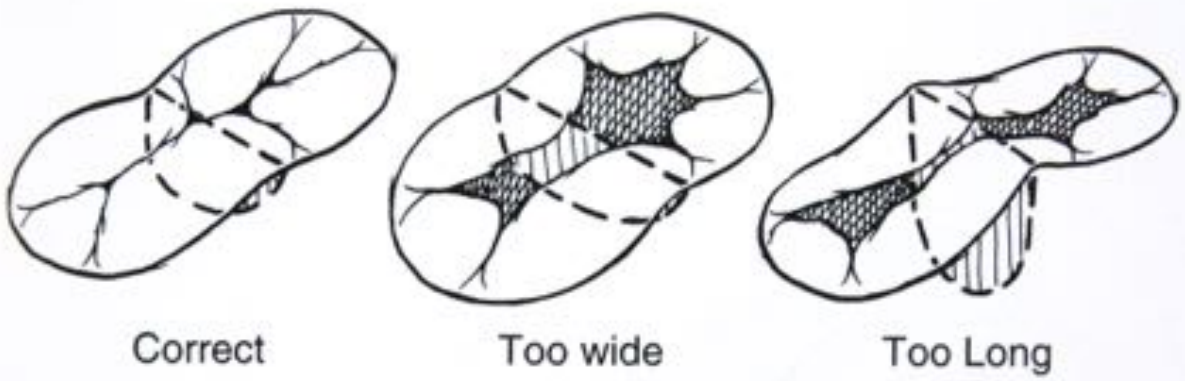

Figure 20-22 Depiction of ventricular septal portion of two-patch technique. If the patch is too wide, theoretically left ventricular outlet flow obstruction may be produced. If the patch is too long, with level of atrioventricular (AV) valves too high, there is a high probability of left AV valve regurgitation. (Modified from Lacour-Gayet and colleagues.[L9])

CHU TIMONE ENFANTS
Marseille, France

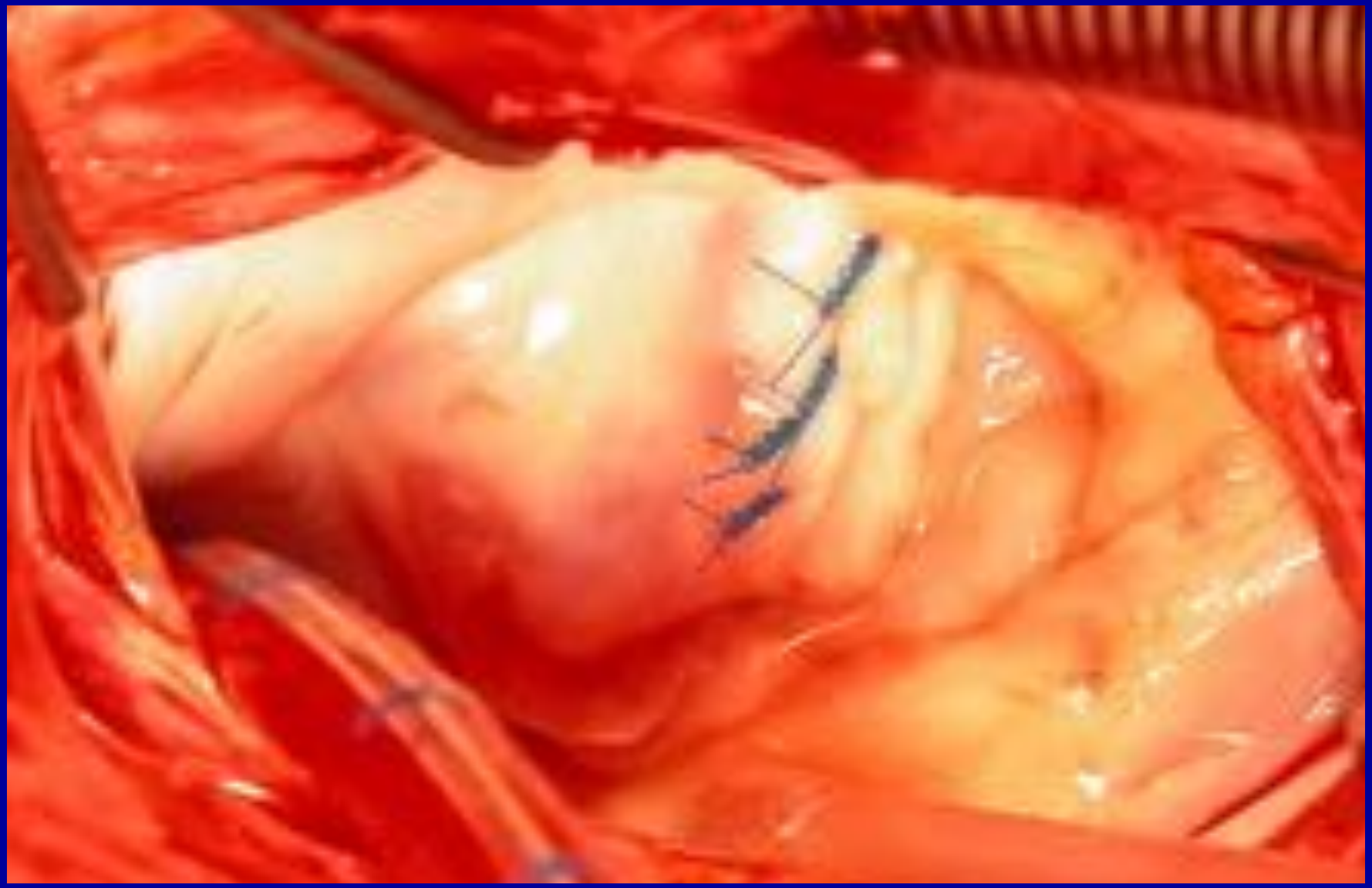

TWO PATCHES TECHNIQUE

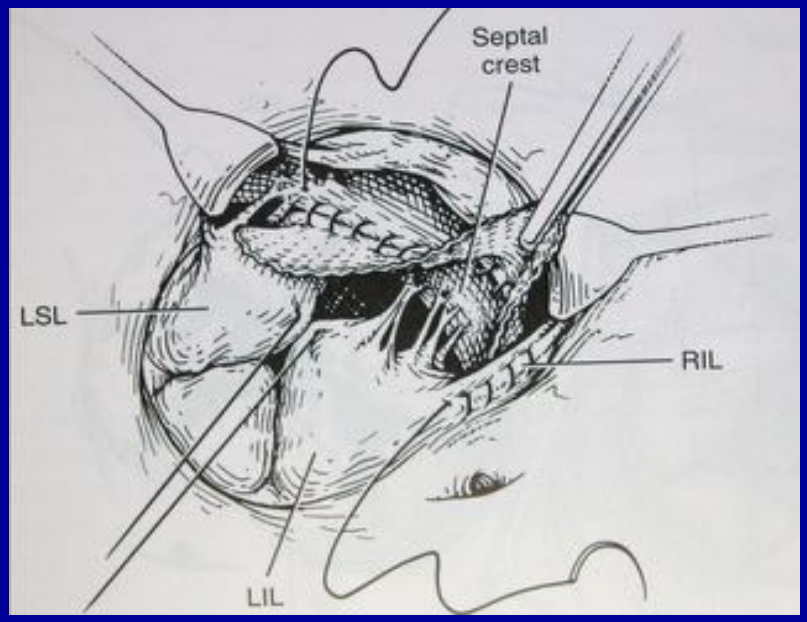

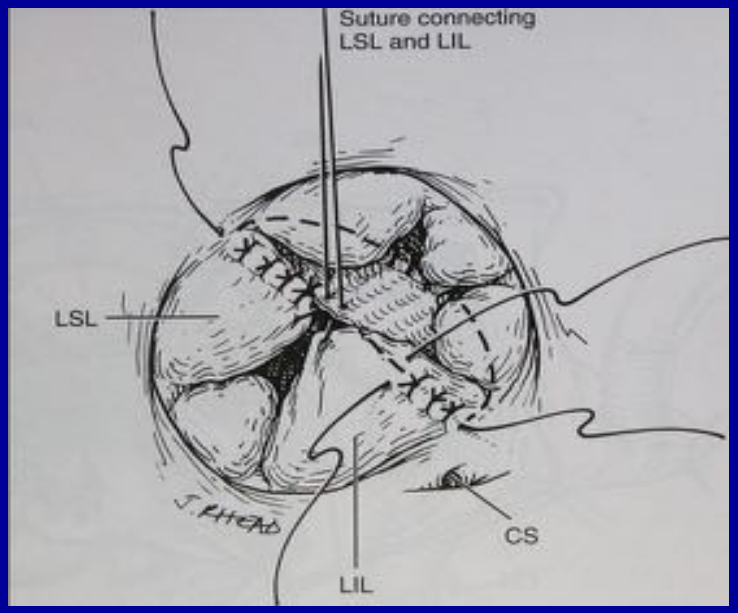

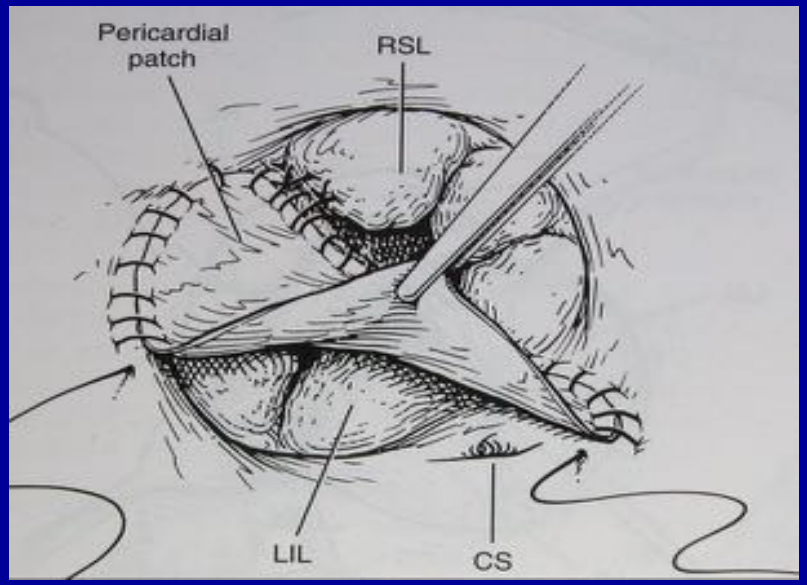

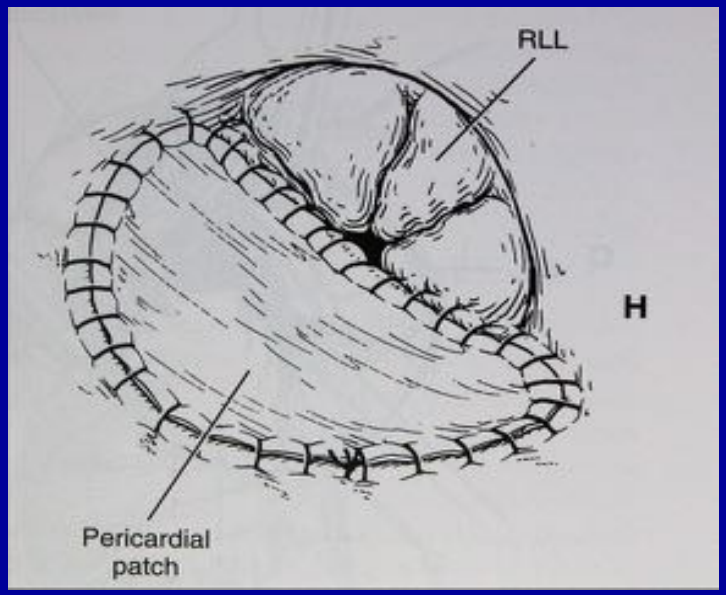

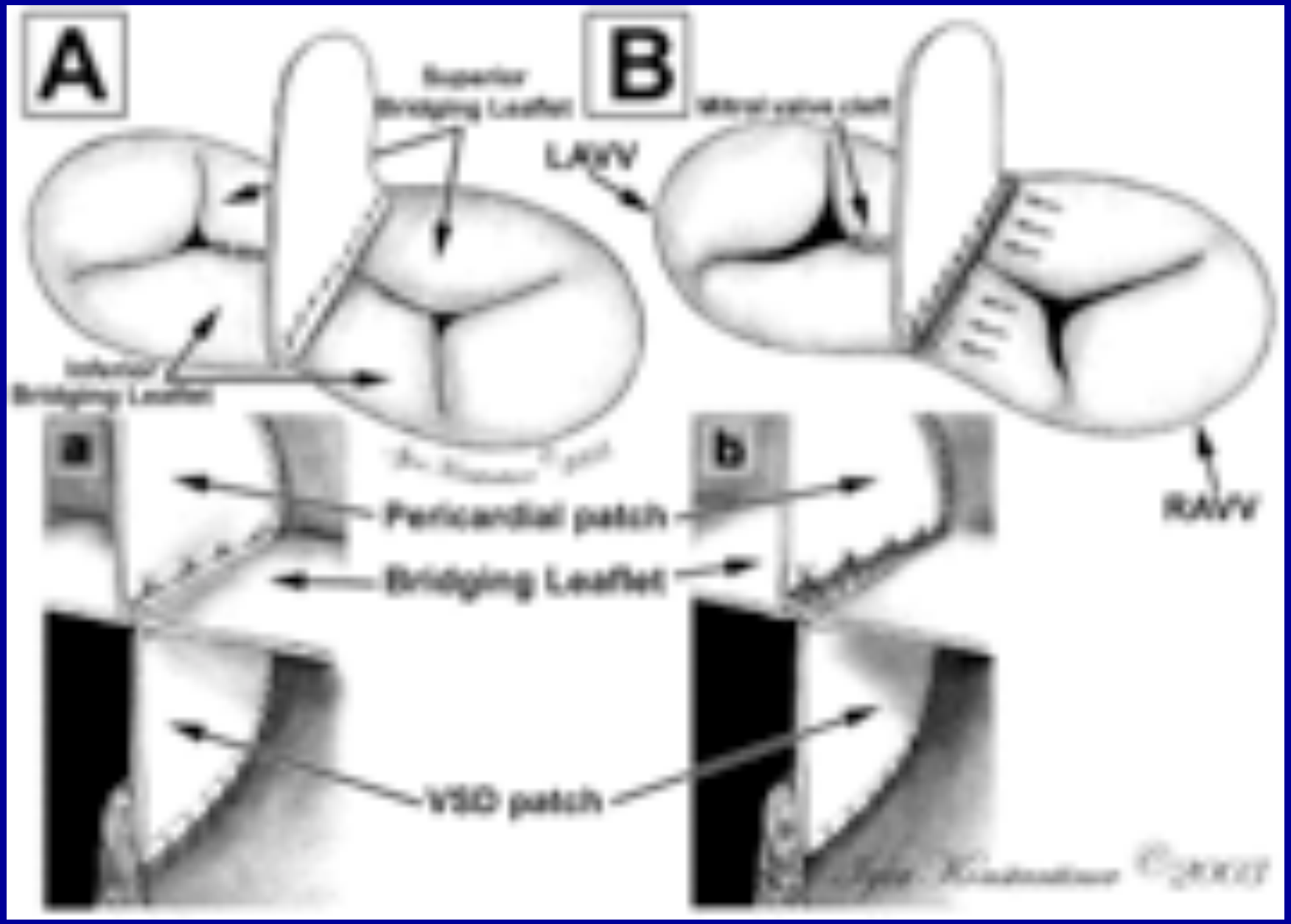
A
B
Superior
Bridging Leaflet
LA/V
Inferior
Bridging Leaflet
a
b
Pericardial patch
Bridging Leaflet
RA/V
VSD patch

Atrioventricular Canal: Modified Single Patch Technique

Graham R. Nunn

A single surgeon experience using a modified single patch technique for the repair of 128 patients with complete atrioventricular canal is presented. Thirty-day mortality was 1.6%. Follow-up of these patients has shown no incidence of significant residual ventricular septal defect, a 2.3% incidence of reoperation on the mitral valve, and no instances of left ventricular outlet obstruction requiring resection in the follow-up period. Comparisons are drawn between these results and the author's own experience with repair of complete atrioventricular canal using a two-patch technique (46 cases) and repair of partial atrioventricular canal (126 cases) to shed light on late valve function and left ventricular outlet obstruction in all groups.

Semin Thorac Cardiovasc Surg Pediatr Card Surg Ann 10:28-31 © 2007 Elsevier Inc. All rights reserved.

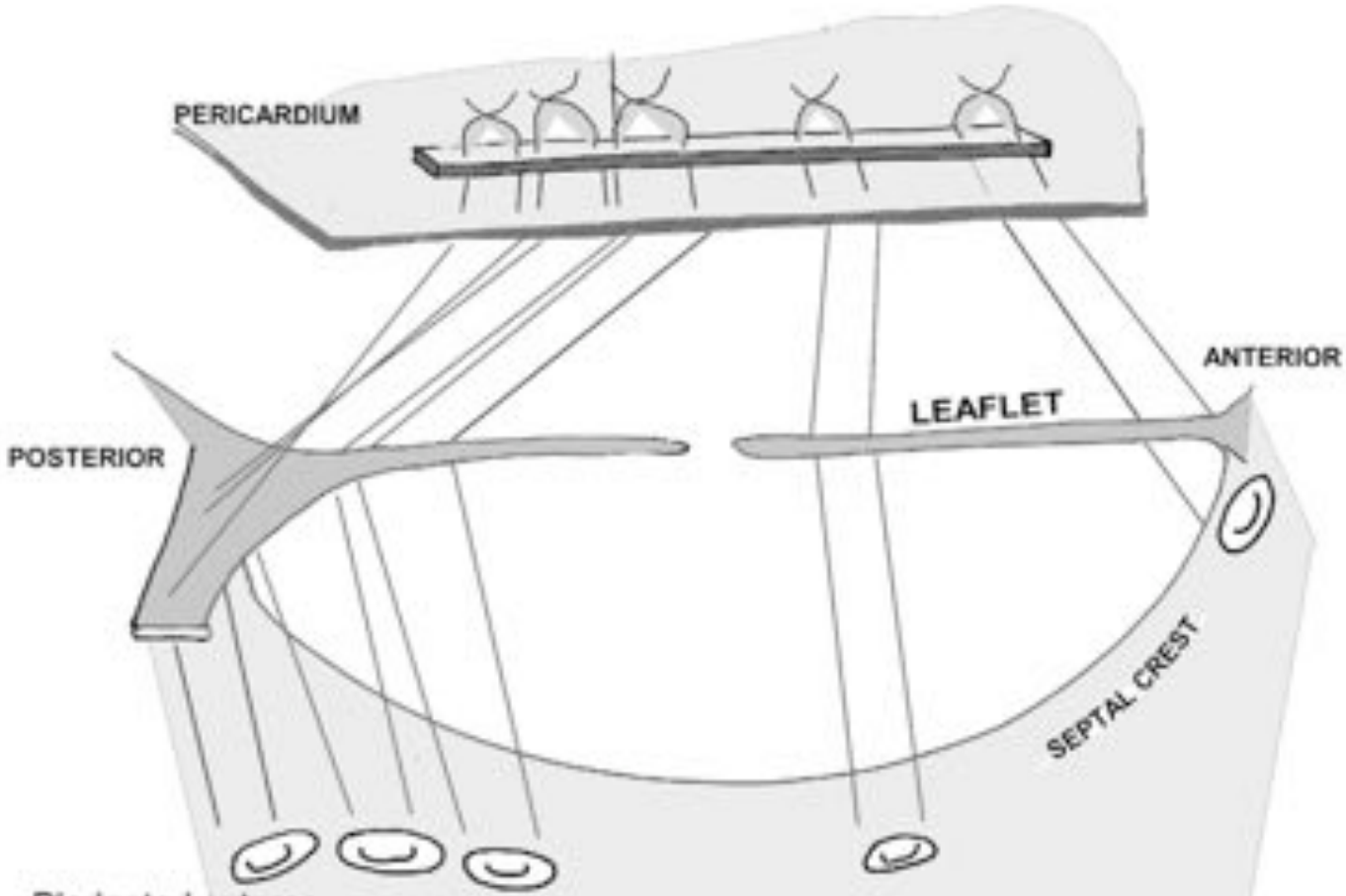

Pledgeted sutures placed well away from the septal crest posteriorly.

Modified Single Patch Technique

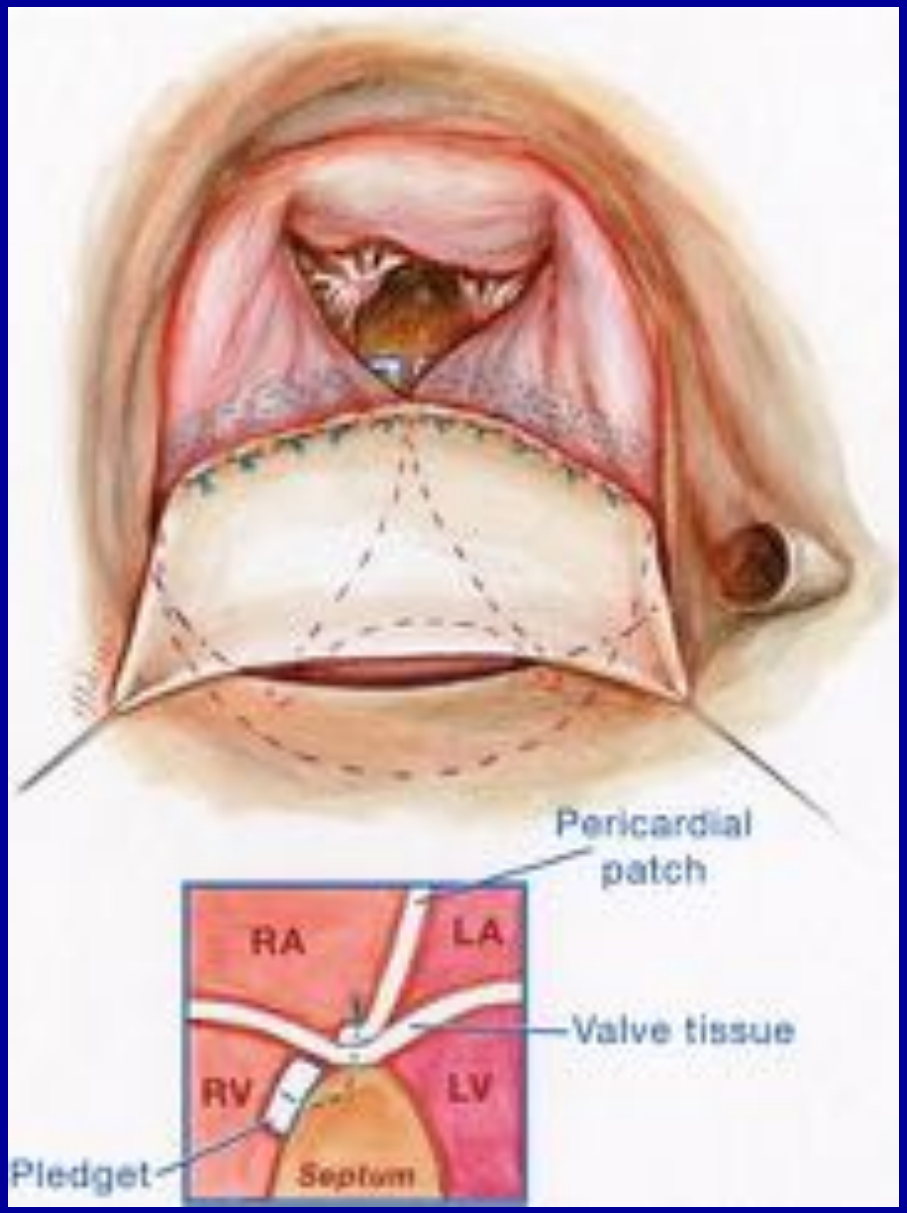
Pericardial patch
RA
LA
Valve tissue
RV
LV
Pledget
Septum

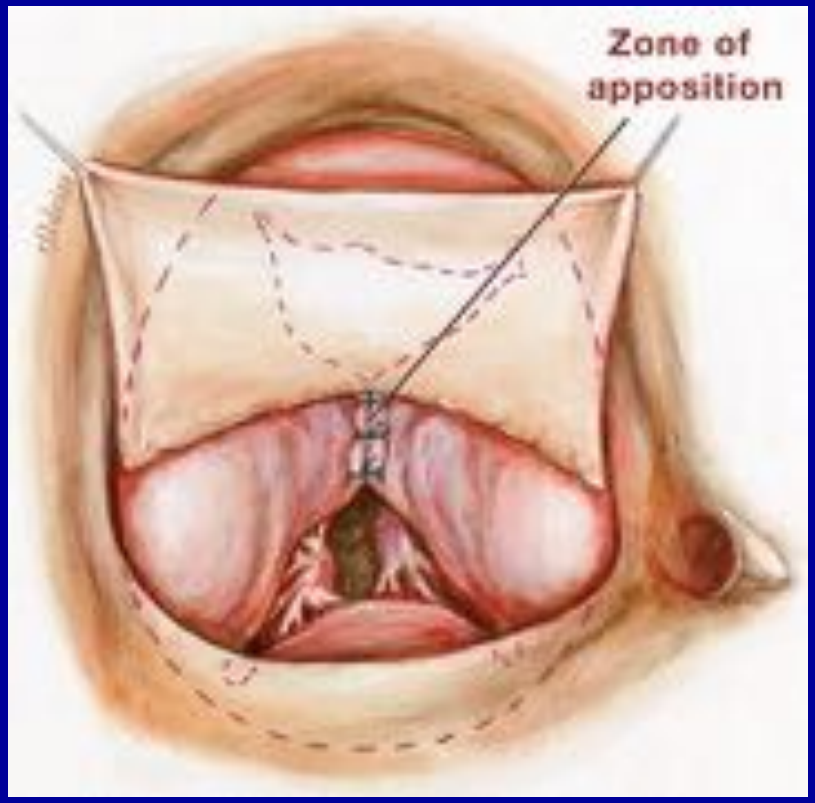
Zone of
apposition

CHIRURGIE DU CAVC
que retenir?

Selon état pré-op:

HTAP sans fuite (résistances)

HTAP avec fuite, gros shunt IV

A - risque de BAV

B - risque de sténose valve AV G (voire D)

C – risque d'IM (shunt VG-OD?)

D – CIV résiduelle?

E – Dysfonction ventriculaire (taille patch?)

CHIRURGIE DU CAVC

comment préparer la réa?

Fermeture thoracique différée

fonction VD? Déséquilibre? Taille patch?

Entrainement par pace maker

fréquence? BAV? Séquence A puis V+++?

Laisser un FOP?

utile si pas de fuite ou de sténose

et si HTAP

dangereux sinon

CAV partiels

Sémantique

partiel vs intermédiaire

Clinique

Symptomatologie de CIA

Chirurgie

Thoracotomie

Se méfier des CAV partiels symptomatiques < 1 an

Série personnelle: 12 cas sur 136

6 retard staturo-pondéral sévère

9 ostium primum très large 2 « O. Unique »

déséquilibre Dt > Gch

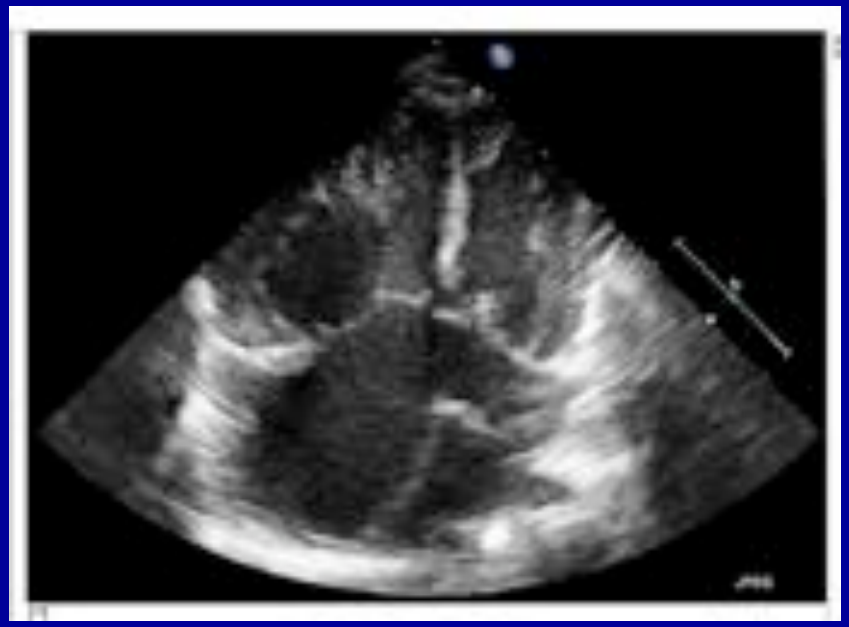

8 CAVi CIV plus que petite

2 “cœur tri atrial“

1 “triple orifice mitral“

CHIRURGIE DU CAVC
Conclusion

Quelque soit le patient, quelque soit son anatomie pré-op,

Pb de dénutrition et d'insuffisance cardiaque

Pb de l'HTAP

Pb conductifs

Pb de fuite ou de sténose des valves auriculo-ventriculaires