ATRESIE PULMONAIRE A SEPTUM OUVERT

Dr Régis GAUDIN

DU REANIAMTION DES CARDIOPATHIES CONGÉNITALES - PARIS

UNIVERSITÉ PARIS DESCARTES

ASSISTANCE PUBLIQUE HÔPITAUX DE PARIS

imagine INSTITUT DES MALADIES GÉNÉTIQUES

European Reference Networks

Necker ENFANTS MALADES HÔPITAL UNIVERSITAIRE

Introduction

Carastéristiques de la cardiopathie

-CIV par Malalignement

-Atrésie pulmonaire

-Major aorto-pulmonary collaterals = MAPCAs

Introduction

-L’anatomie intra-cardiaque n’est quasiment jamais un problème

-Le pronostic dépends des caractéristiques de la vascularisation pulmonaire

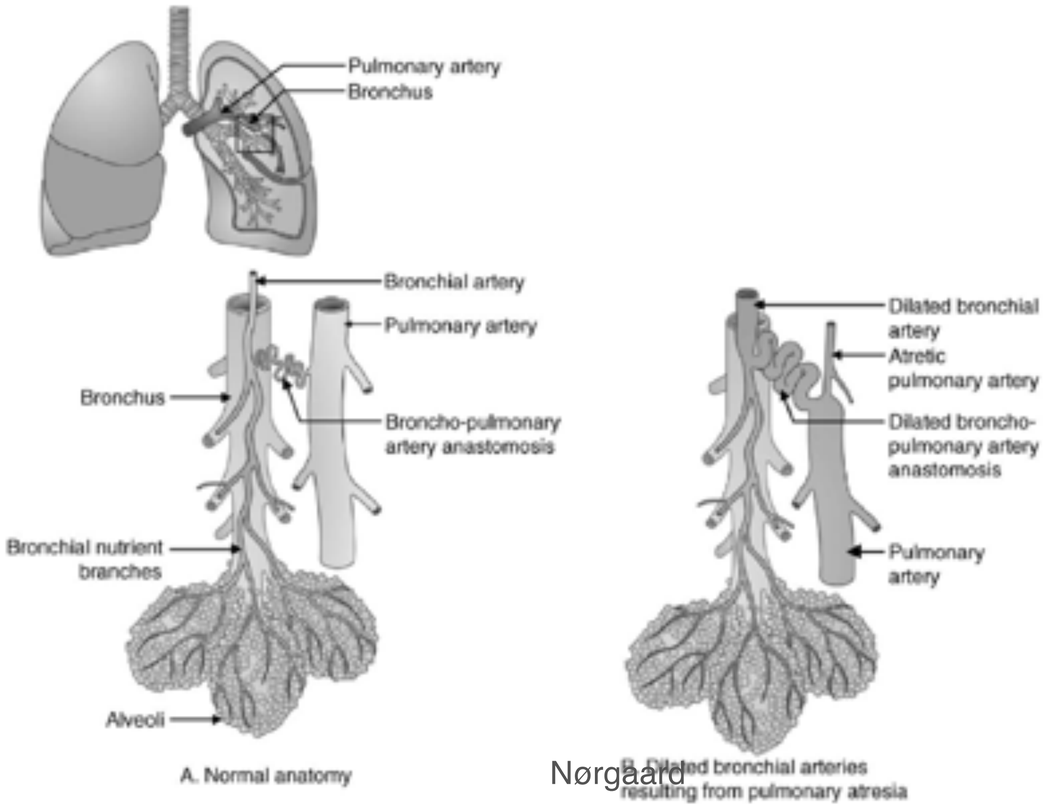

Nørgaard

Introduction

-L’anatomie intra-cardiaque n’est quasiment jamais un problème

-Le pronostic dépends des caractéristiques de la vascularisation pulmonaire

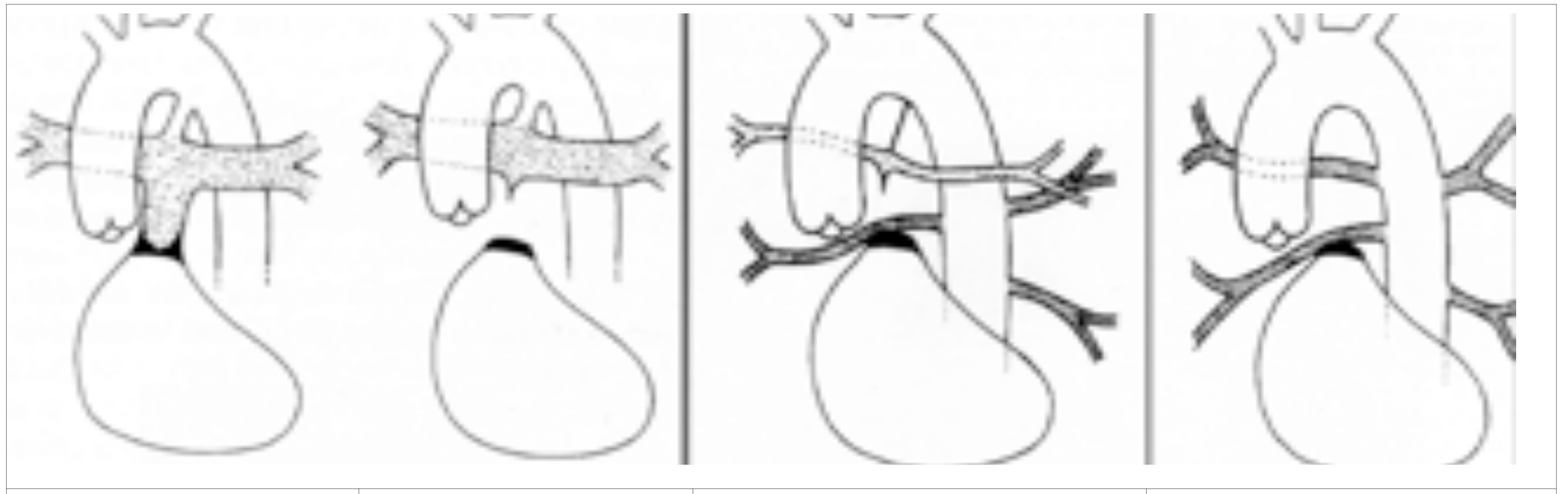

I	II	III	IV
A	A	B	C

Castaneda

STS

Nørgaard

Introduction

Castaneda 3 and 4

STS B and C

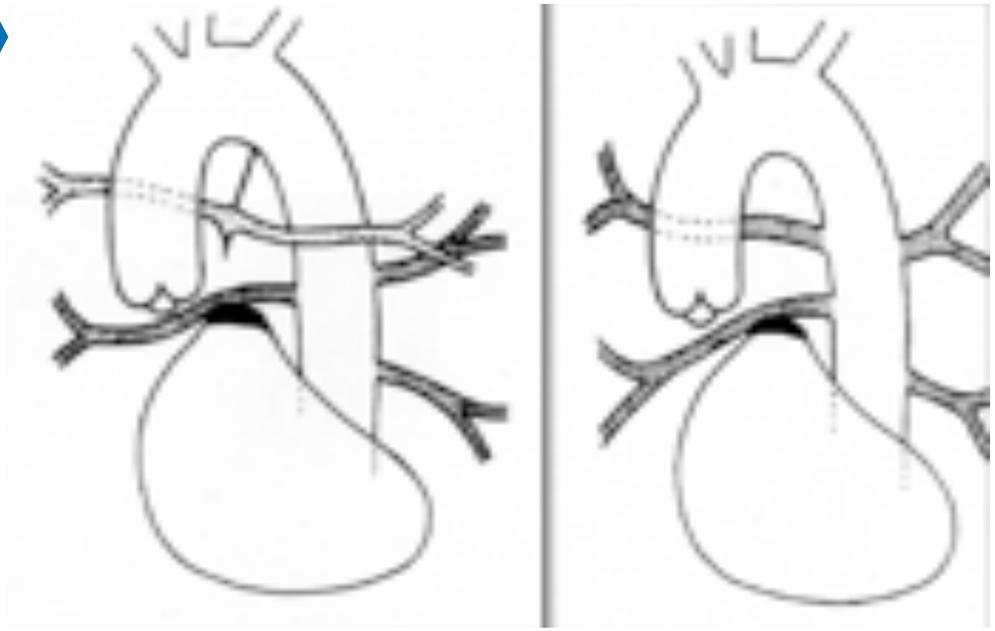

Vascularisation pulmonaire

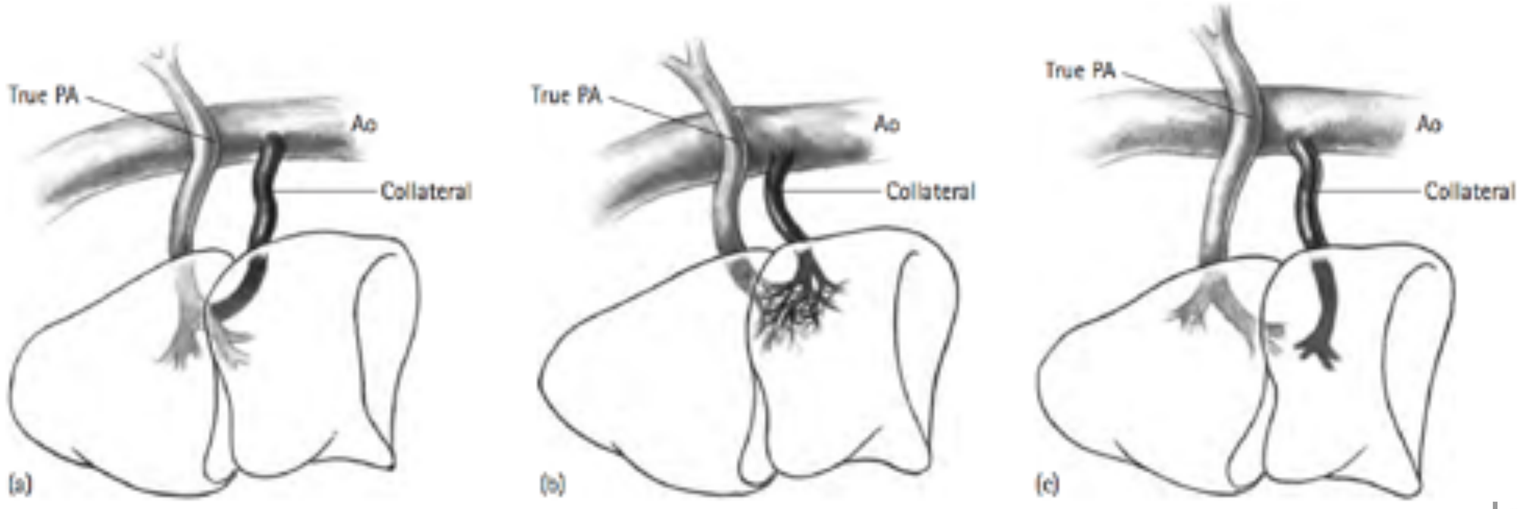

Jonas

Spectre large

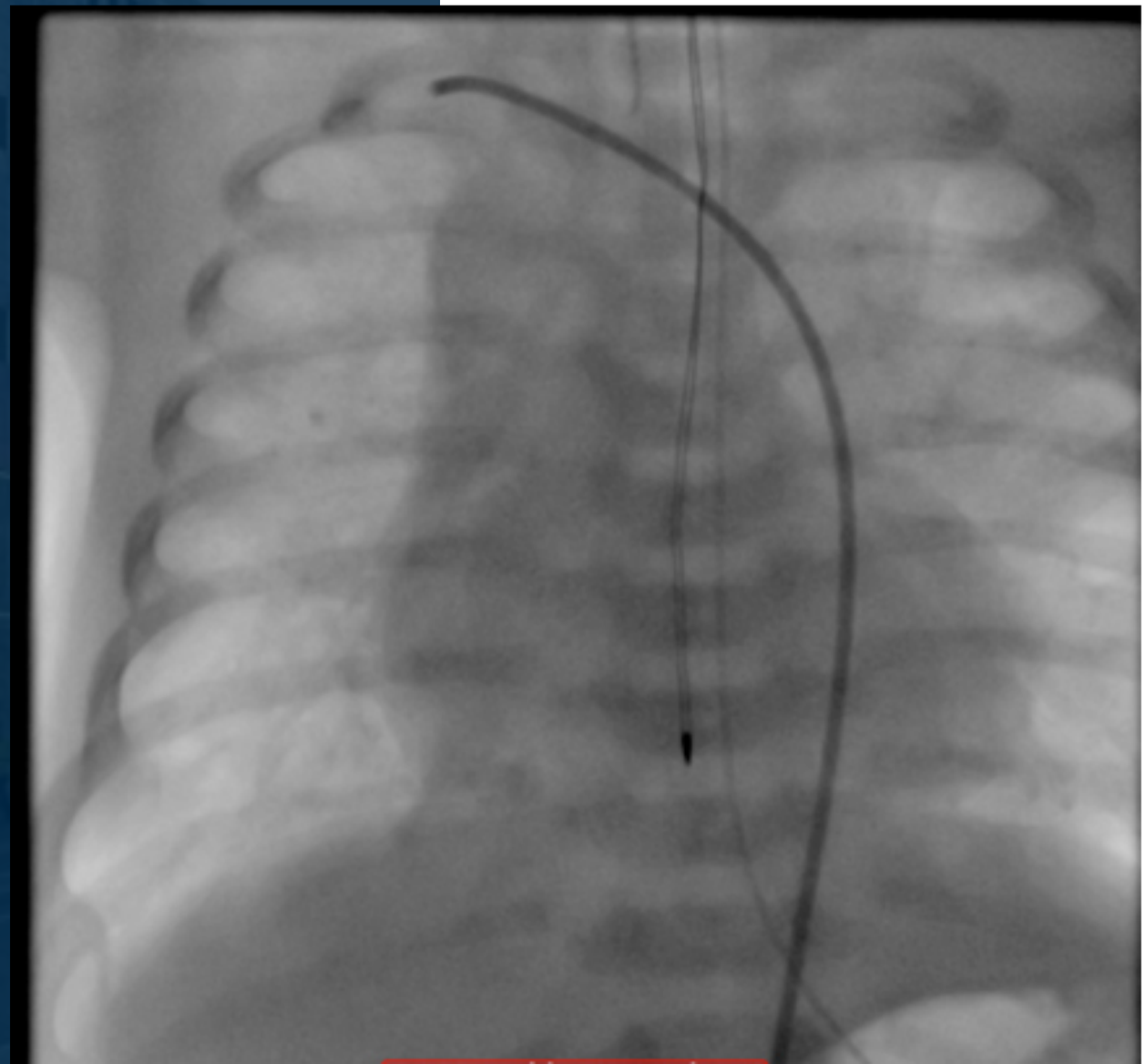

De forme avec petites AP mais arborisation normales et MAPCAs communicantes…

Spectre large

…aux formes sans AP centrales
avec uniquement des MAPCAs

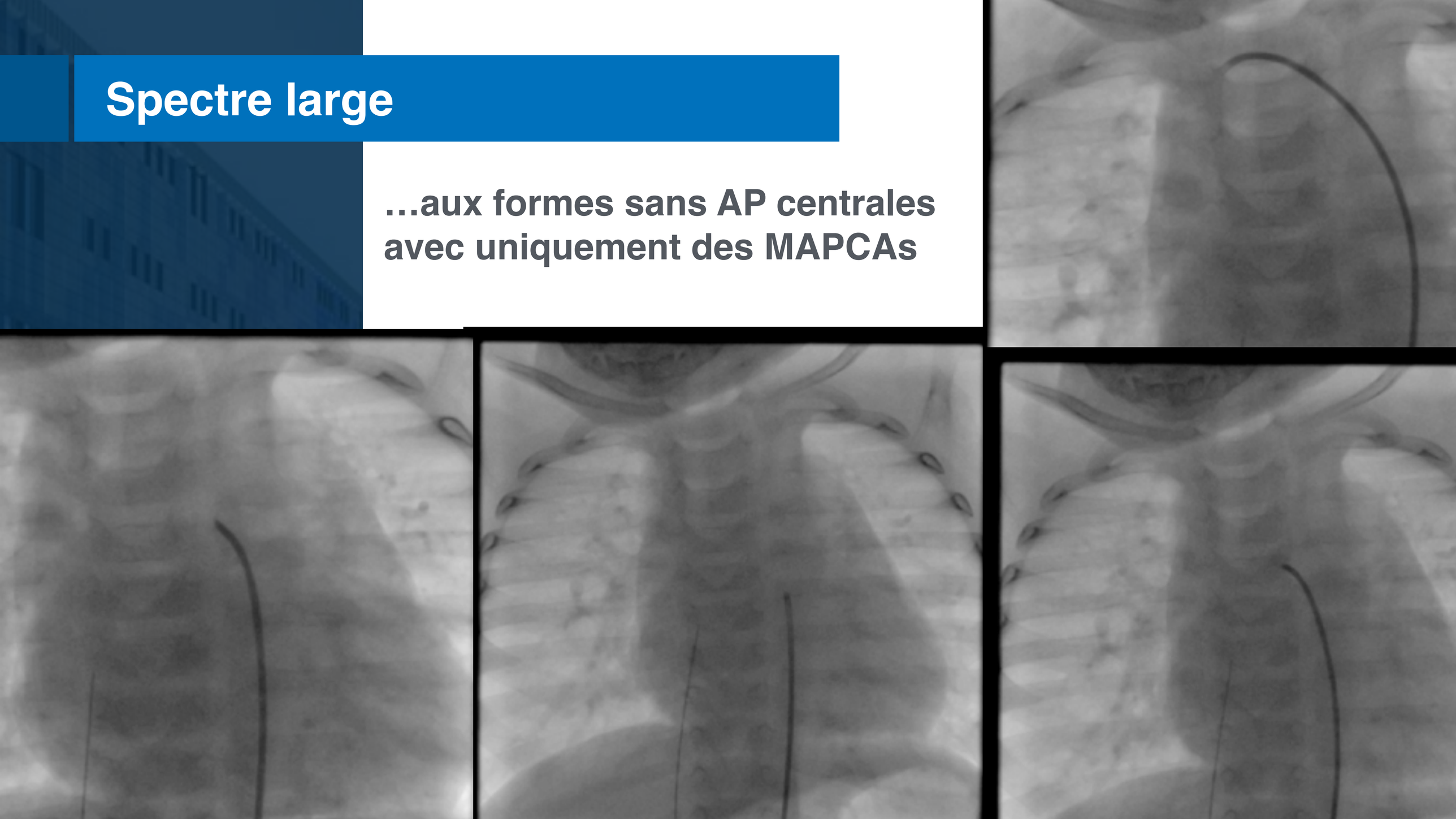

Spectre large

… formes avec petites AP avec des segments vascularisés soit par des MAPCAS, soit par les AP native, soit par les deux, soit par aucune

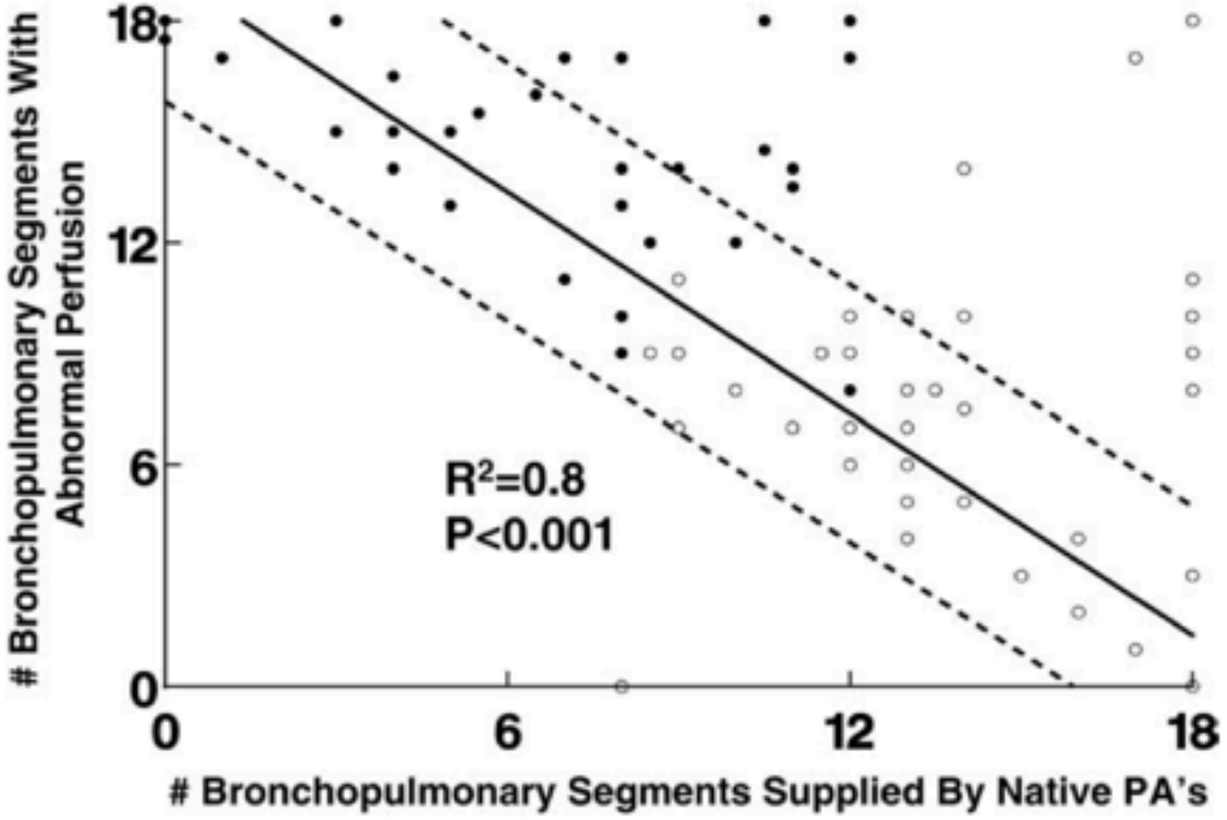

Jonas

Historique

La prise en charge a évolué, de l'absence de traitement vers une prise en charge précoce avec un taux élevé de réparations biventriculaires

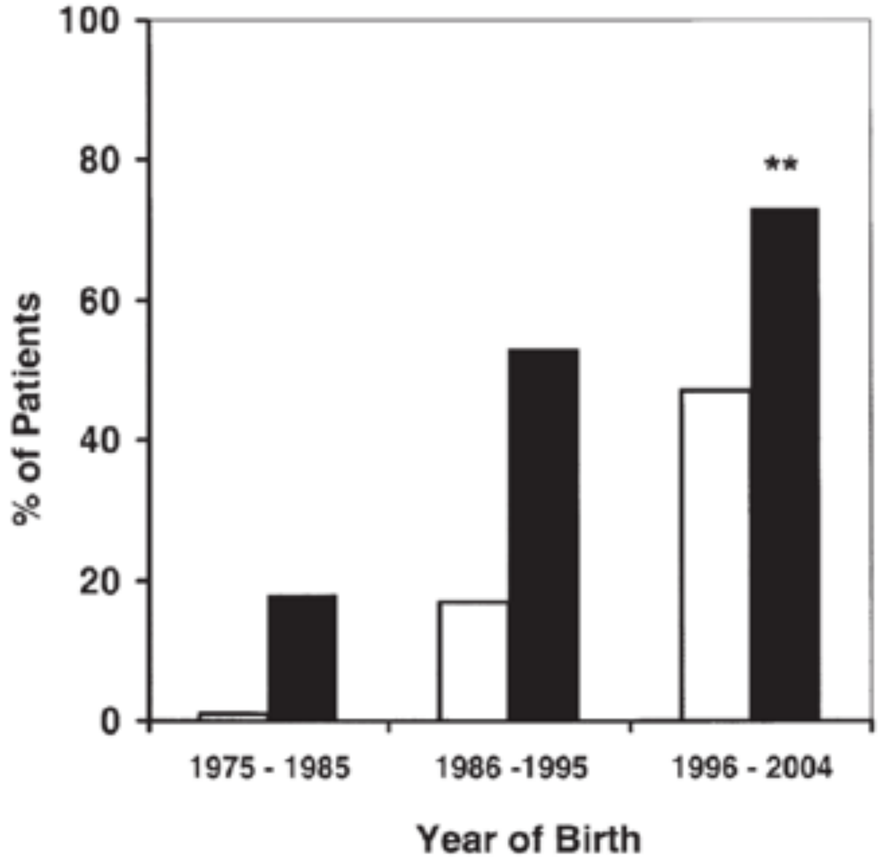

Spectre large de traitement

Buts à atteindre

-Reparation bi-ventriculaire

-Rapport de pression VD / VG bas

Spectre large de traitement

Buts à atteindre

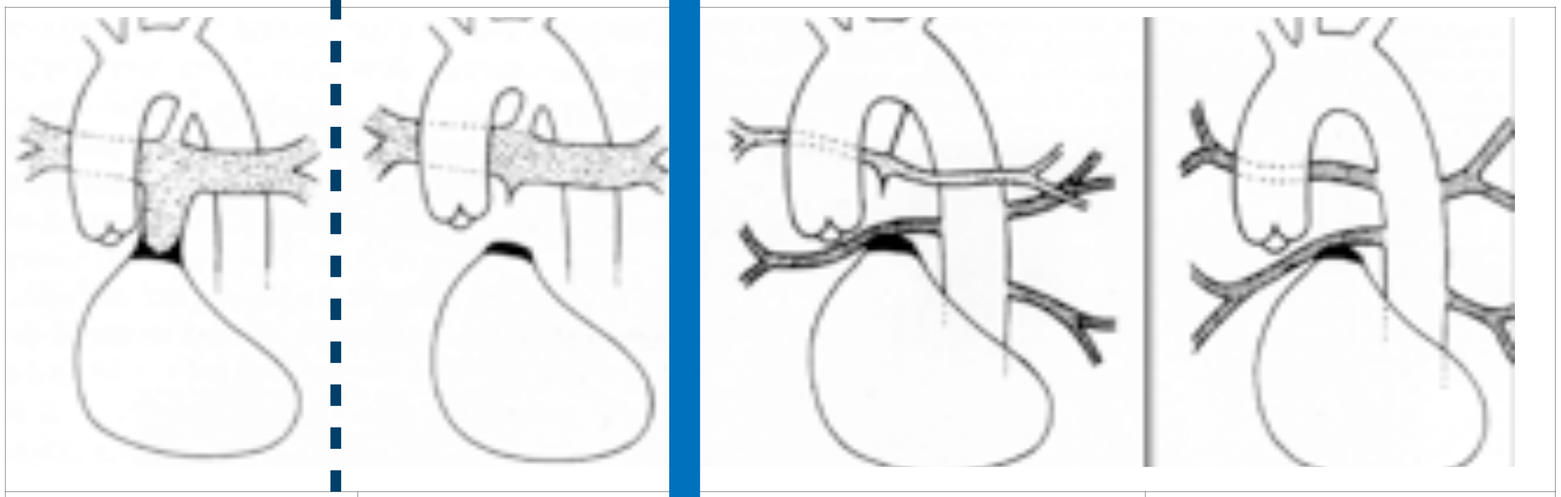

I	II	III	IV
A	A	B	C

Castaneda

STS

Nørgaard

Fallot

Stratégies multiples…

APSO type I / II

Notre stratégie

Présentation clinique

Cyanose à la fermeture du canal + très belles AP

Cure complète d’emblée

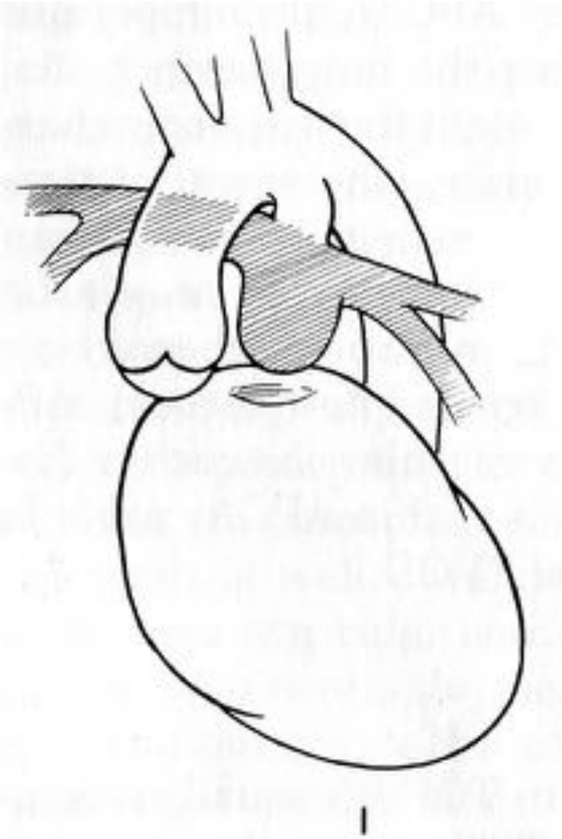

Notre stratégie

Présentation clinique

Cyanose à la fermeture du canal + petites AP

Ouverture VD-AP

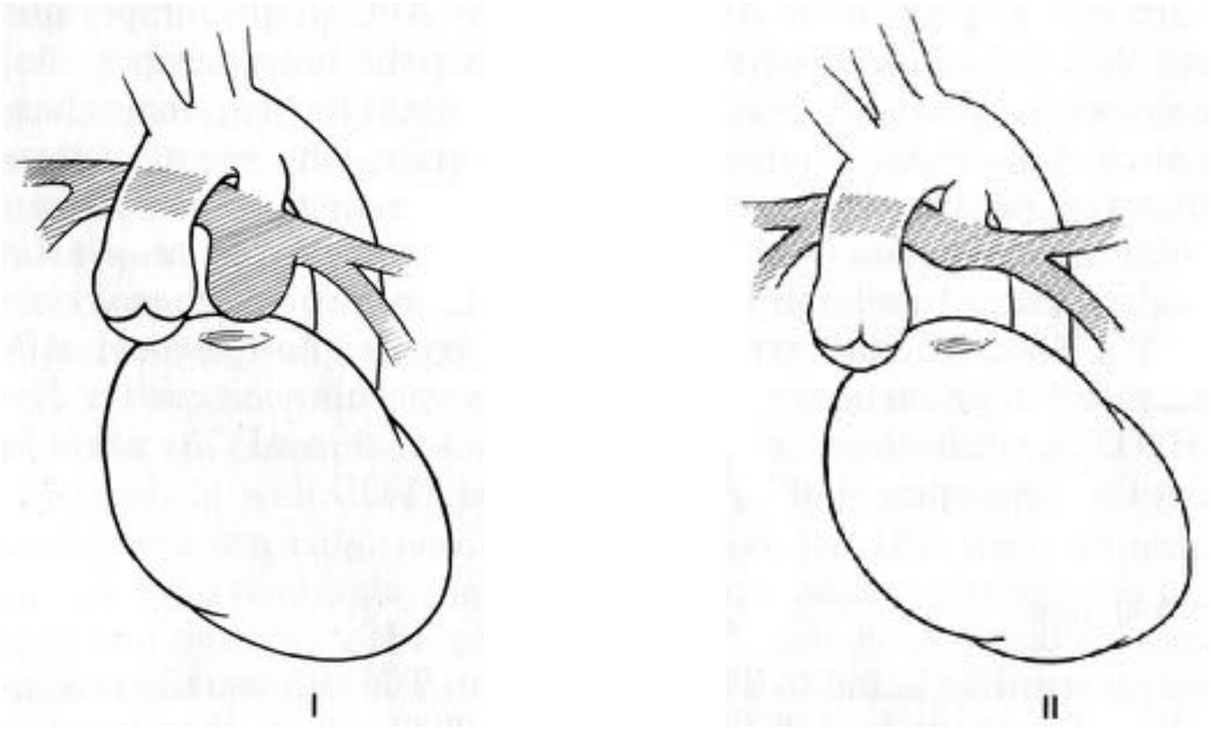

Notre stratégie

Présentation clinique

Cyanose à la fermeture du canal + petites AP

Ouverture VD-AP

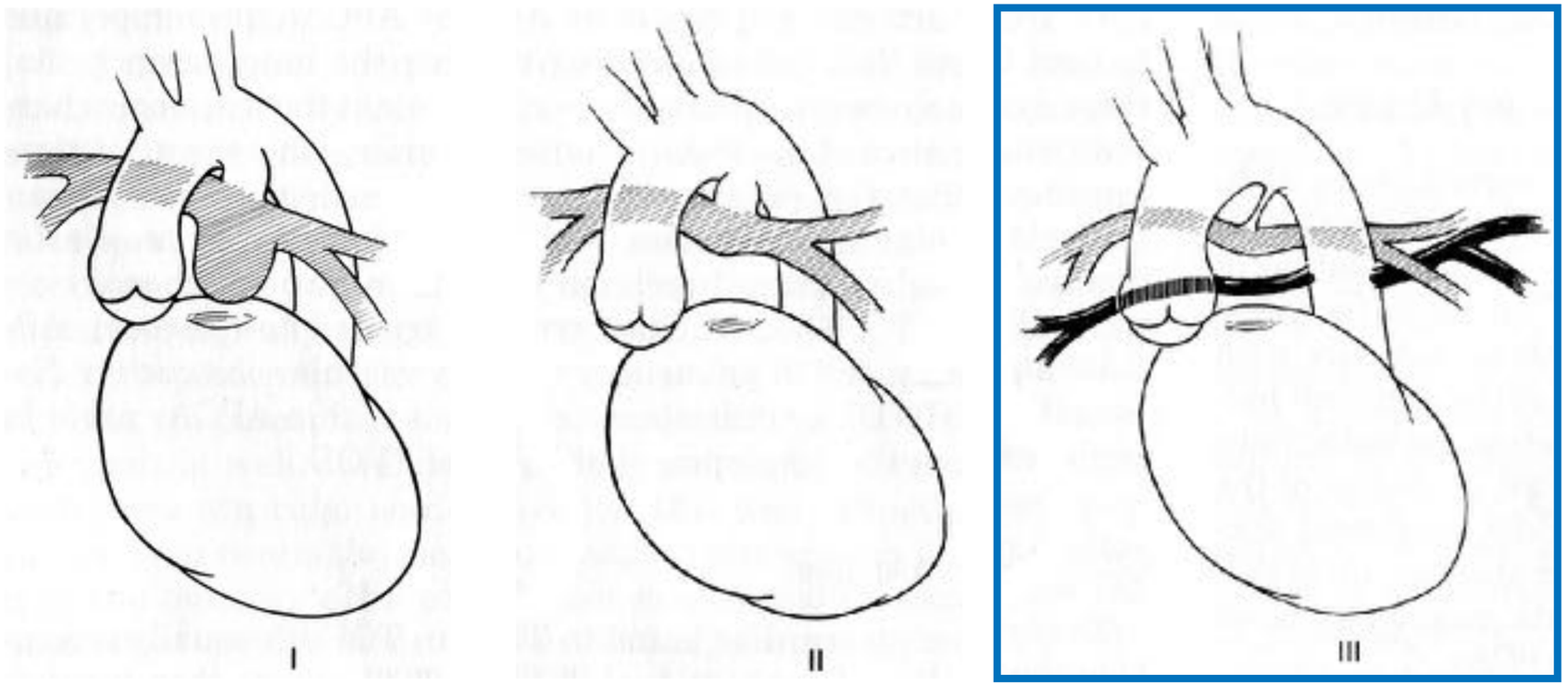

Notre stratégie

Ouverture VD-AP en première intention

Si impossible Blalock modifié

Rarement shunt central

Outcomes of palliative right ventricle to pulmon
for pulmonary atresia with ventricular

Marien Lenoir[a], Margaux Pontailler[a], Régis Gaudin[a], Sébastien Gerelli[a], Da
Bari Murtuza[a], Pascal R. Vouhé[a] and Olivier Ra

[a] Department of Pediatric Cardiac Surgery, University Paris Descartes and Sick Children Hospital, Paris, France
[b] Department of Pediatric Cardiology, University Paris Descartes and Sick Children Hospital, Paris, France

Rationale

- Meilleure stabilité hémodynamique sans vol diastolique coronaire
- Flux antérograde pulsatile dans les deux AP
- Pas de risque de thrombose
- Mortalité faible
- Donne un accès aux AP pour le KT
- Plus facile qu'un blalock quand la crosse est à droite

Drawbacks: ECC, X clamp…

Notre stratégie

Ouverture VD-AP en première intention

Si impossible Blalock modifié

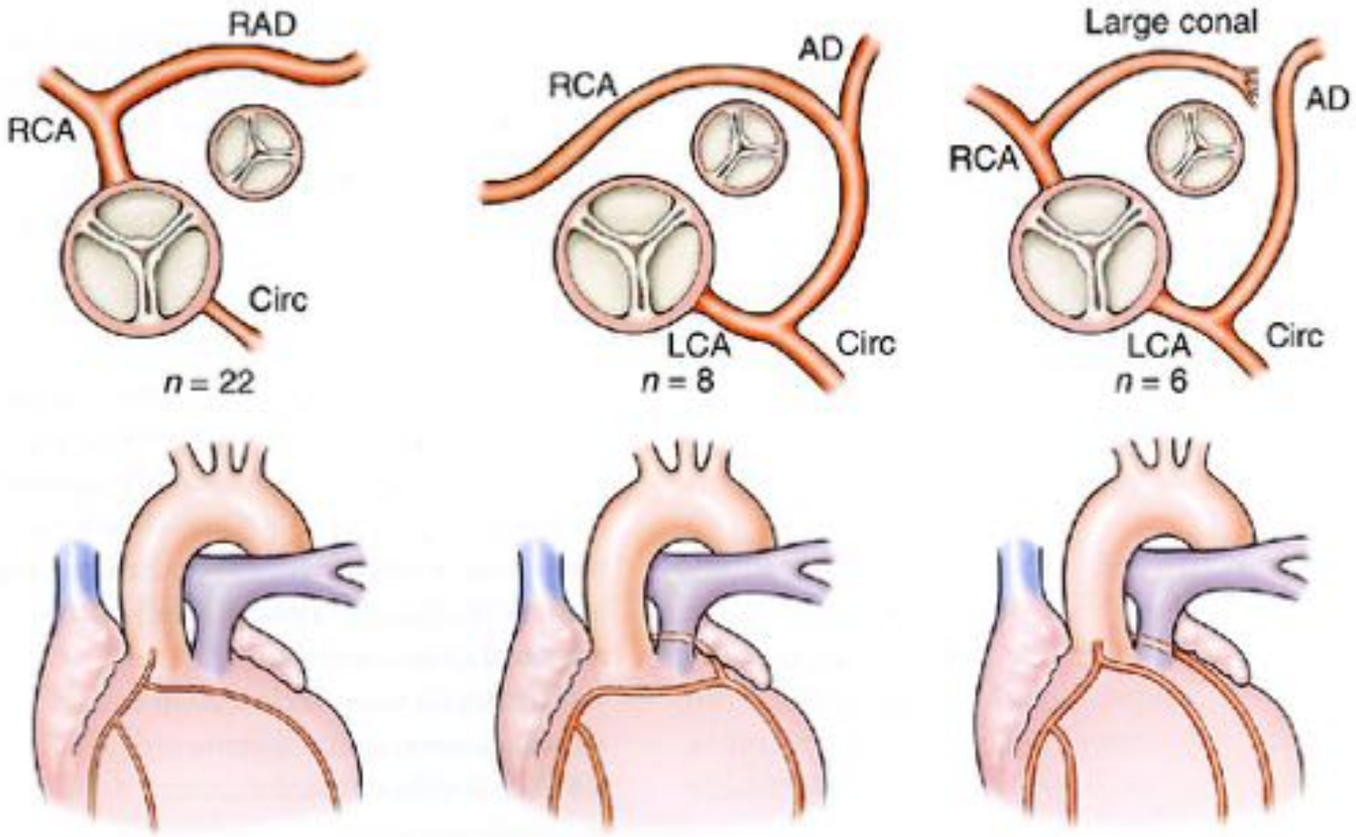

Ouverture VD-AP en première intention

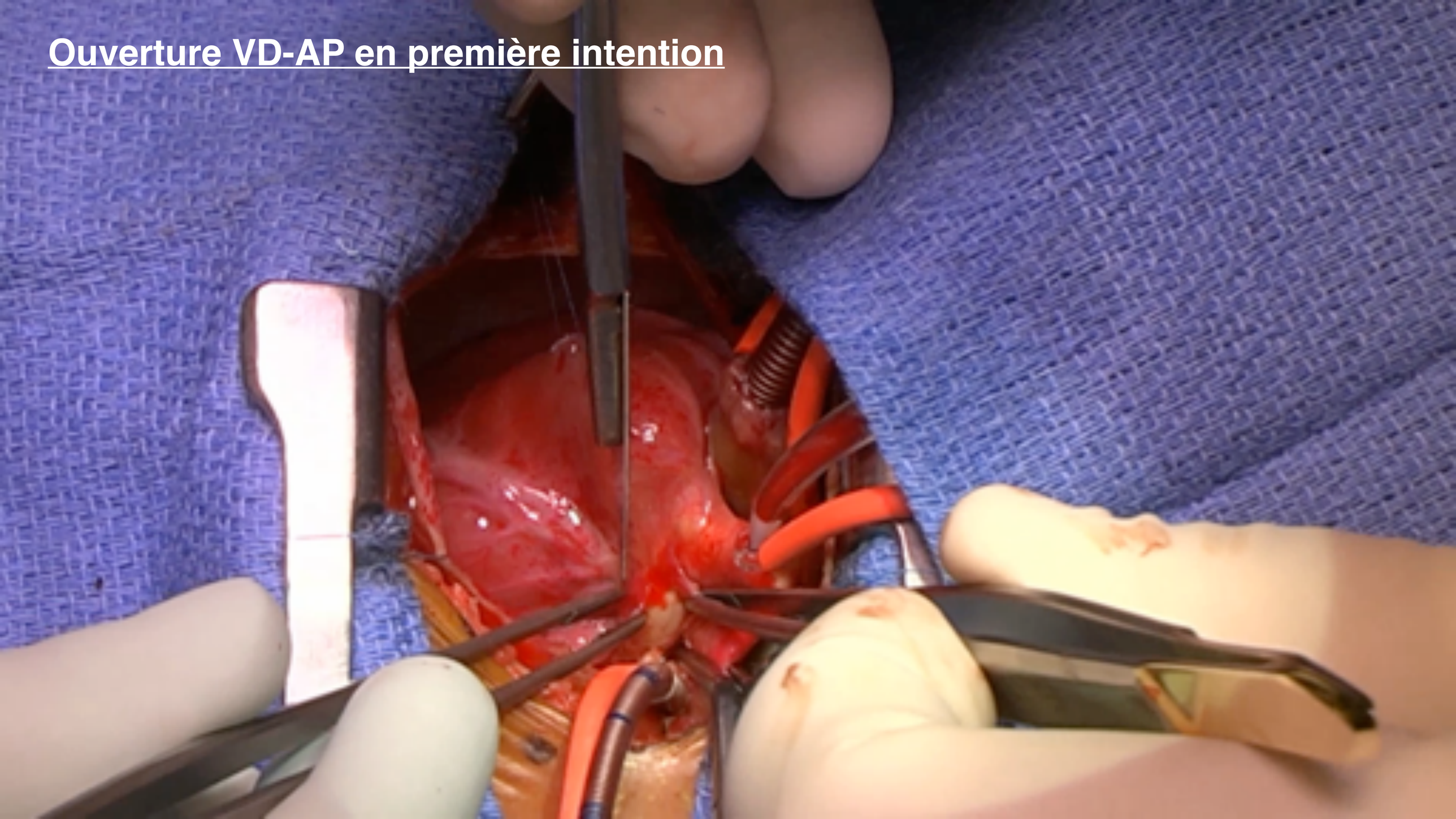

Notre stratégie

APSO type 2

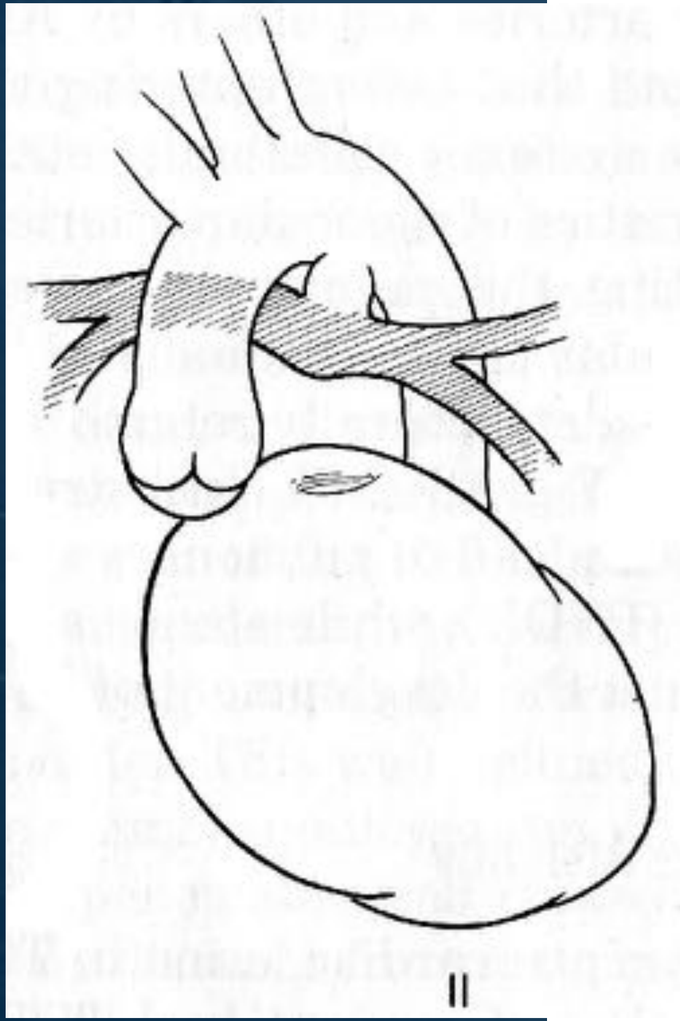

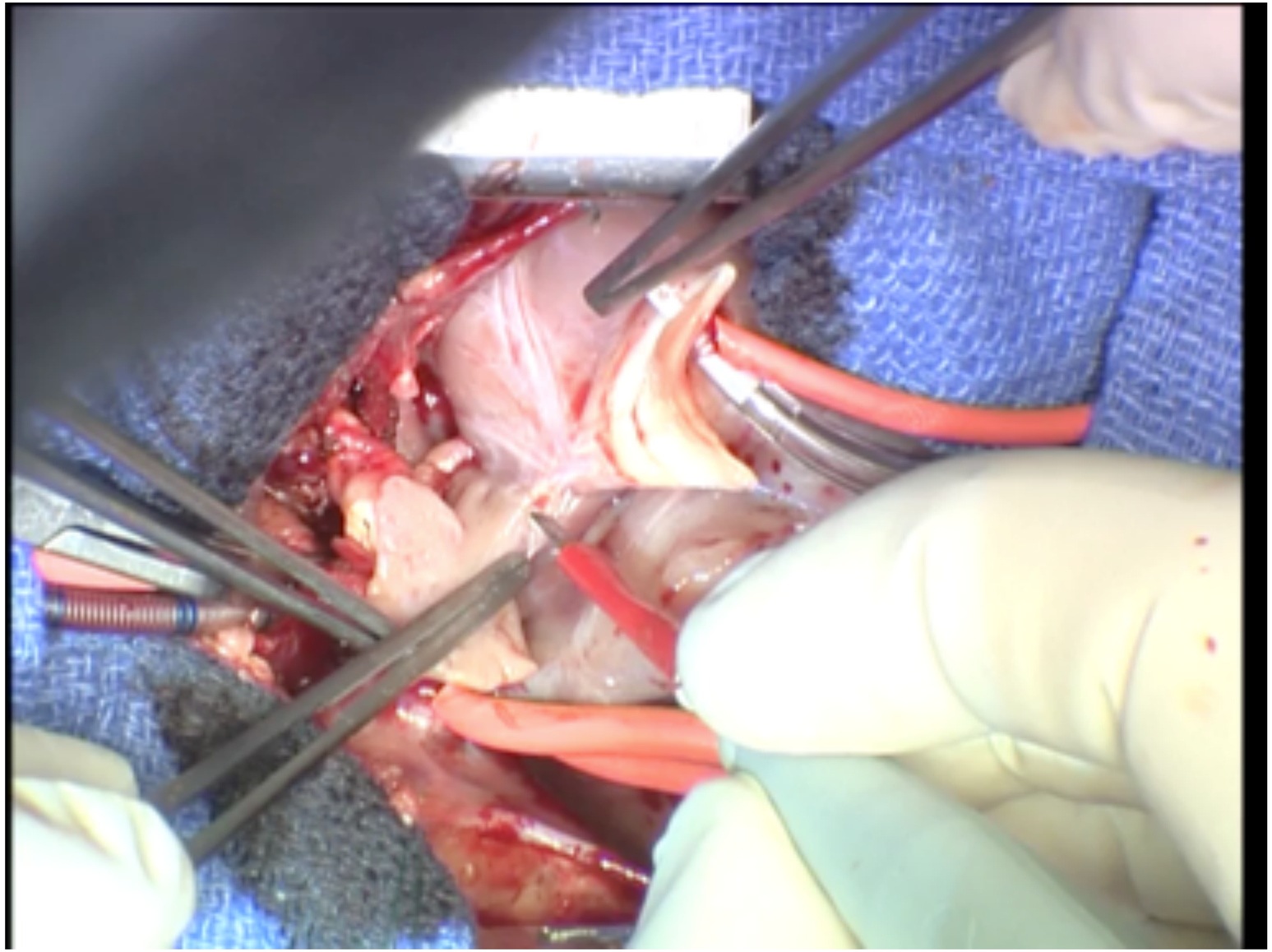

Notre stratégie

APSO type 2

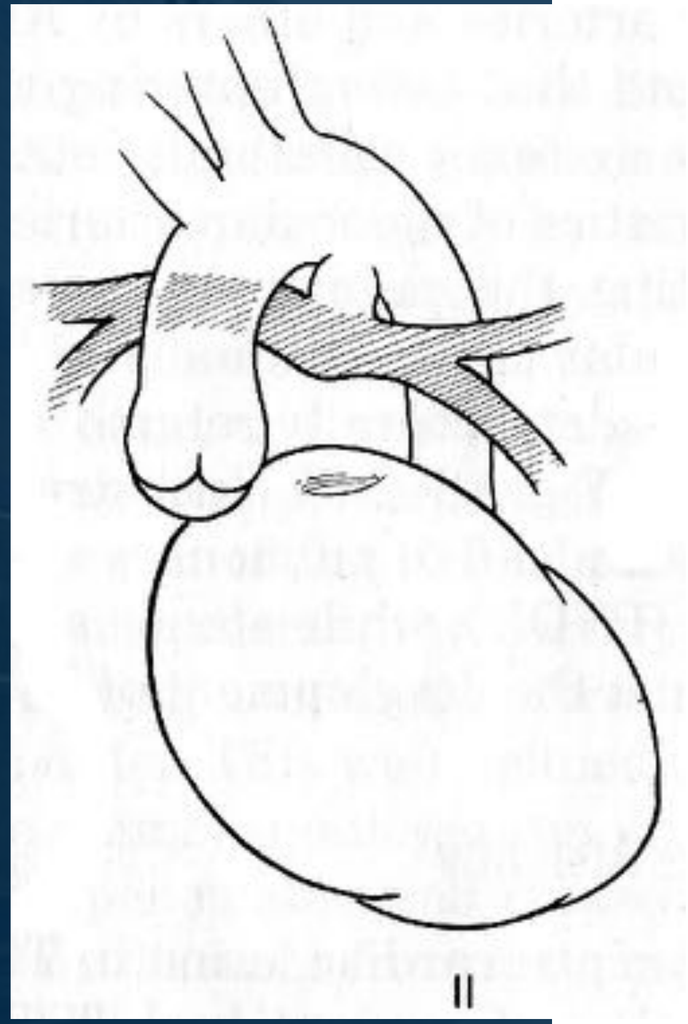

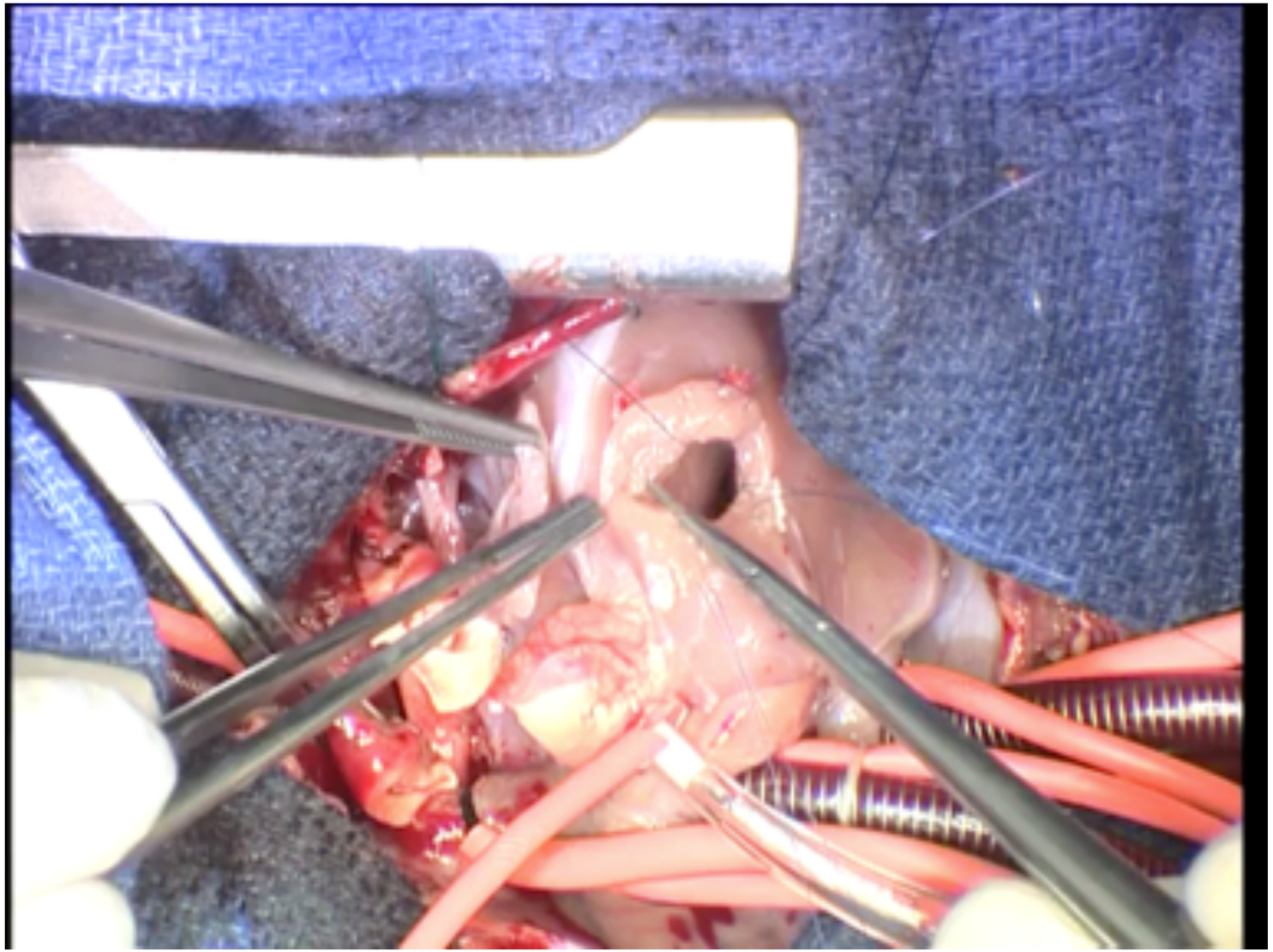



APSO type III / IV

Notre stratégie

Présentation clinique

Cyanose à la fermeture du canal ou avant 3 mois+ petites AP

Ouverture VD-AP sans unifocalisation

Notre stratégie

Présentation clinique

Cyanose à la fermeture du canal ou avant 3 mois+ petites AP

Ouverture VD-AP sans unifocalisation

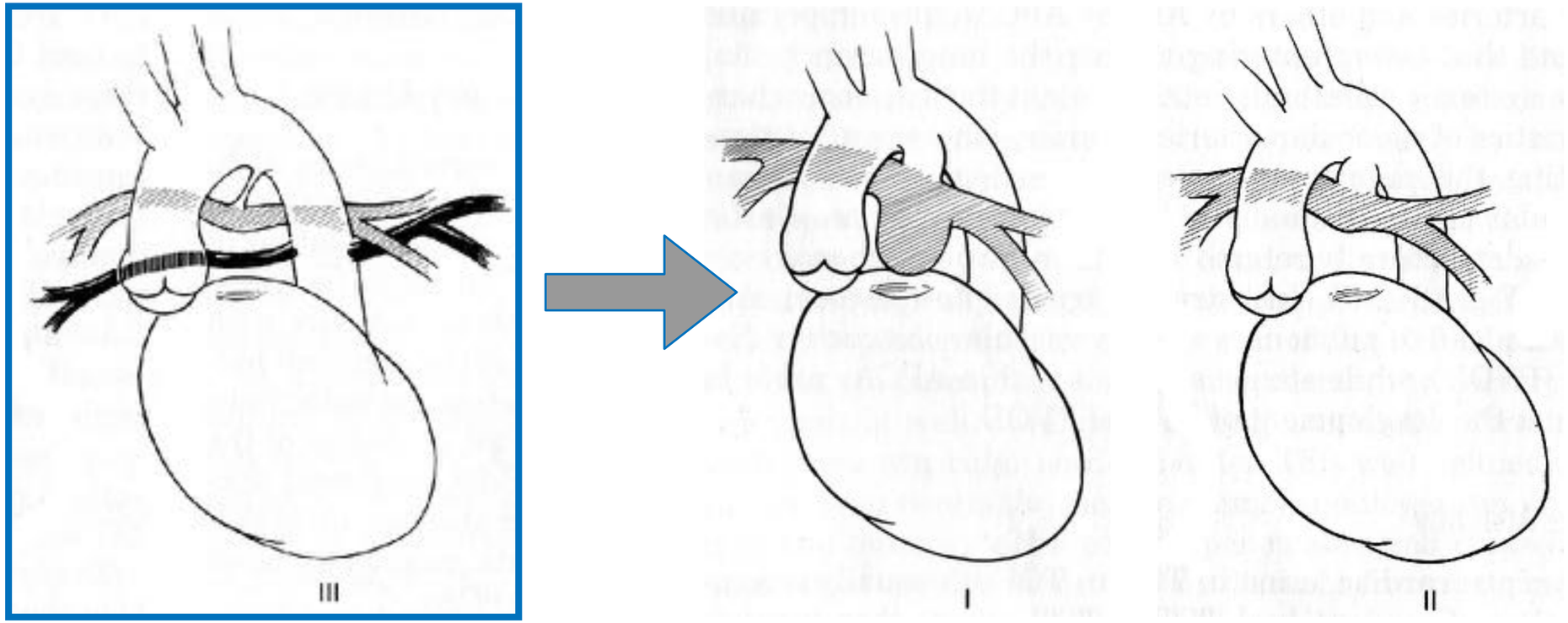

Notre stratégie

De 2000 to 2014, 109 pts Ouverture VD-AP comme première palliation

2.7% mortalité hospitalière

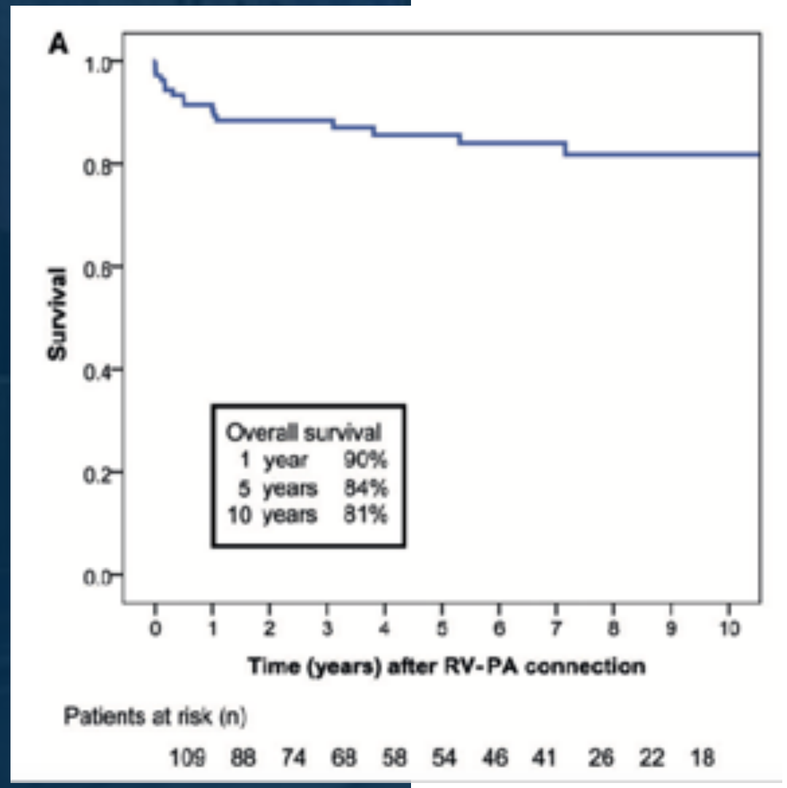

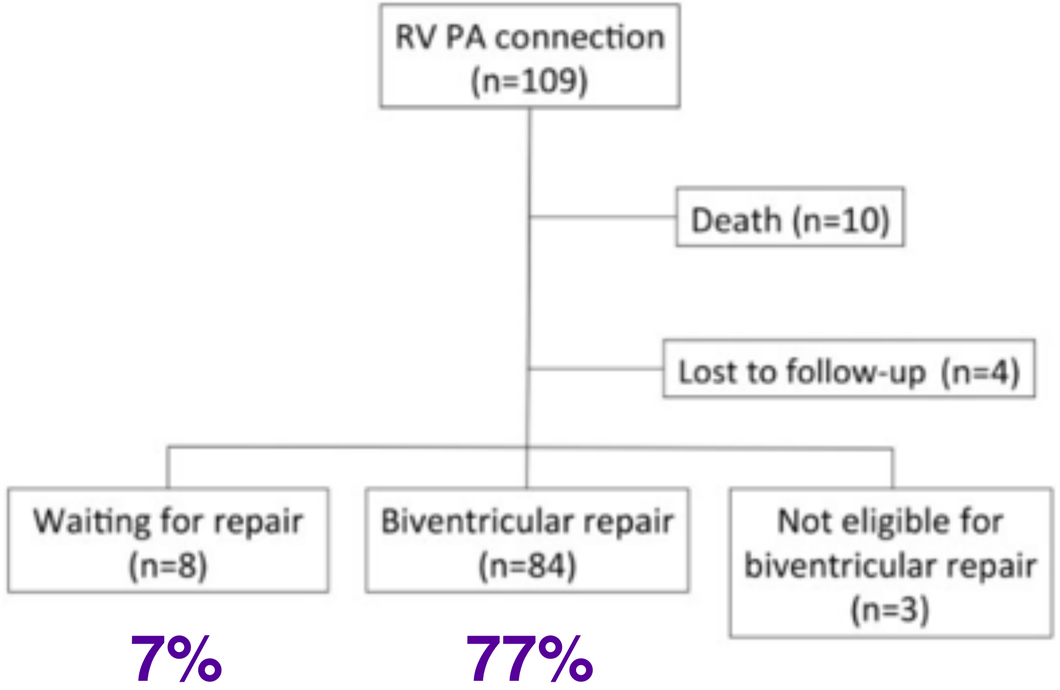

Notre stratégie

Bonne croissance des AP

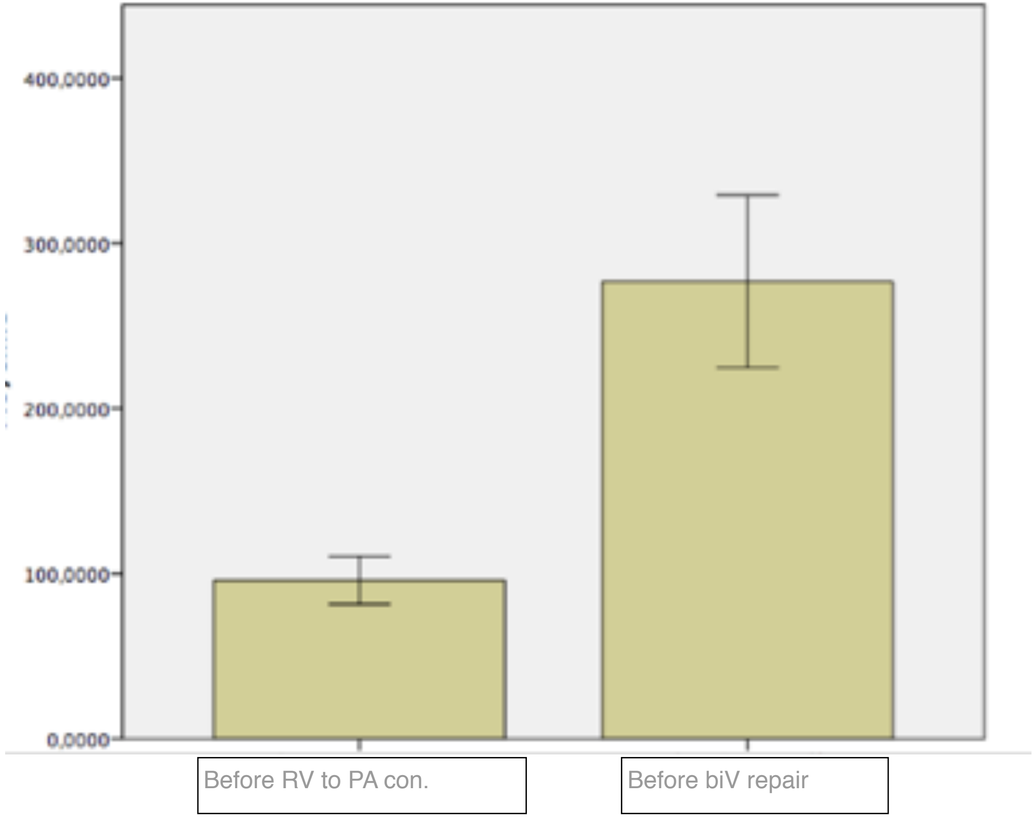

Index de Nakata passe de 101 à 274 au cours du suivi

Notre stratégie

Pas de cyanose à la fermeture du canal, débit pulmonaire équilibré ou élevé

Unifocalisation complète à 4 mois par sternotomie



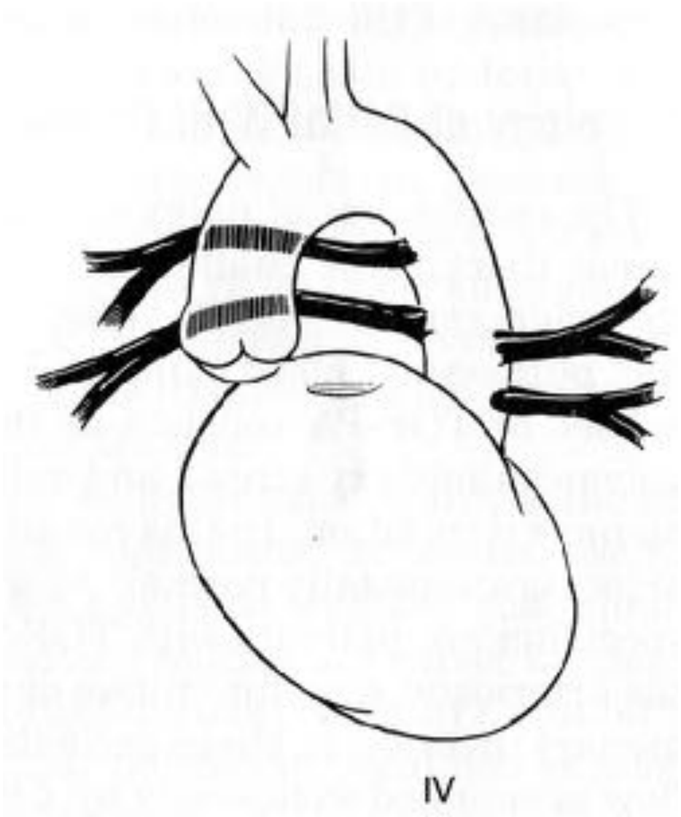

Notre stratégie

Pas de cyanose à la fermeture du canal, débit pulmonaire équilibré ou élevé

OU pas de prise en charge chirurgicale !!!!

Pb: ils ne meurent pas…

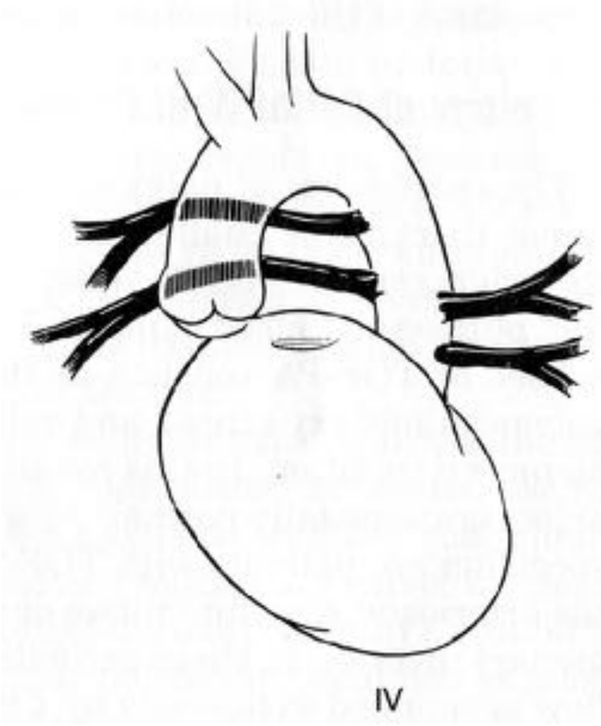

Notre stratégie

Pas de cyanose à la fermeture du canal, débit pulmonaire équilibré ou élevé

Unifocalisation complète à 4 mois par sternotomie

Arbre pulmonaire petit
/
Anatomie non favorable à l'ouverture VD-AP

↓

Blalock modifié

Bel arbre pulmonaire
/
Anatomie favorable à l'ouverture VD-AP

↓

Ouverture VD-AP

Notre stratégie

4 mois. APSO petites AP and MAPCAS essentiellement communicantes

Unifocalisation et ouverture VD-AP avec l’auricule gauche

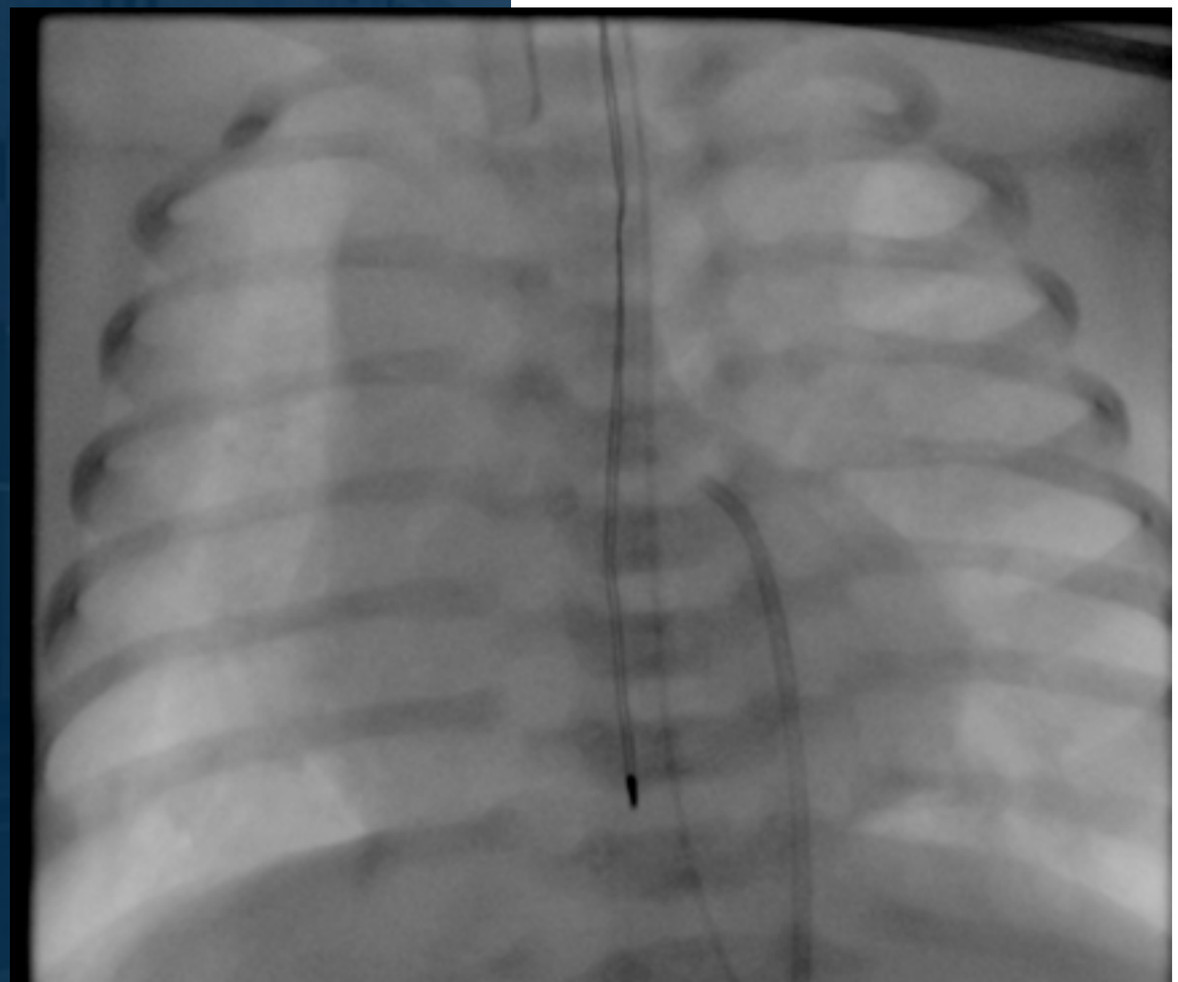

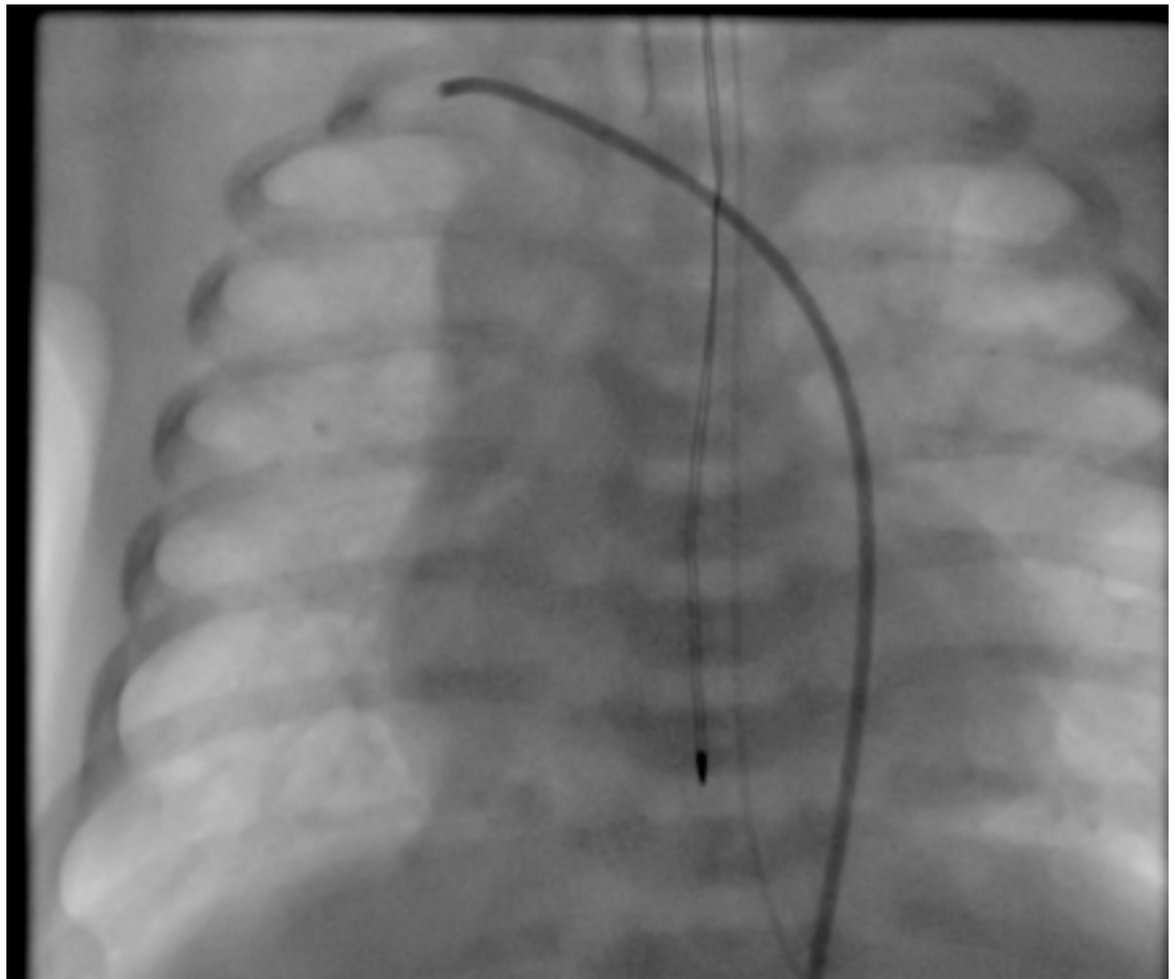

Notre stratégie

1O mois

Cure complète sans tube ni valve + plastie de la bifurcation

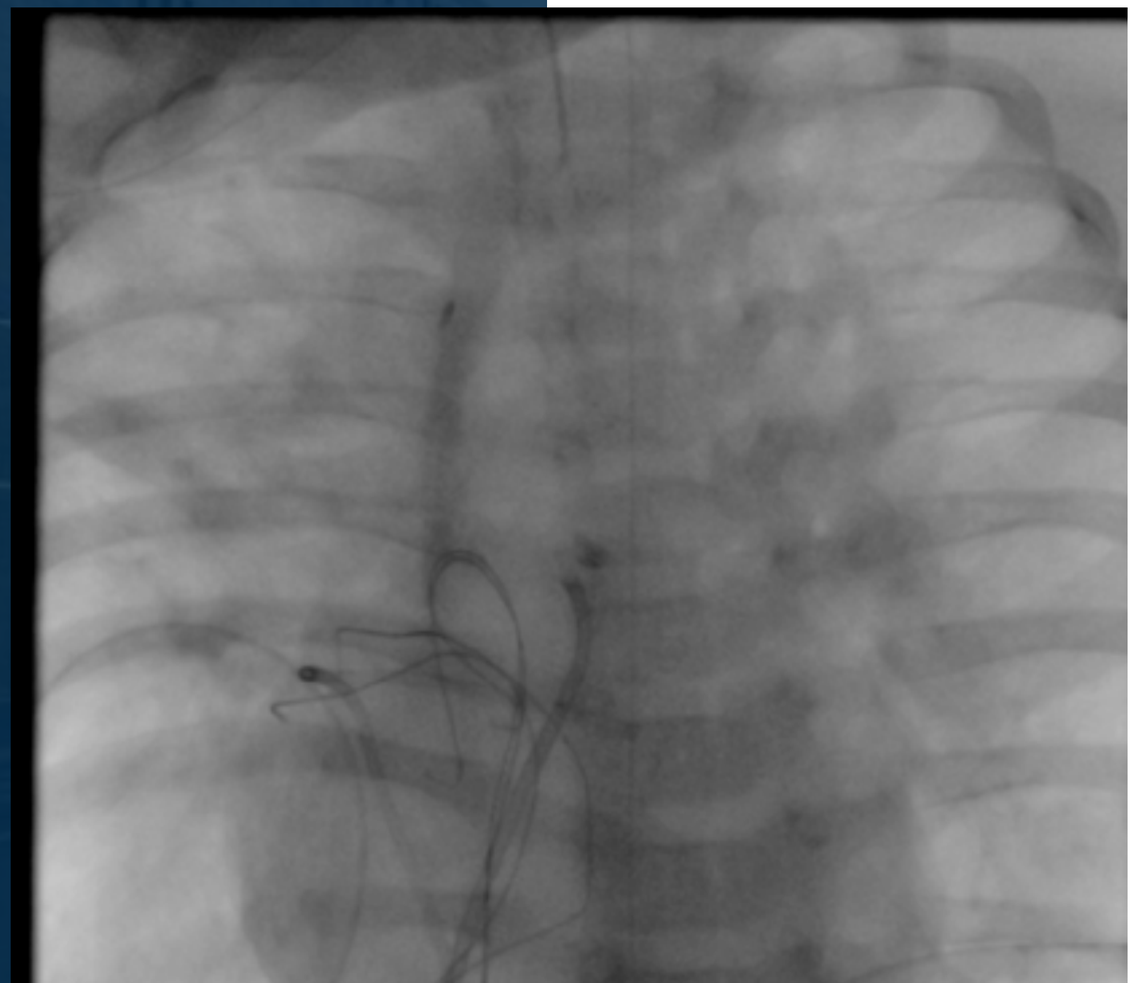

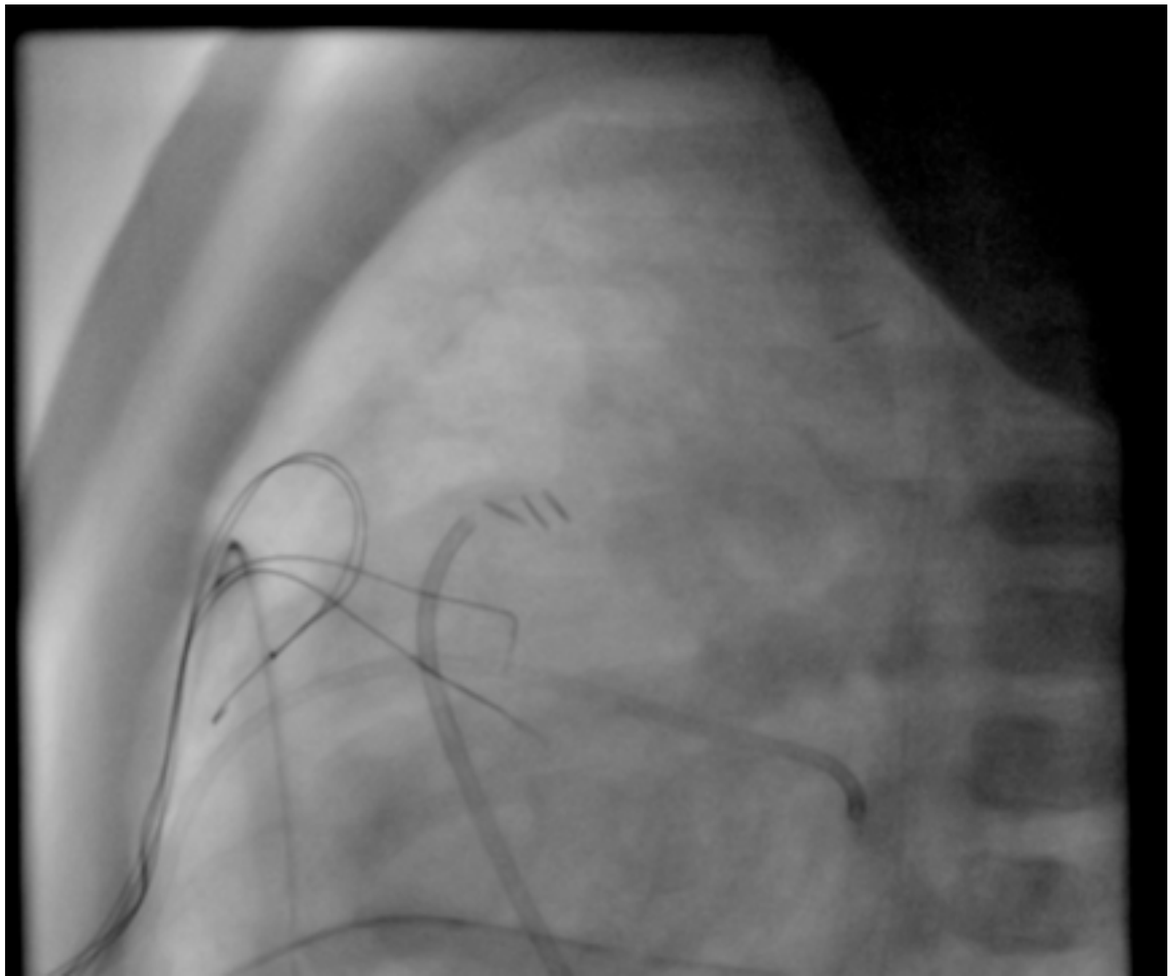

Notre stratégie

6 mois, 5.5 kg
APSO
Arche aortique droite
AP native 1.5mm , 2 MAPCAs de chaque coté

Unifocalisation complète + plastie au péricarde autologue + blalock modifié

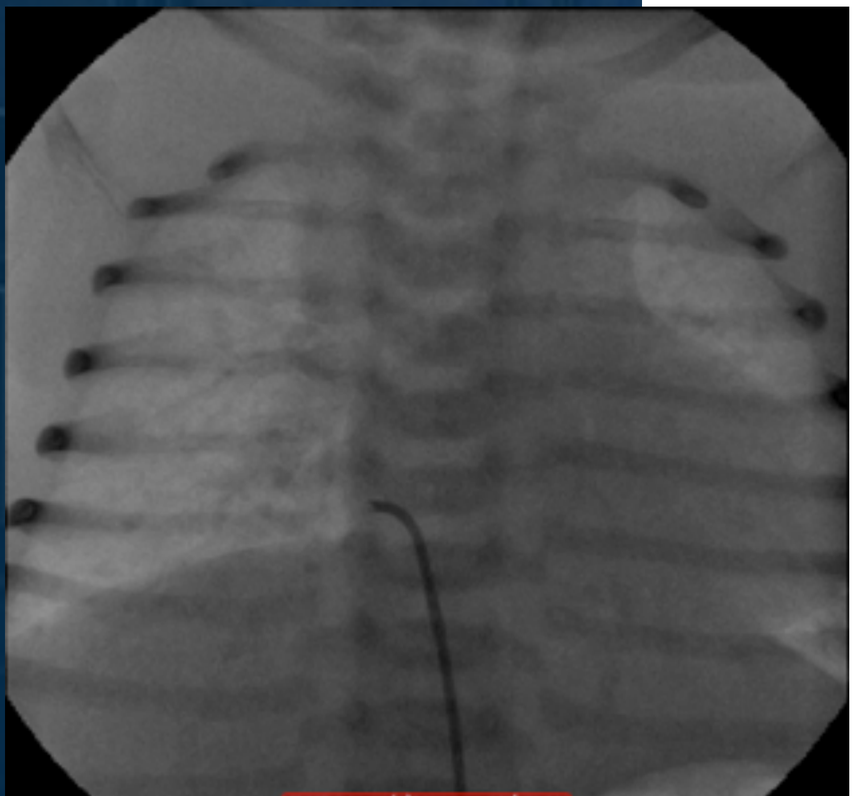

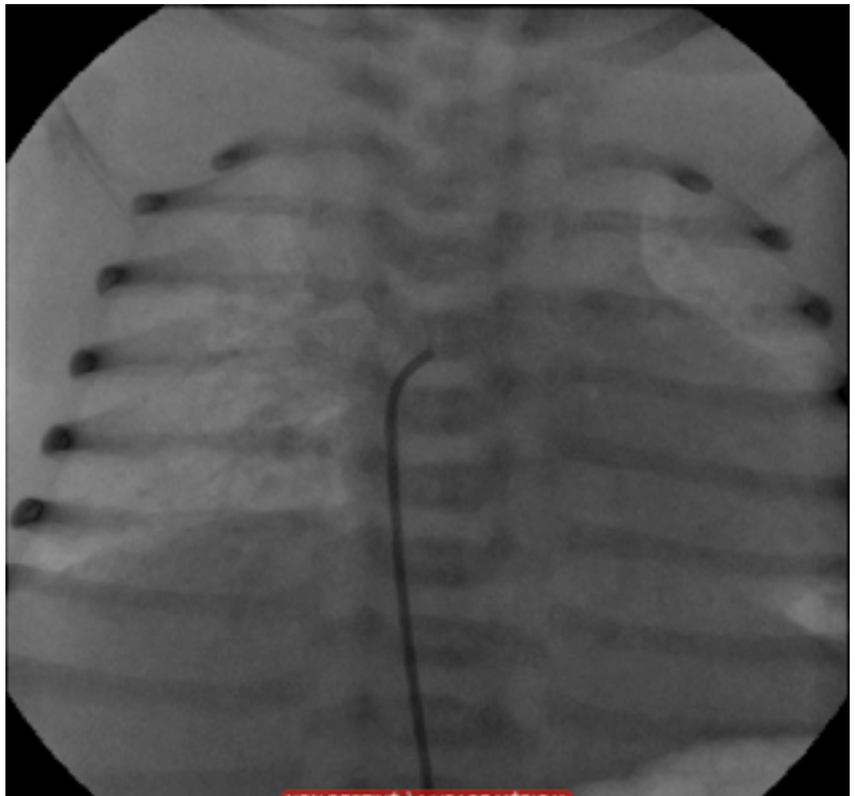

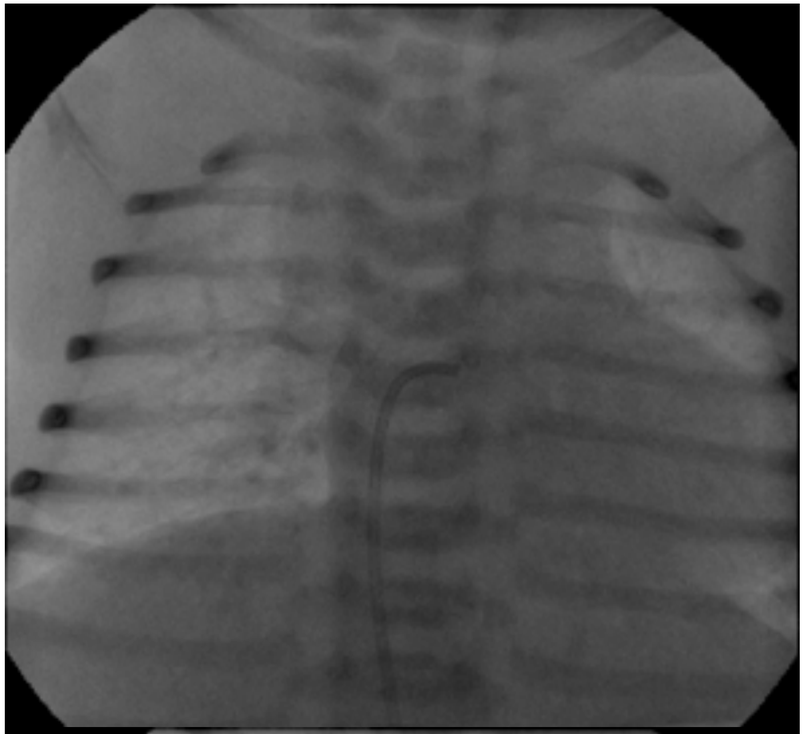

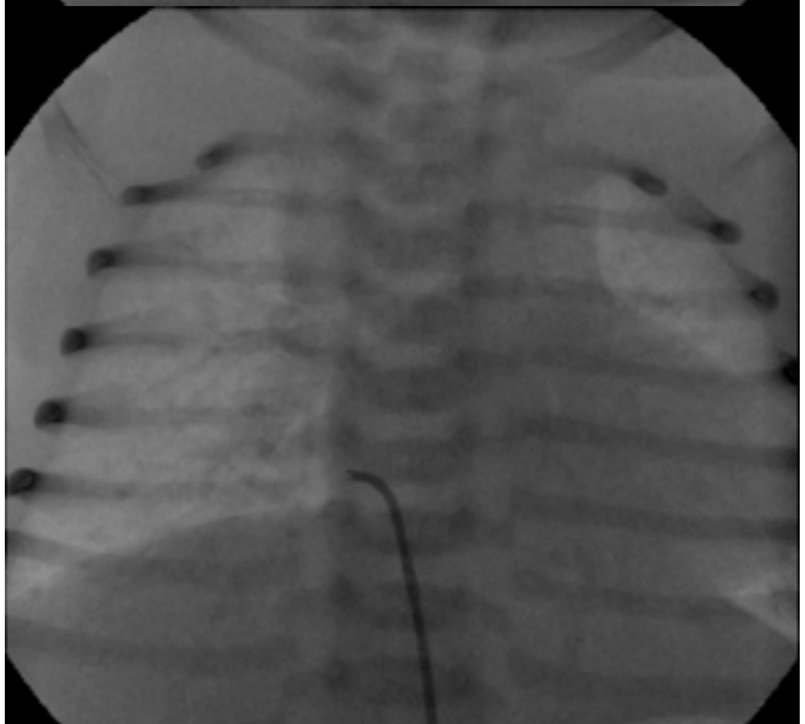

Notre stratégie

3 ans (blalock gauche entre temps)
AP petites mais bel arbre pulmonaire

Translocation anterieure de l'APG (retrooesophagienne)
Plastie de la bifurcation (MATRIX patch)
CONTEGRA 14mm
Fermeture de la CIV

PVD 40mmHg VD / LVG less than 0.5

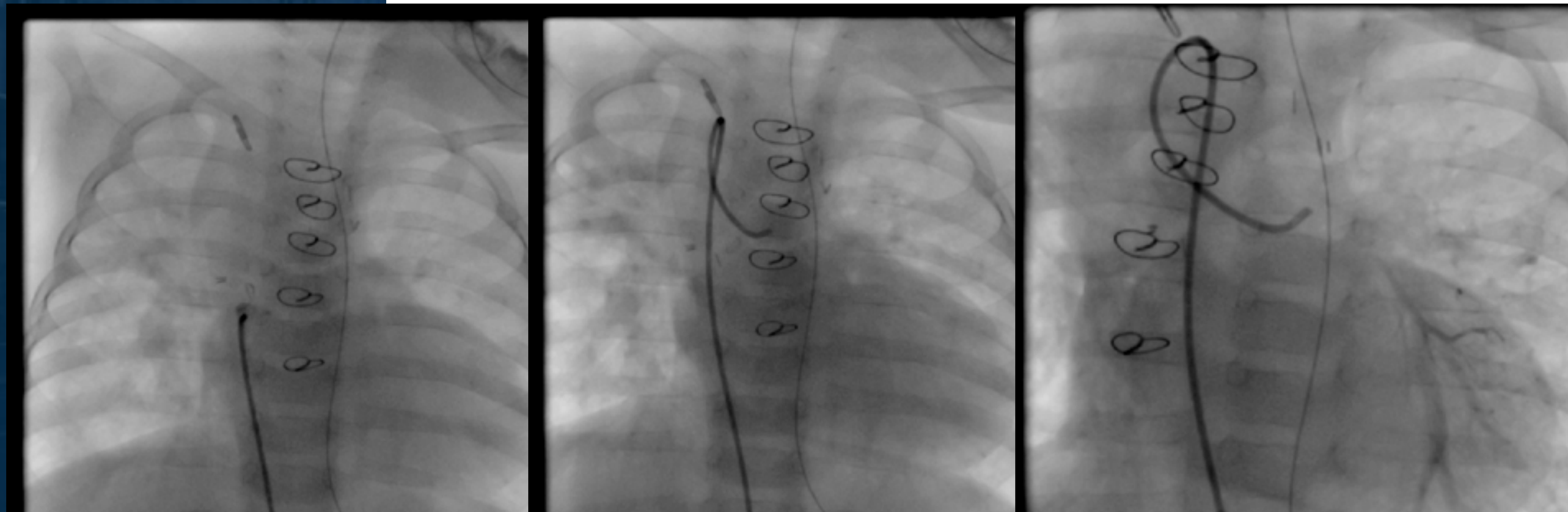

Notre stratégie

4 ans, Sténose progressive de l’APG

Plastie de la bifurcation, homogreffe pulmonaire 16mm and rallongement de l’aorta 22mm

PVD 30mmHg au dernier suivi

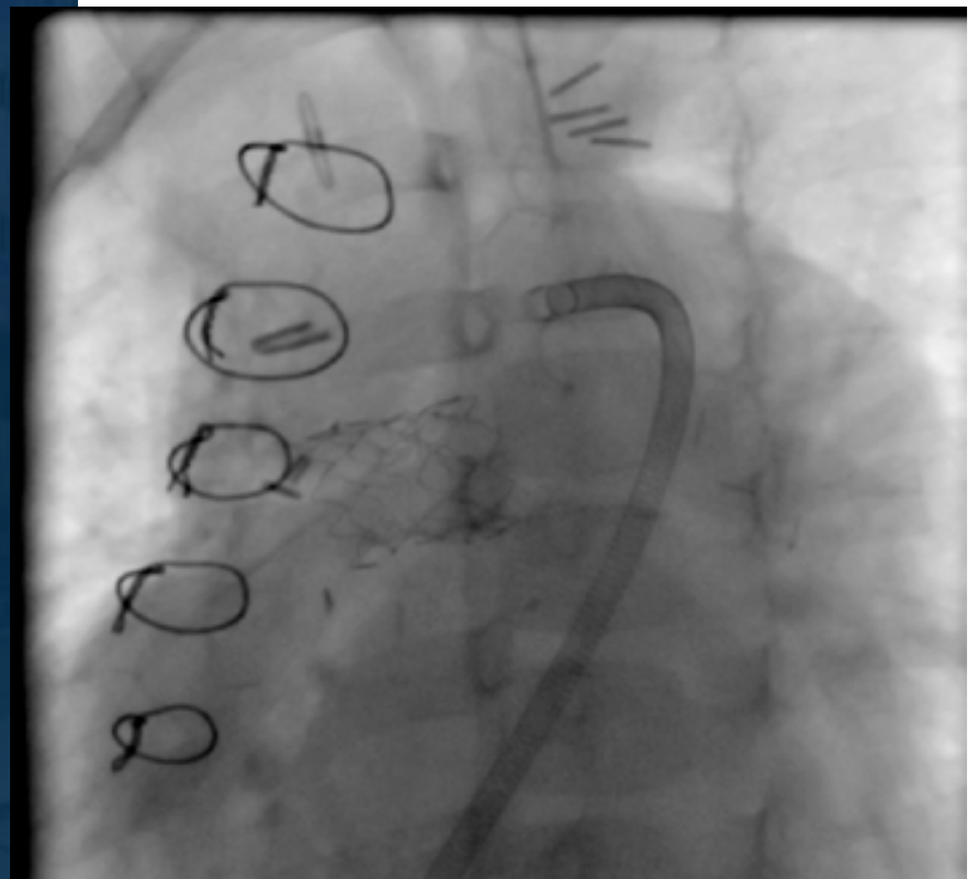

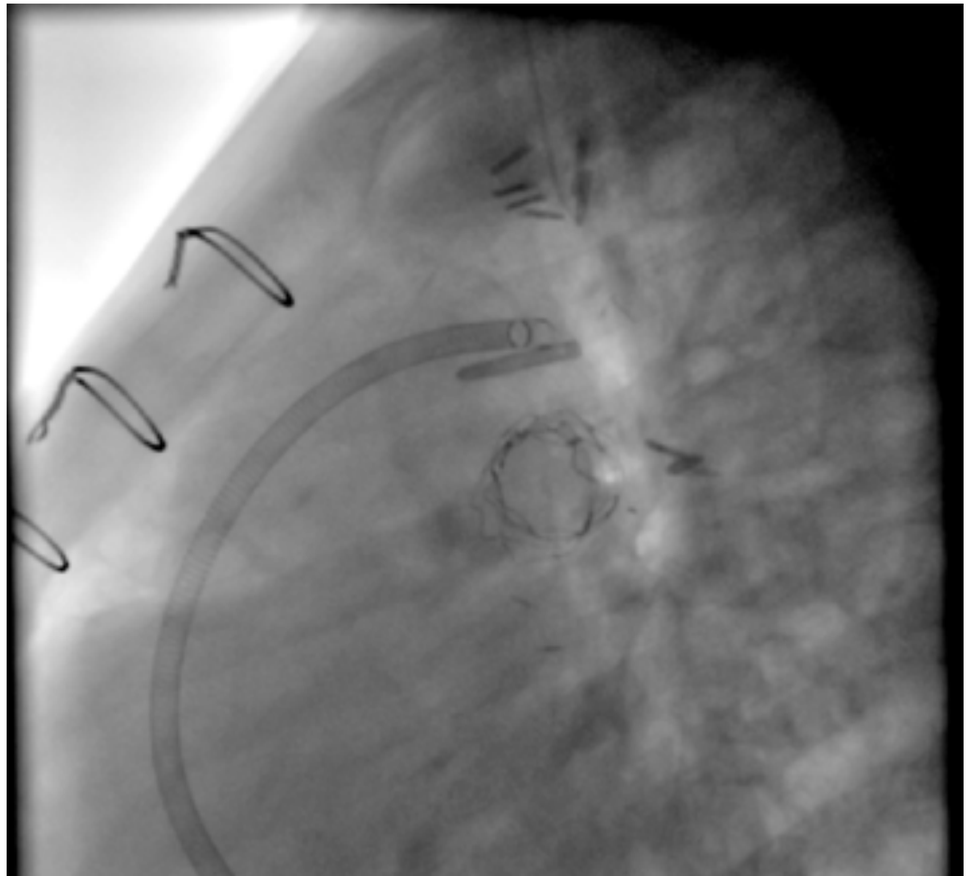

Aspects Techniques

Unifocalisation complète

Dissection off pump et contrôle de toutes les MAPCAS

Reconstruction autologue

Aspects Techniques

Unifocalisation complète

Dissection off pump et contrôle de toutes les MAPCAS

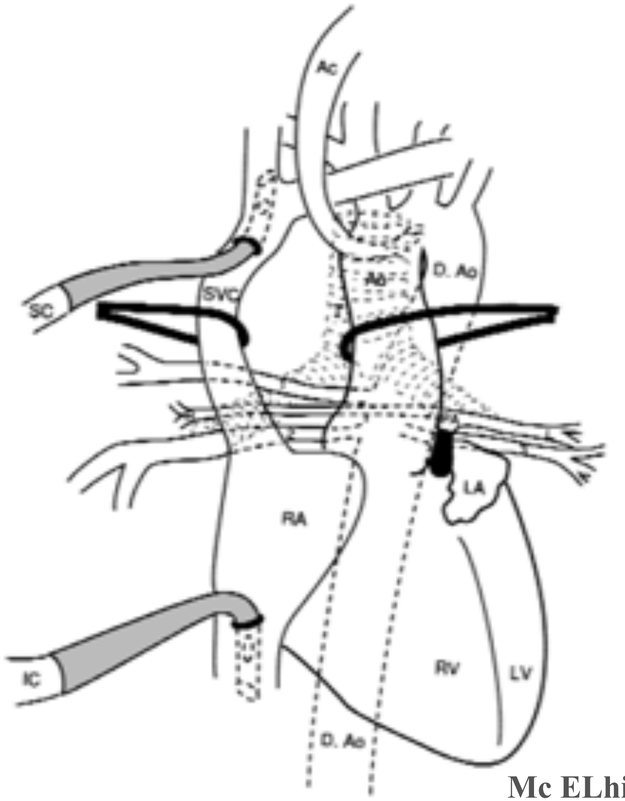

Mc ELhinney

planning pré-opératoire+++

Angiographie

CT scan

Dessins

Aspects Techniques

Unifocalisation complète

Dissection off pump et contrôle de toutes les MAPCAS

Exposure **…and a dynamic assistant**

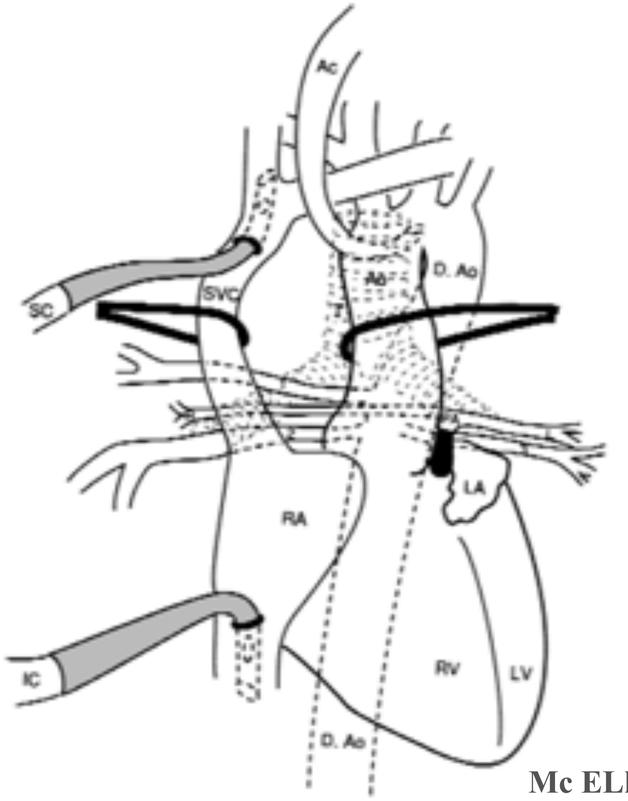

Mc ELhinney

Stiches on the aorta

Stiches on the SVC

purse string on the right appendage

Vessel loop on the right PA

Opening of the Theile and Haller recessuses

Dissection of the bronchus and inter trachea-bronchial space

Aspects Techniques

Unifocalisation complète

Dissection off pump et contrôle de toutes les MAPCAS

Exposure …and a dynamic assistant

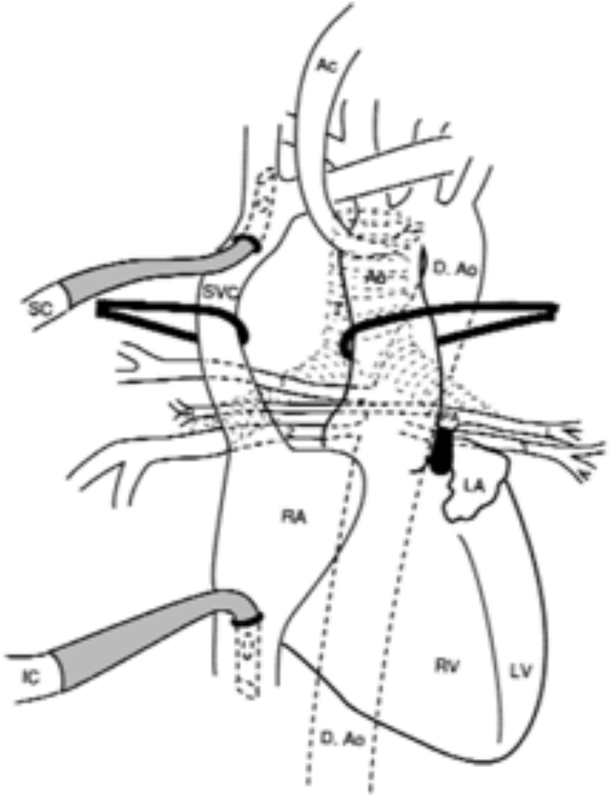

Mc ELhinney

Contrôle de toutes les MAPCAs avant le départ en CEC+++

Aspects Techniques

Unifocalisation complète

Dissection off pump et contrôle de toutes les MAPCAS

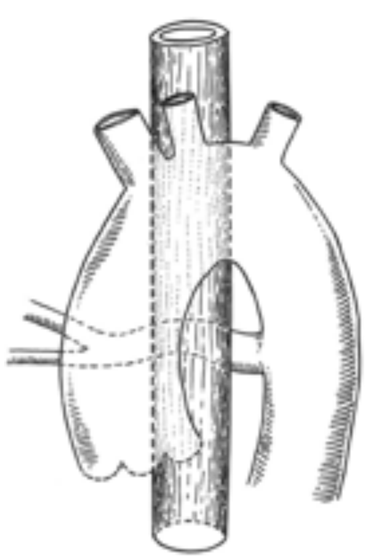

Left Aortic Arch

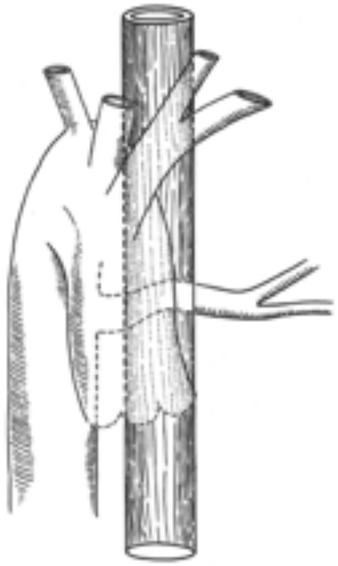

Right Aortic Arch

Retro-oesophageal MAPCAs

75% in left arch

53% in right arch

More intra oesophageal when right sided arch

More stenosis when intra-oesophgeal course

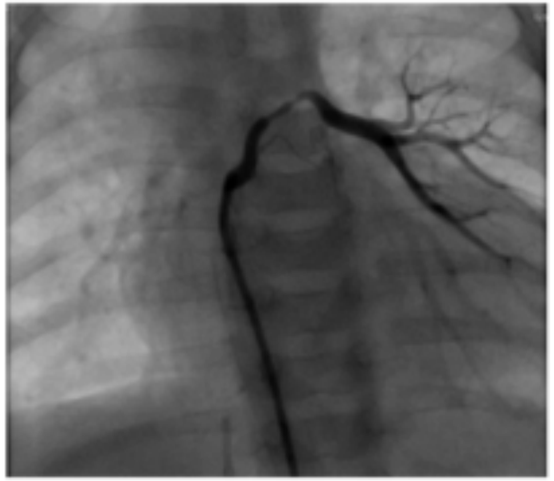

Aspects Techniques

Unifocalisation complète

Dissection off pump et contrôle de toutes les MAPCAS

Exposure …and a dynamic assistant

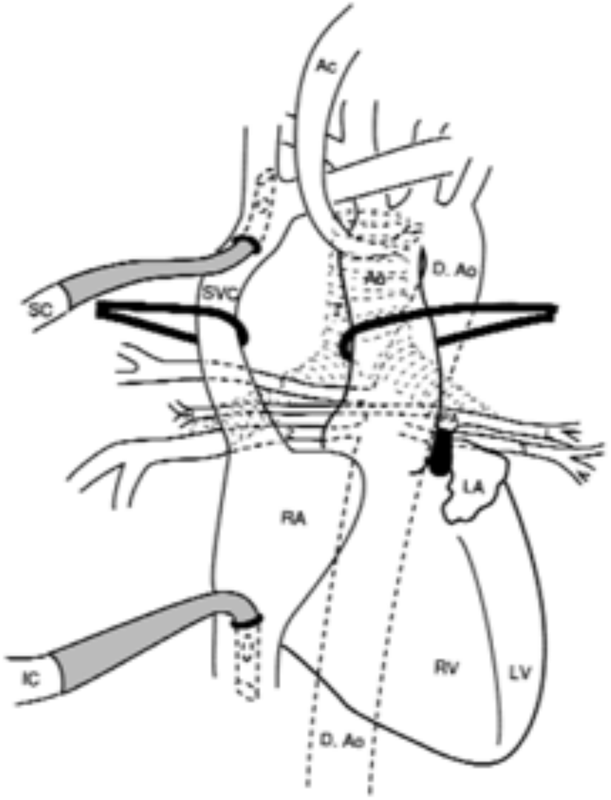

Ligature des Mapcas communicantes

Anastomose des Mapcas non-communicantes avec les AP natives

Mc ELhinney

Aspects Techniques

Unifocalisation complète

Reconstruction autologue

Taylor made surgery

AP, MAPCAs, péricarde autologue non traité

Aspects Techniques

Ouverture VD AP

Patch 54% 61%

Tube de Goretex 42% 28%

Interposition de l’auricule 3% 11%

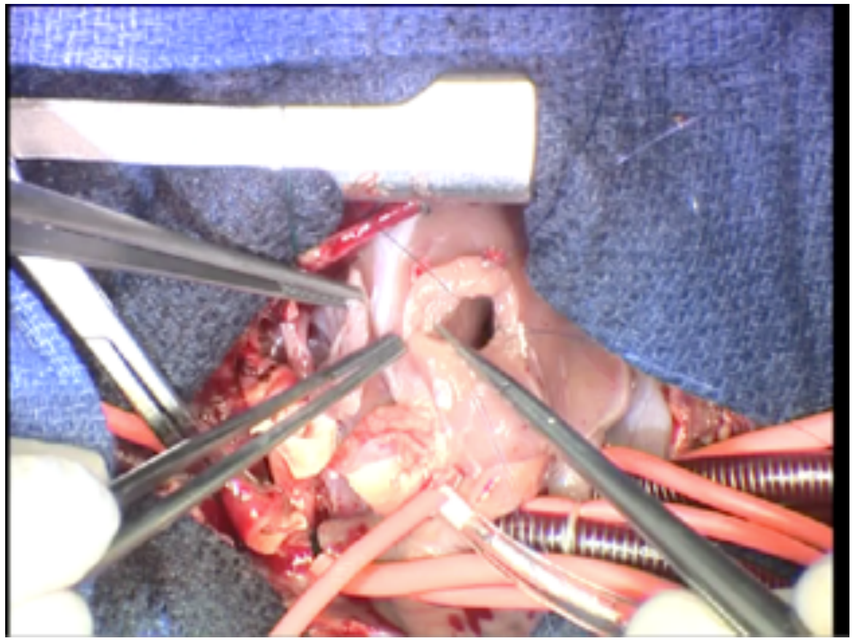

Aspects Techniques

Ouverture VD AP

Patch 54%

Tube de Goretex 42%

Interposition de l'auricule 3%

Large connection
La calibration depend de l'âge (5 à 6mm NN)

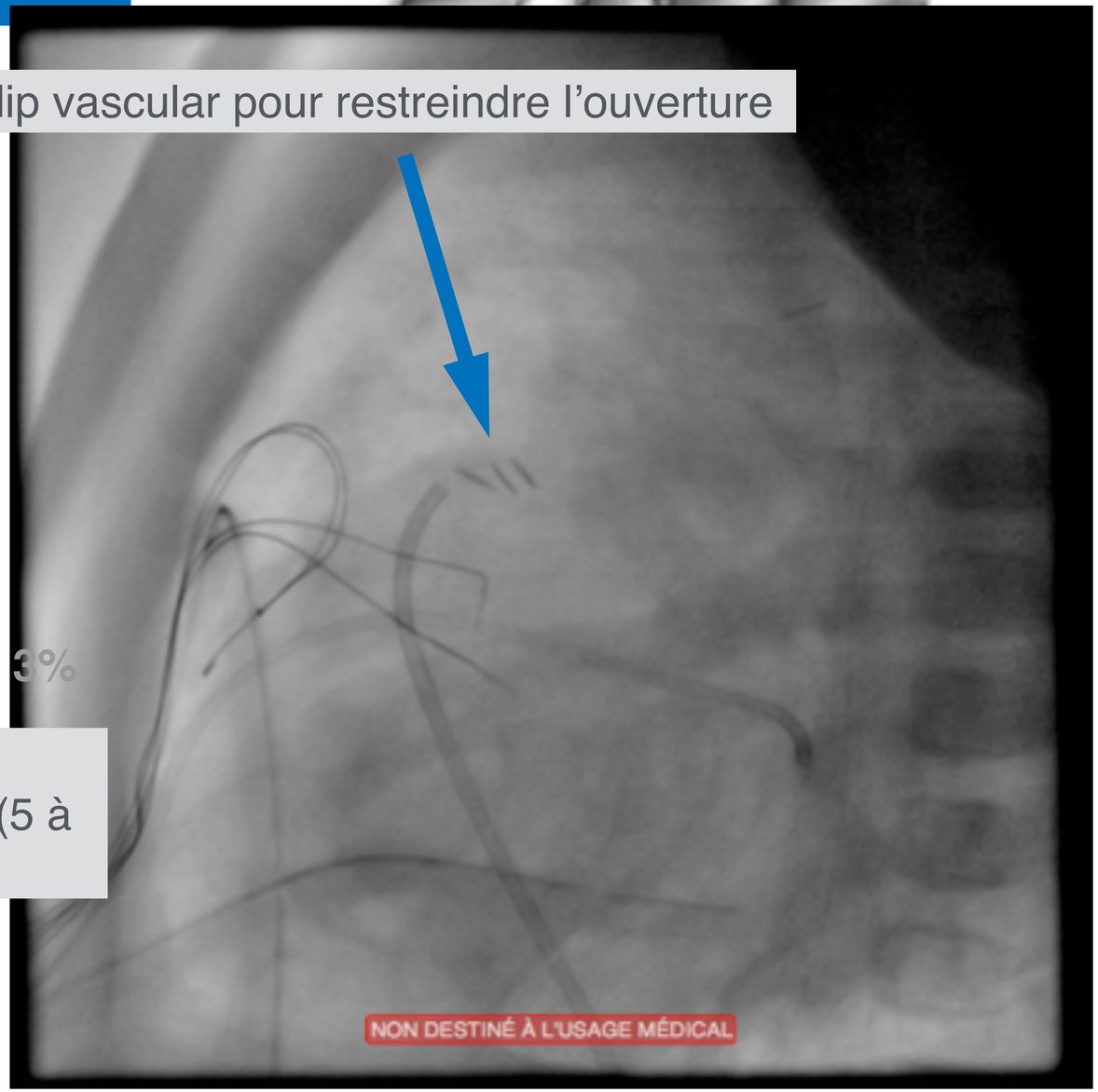

Résultats

PA with VSD and MAPCAs

35pts had a RV to PA connection as a first palliation

34% had complete unifocalisation

1 patient died

Patients who had a blalock as a first palliation were excluded

Characteristics	PA/VSD Type III (*n* = 35)	Total (*n* = 109)	*P*-value
Surgical procedure			
Patch enlargement	19 (54)	66 (61%)	0.1
PTFE conduit	15 (42)	31 (28%)	0.06
Interposition left appendage	1 (3)	12 (11%)	0.023
Mean open size (mm)	5.9 (1.1)	5.4 (1.1)	0.002
Unifocalization	12 (34)	12 (11)	<0.001
Confluence PA plasty	8 (22)	26 (23)	0.53
LPA plasty	6 (17)	22 (20)	0.86
RPA plasty	7 (20)	15 (13)	0.079
CPB duration (min)	96 (56)	85 (43)	0.06
Cross-clamping duration (min)	29 (18)	33 (18)	0.05
Postoperative characteristics			
Delayed sternal closure (days)	5 (14)	23 (21%)	0.41
Mean oxygen saturation after surgery, %	88 (11)	90 (8)	0.29
Mechanical ventilation (h)	91 (84)	86 (102)	0.84
Length of ICU stay (h)	156 (113)	158 (142)	0.5
HFO	3 (8)	9 (8)	0.41

Résultats

15 reoperations before complete repair

1 early reoperation before 2 months for a restrictive connection

Characteristics	PA/VSD Type III (n = 35)	Total (n = 109)	P-value
In-hospital deaths	1 (3%)	3 (2.8%)	1
Ventricular aneurysm	5 (14%)	8 (7%)	0.18
Excessive pulmonary blood flow	1 (2.9%)	1 (1%)	0.34
Restrictive pulmonary blood flow before 2 months	1 (3%)	9 (8%)	0.14
BT shunt	0	7 (6.4%)	
Enlargement of RVPA connection	1	2 (2%)	
Unifocalization	0	0	
Pulmonary artery plasty	0	1 (1%)	
Angioplasty	0	0	
Restrictive pulmonary blood flow between 2 months and biventricular repair	15 (42%)	20 (18%)	<0.001
BT shunt	3	5	
Enlargement of RVPA connection	4	5	
Unifocalization	4	4	
Pulmonary artery plasty	1	1	
Angioplasty	3	5	
BT shunt + unifocalization	2	2	
Enlargement of RVPA connection + unifocalization	1	1	
Enlargement of RVPA connection + pulmonary artery plasty	1	1	
Pericardial drainage	3 (8.5%)	4 (4%)	0.10
Phrenic paralysis	1 (3%)	2 (2%)	0.64

Résultats

Over the 34 survivors

20 had complete repair

No operative mortality

2 pts died

10 are waiting for repair

2 are unsuitable for repair

Characteristics	PA/VSD type III (n = 20)	Total (n = 84)	P-value
Mean weight (kg)	13.44 (10)	8.85 (6.2)	0.002
Mean age (months)	43.4 (42.5)	20.43 (29.4)	<0.001
Time between the RVPA connection and biventricular repair (months)	25.7 (21)	14.67 (17)	0.002
Mean Nakata index before biventricular repair (mm^2/m^2)	257 (130)	266 (186)	0.26
Surgical procedure			
Patch enlargement	4 (20%)	47 (56%)	<0.001
Prosthetic conduit valve	12 (60%)	28 (33%)	<0.001
Prosthetic conduit, no valve	1 (5%)	2 (2%)	0.54
Patch enlargement with monocuspid valve	3 (15%)	7 (8%)	0.46
RPA plasty	2 (10%)	25 (30%)	0.03
LPA plasty	8 (40%)	44 (52%)	0.31
CPB duration (min)	151 (42)	144 (41)	0.44
Cross-clamping duration (min)	80 (30)	83 (27)	0.75
Right ventricular pressure superior at 40 mmHg	10 (50%)	22 (26%)	0.02

Résultats

Over the 34 survivors

20 had complete repair → No operative mortality

2 pts died

10 are waiting for repair

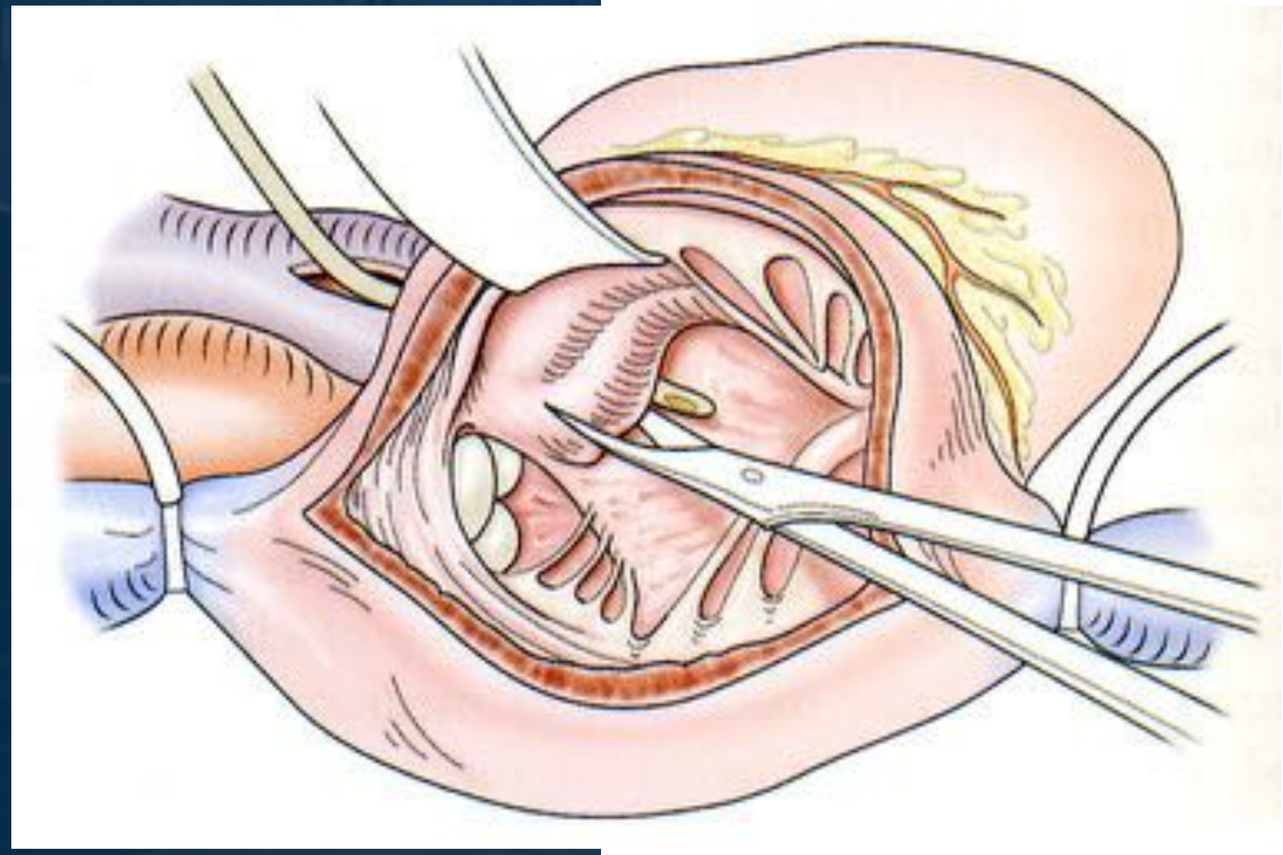

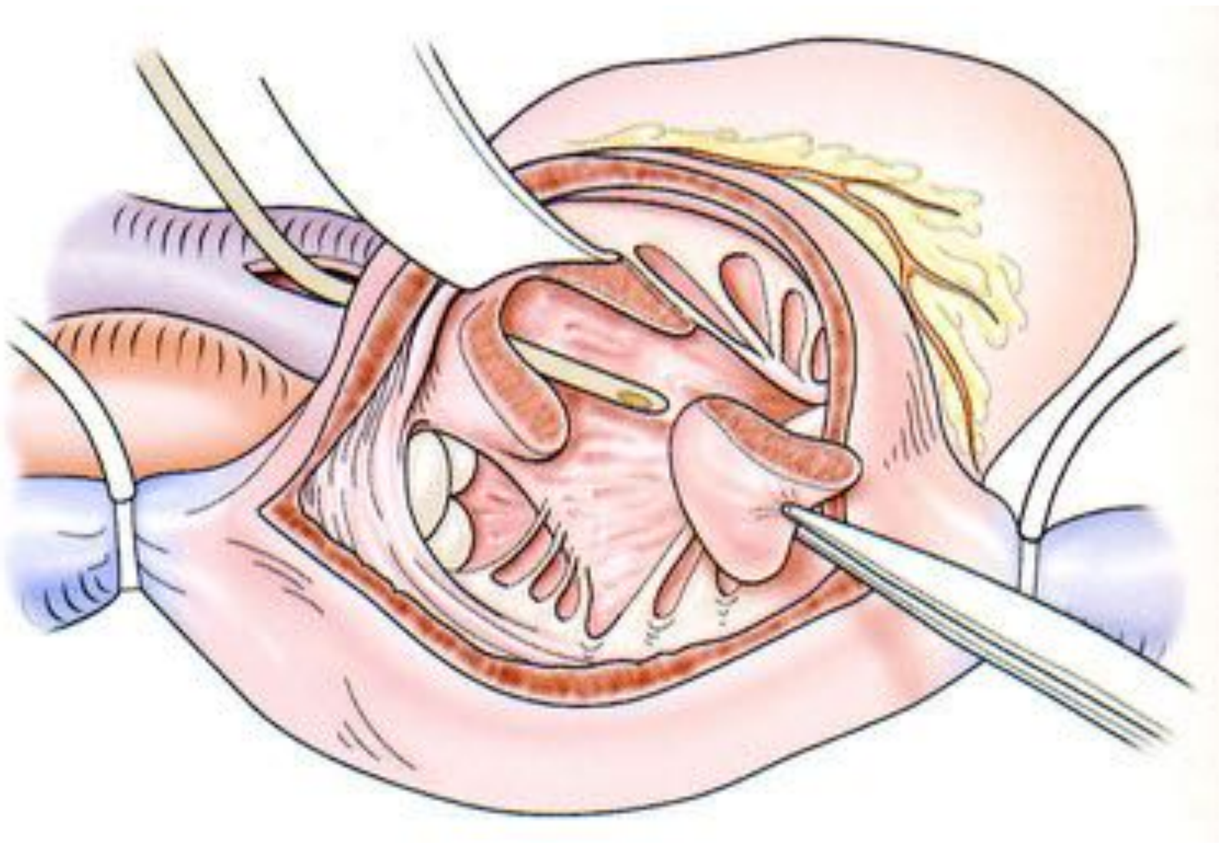

Résultats

Over the 34 survivors

20 had complete repair → No operative mortality

2 pts died

10 are waiting for repair

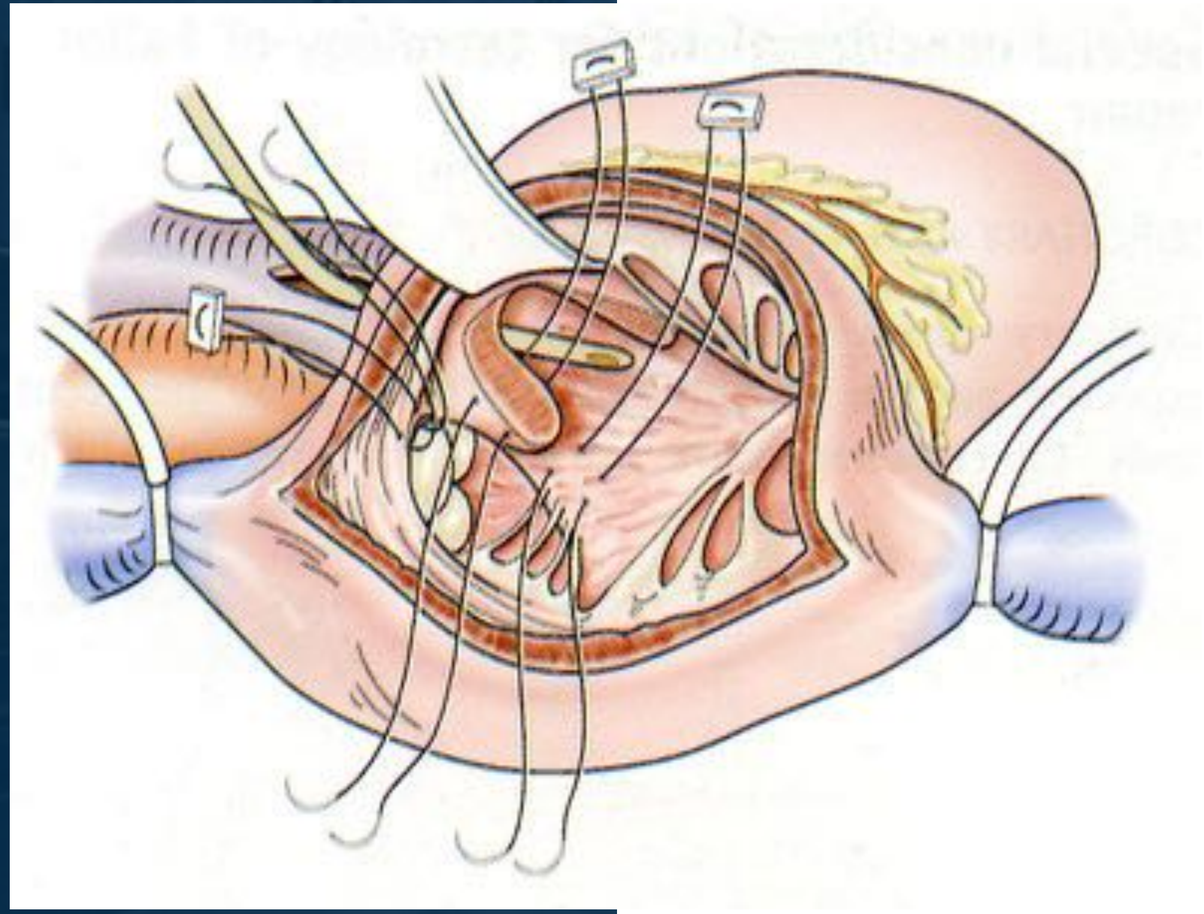

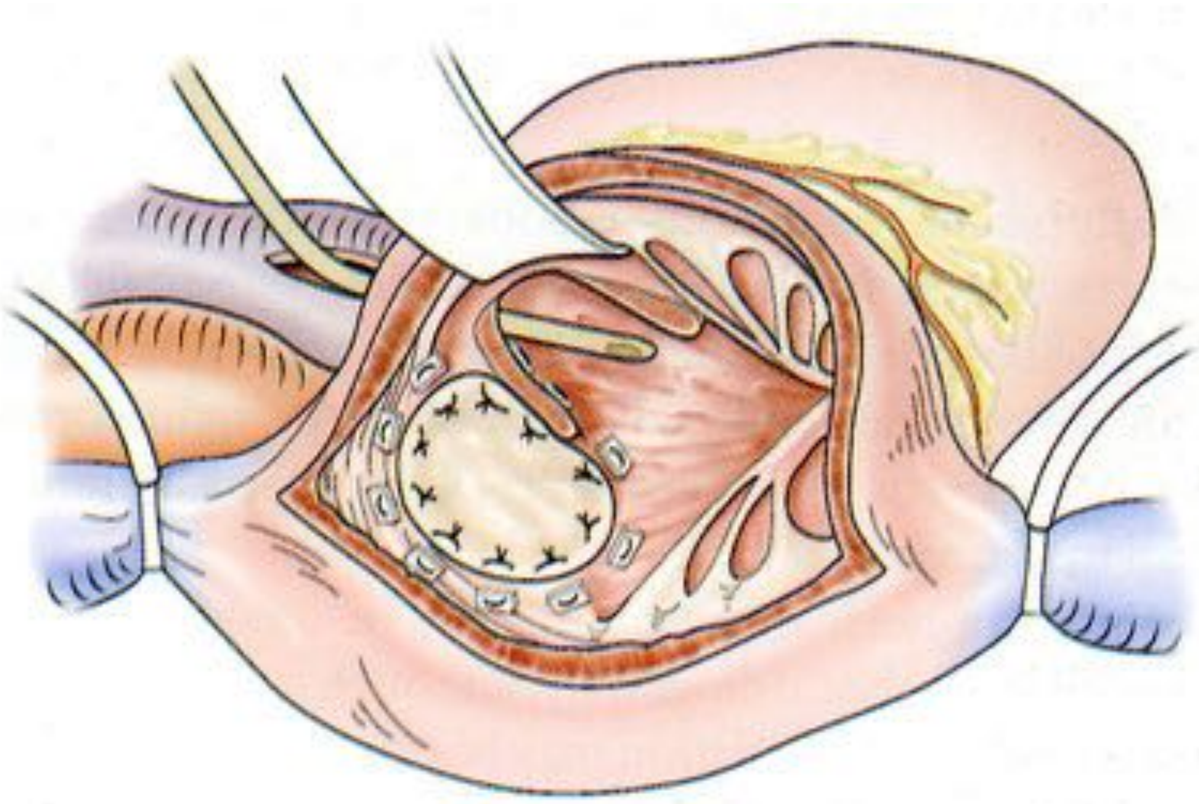

Résultats

Over the 34 survivors

20 had complete repair

No operative mortality

2 pts died

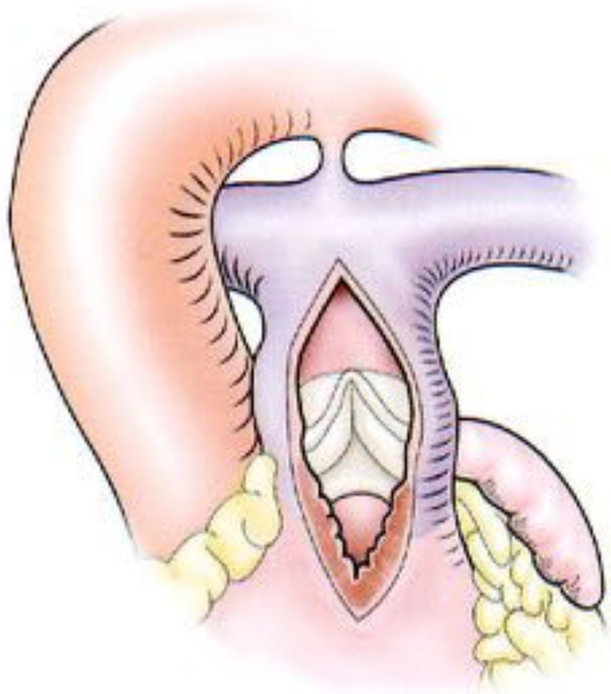

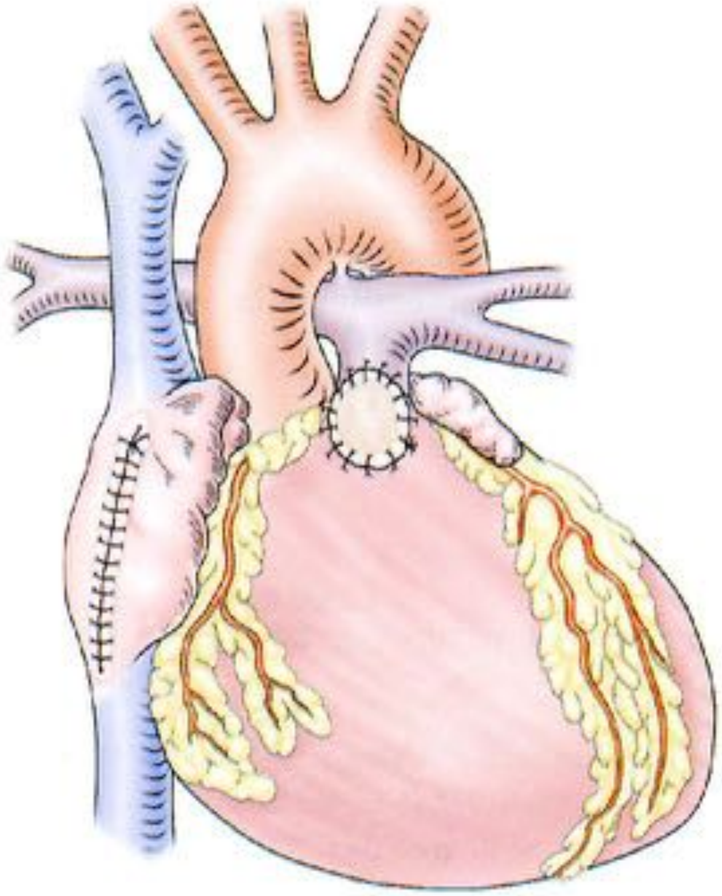

Résultats

RVOT reconstruction at the time of the repair,

No valve when possible (40% in our series)

35% no valve no tube

5% tube but no valve

60% valved tube

Characteristics	PA/VSD type III (n = 20)	Total (n = 84)	P-value
Mean weight (kg)	13.44 (10)	8.85 (6.2)	0.002
Mean age (months)	43.4 (42.5)	20.43 (29.4)	<0.001
Time between the RVPA connection and biventricular repair (months)	25.7 (21)	14.67 (17)	0.002
Mean Nakata index before biventricular repair (mm^2/m^2)	257 (130)	266 (186)	0.26
Surgical procedure			
Patch enlargement	4 (20%)	47 (56%)	<0.001
Prosthetic conduit valve	12 (60%)	28 (33%)	<0.001
Prosthetic conduit, no valve	1 (5%)	2 (2%)	0.54
Patch enlargement with monocuspid valve	3 (15%)	7 (8%)	0.46
RPA plasty	2 (10%)	25 (30%)	0.03
LPA plasty	8 (40%)	44 (52%)	0.31
CPB duration (min)	151 (42)	144 (41)	0.44
Cross-clamping duration (min)	80 (30)	83 (27)	0.75
Right ventricular pressure superior at 40 mmHg	10 (50%)	22 (26%)	0.02

5.5 year follow up

5 reinterventions

1 conduit replacement

3 dilatation + stent

1 PVI

Conclusion

présentation clinique +++

Cyanose à la fermeture du canal + très belles AP

Cure complète d'emblée

Cyanose à la fermeture du canal ou avant 3 mois+ petites AP

Ouverture VD-AP sans unifocalisation

Pas de cyanose à la fermeture du canal, débit pulmonaire équilibré ou élevé

Unifocalisation complète à 4 mois par sternotomie

Conclusion

Stratégie globale : 3 étapes

. Période néonatale

- favoriser croissance APs natives. Ouverture VD-AP

- ± supprimer MAPCAs communicantes

. À partir de 4 / 5 mois

- unifocaliser les MAPCAs non communicantes

- supprimer MAPCAs communicantes
- optimiser anatomie APs natives

. A partir de 2 ans

- cure complète au mieux sans tube

- au moins 15 segments pulmonaires

Conclusion

Stratégie globale :

La survie à long terme dépend

La capacité à obtenir une réparation biV

Du rapport de pression VD-AP

Lit vasculaire pulmonaire

Conclusion

Stratégie globale :

- Maladie grave !

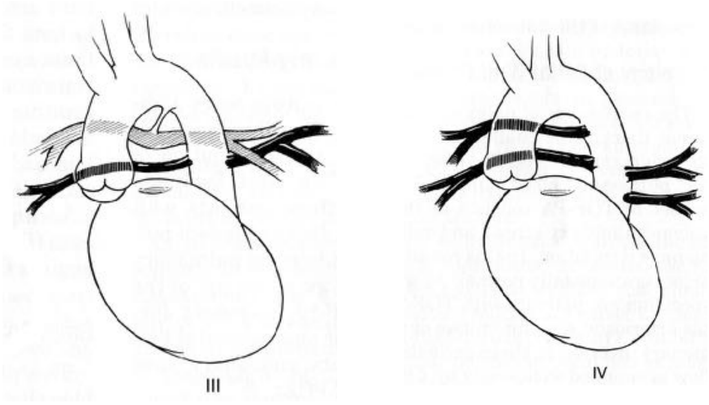

-Chirurgies et KT itératifs

Sternotomies multiples, KT multiples, ACCES VASCULAIRES+++

Arigato