Canal Atrio-Ventriculaire Complet

CAV complet

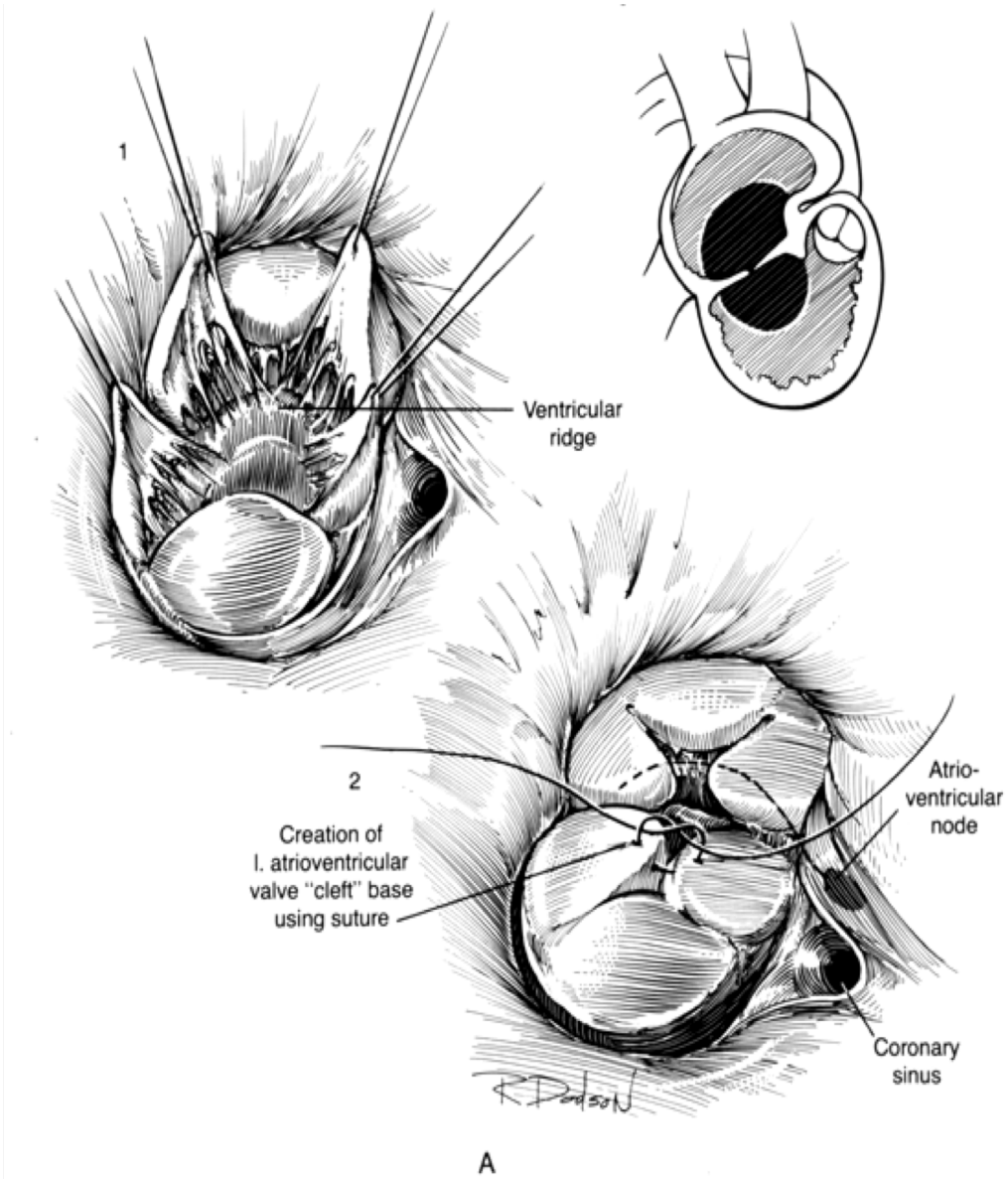
1
Ventricular ridge
2
Creation of l. atrioventricular valve "cleft" base using suture
Atrio-ventricular node
Coronary sinus
A

Indications

- ✓ cerclage pulmonaire
  - CIV multiples
  - contre-indication CEC
    (petit poids, infection …)

- ✓ correction complète sous CEC

Buts de l'intervention chirurgicale

1. fermer la CIA
2. fermer la CIV
3. éviter les voies de conduction
4. créer deux valves AV fonctionnelles

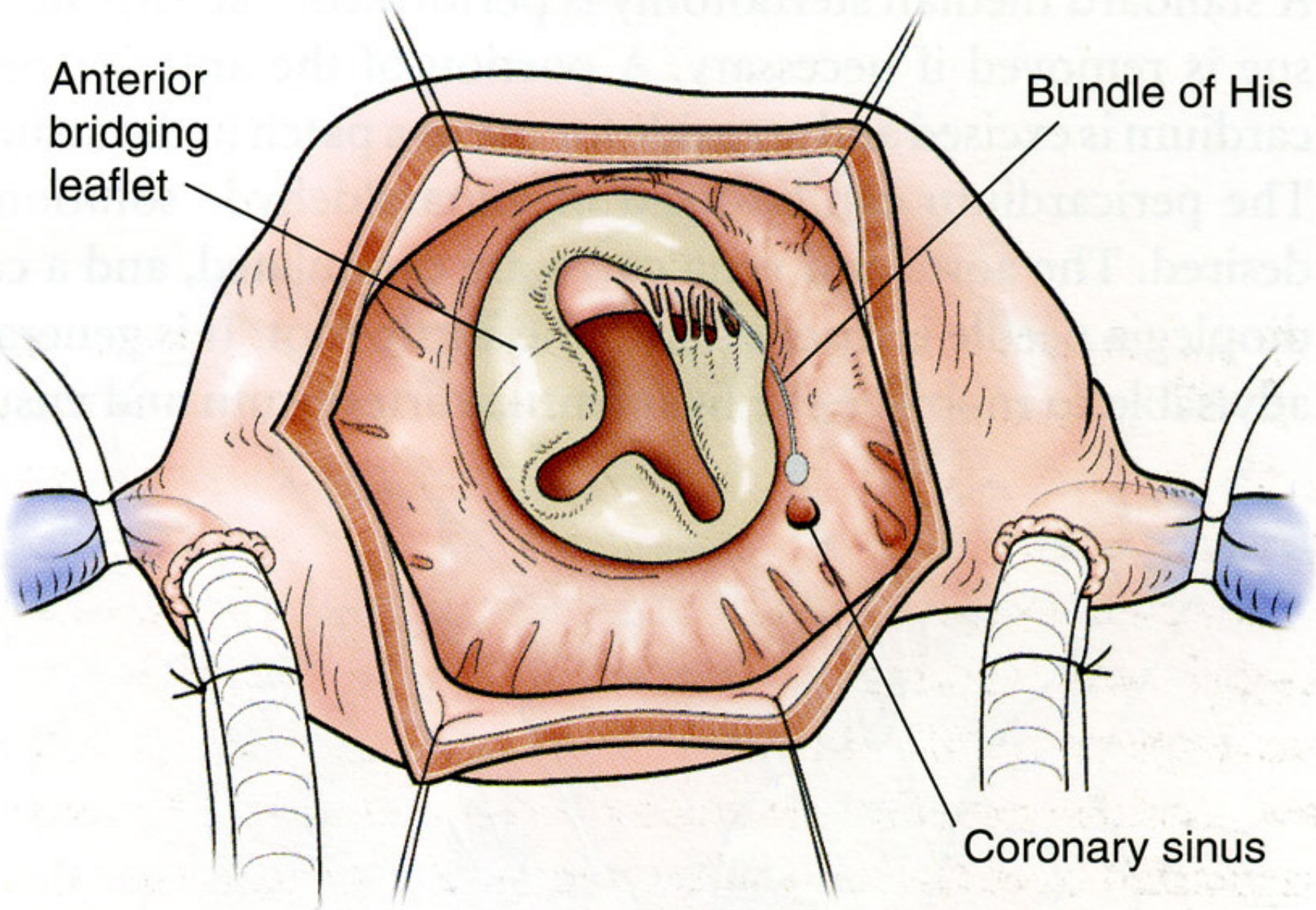
Anterior bridging leaflet
Bundle of His
Coronary sinus

CAV

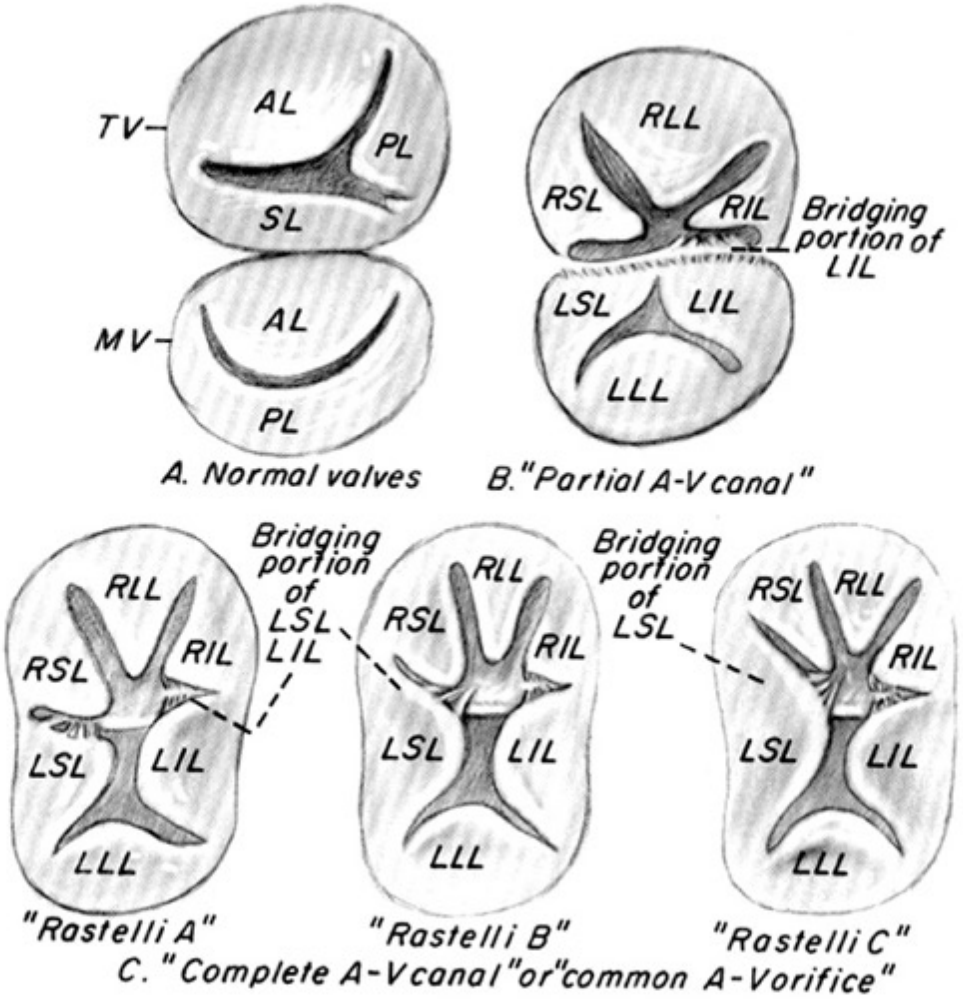
TV
AL
PL
SL
MV
AL
PL
A. Normal valves
RLL
RSL
RIL
Bridging portion of LIL
LSL
LIL
LLL
B. "Partial A-V canal"
Bridging portion of LSL LIL
RLL
RSL
RIL
LSL
LIL
LLL
"Rastelli A"
Bridging portion of LSL
RLL
RSL
RIL
LSL
LIL
LLL
"Rastelli B"
RSL
RLL
RIL
LSL
LIL
LLL
"Rastelli C"
C. "Complete A-V canal" or "common A-V orifice"

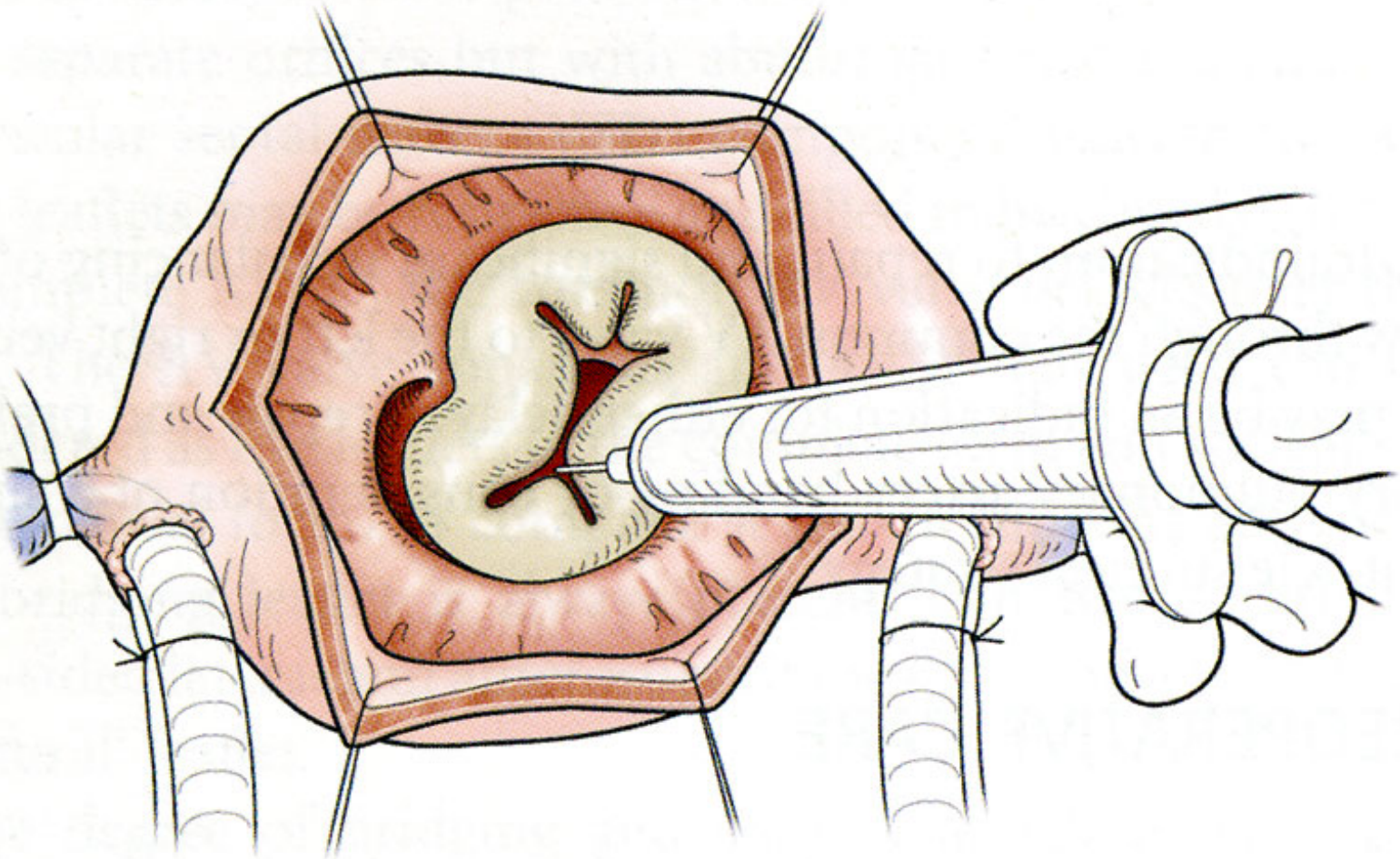

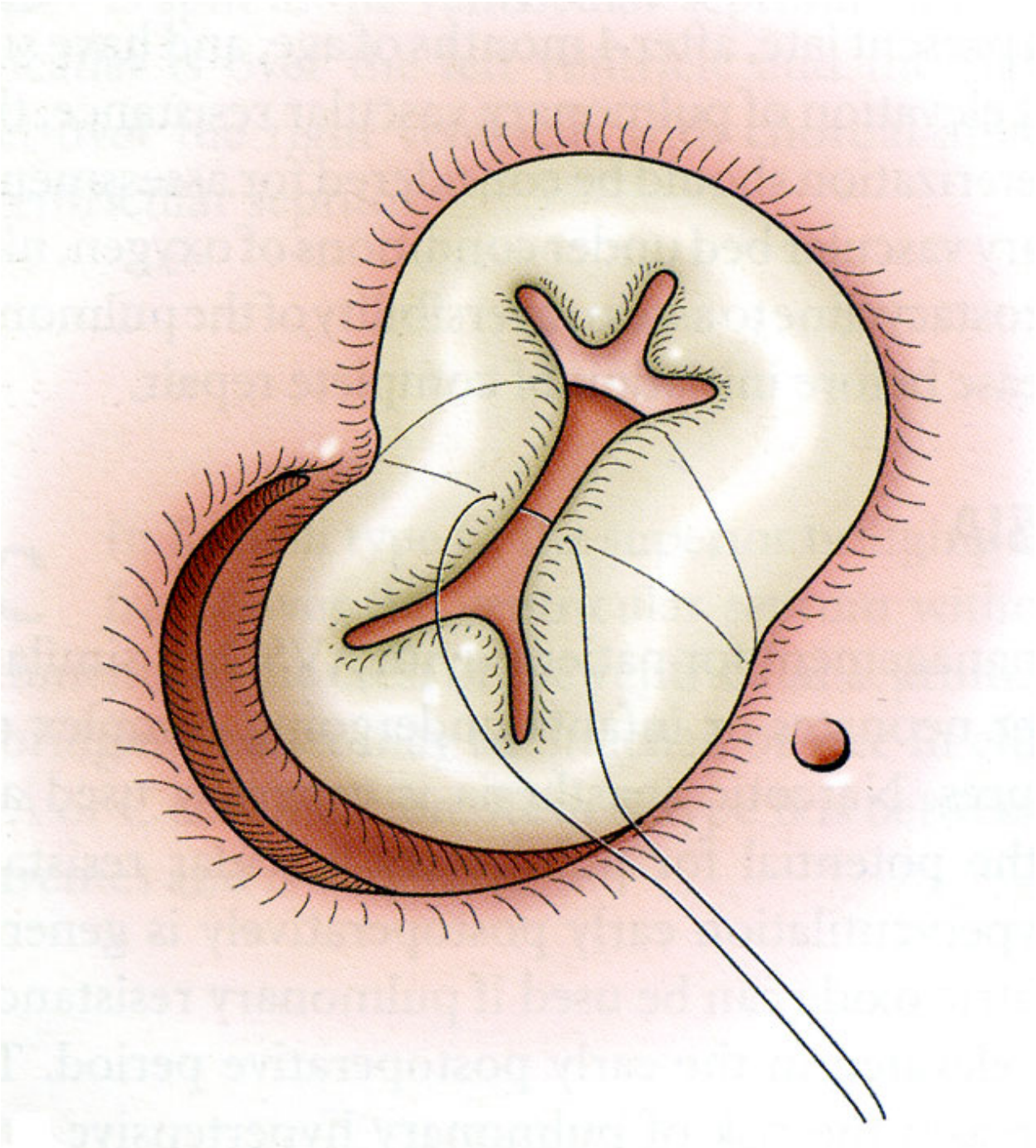

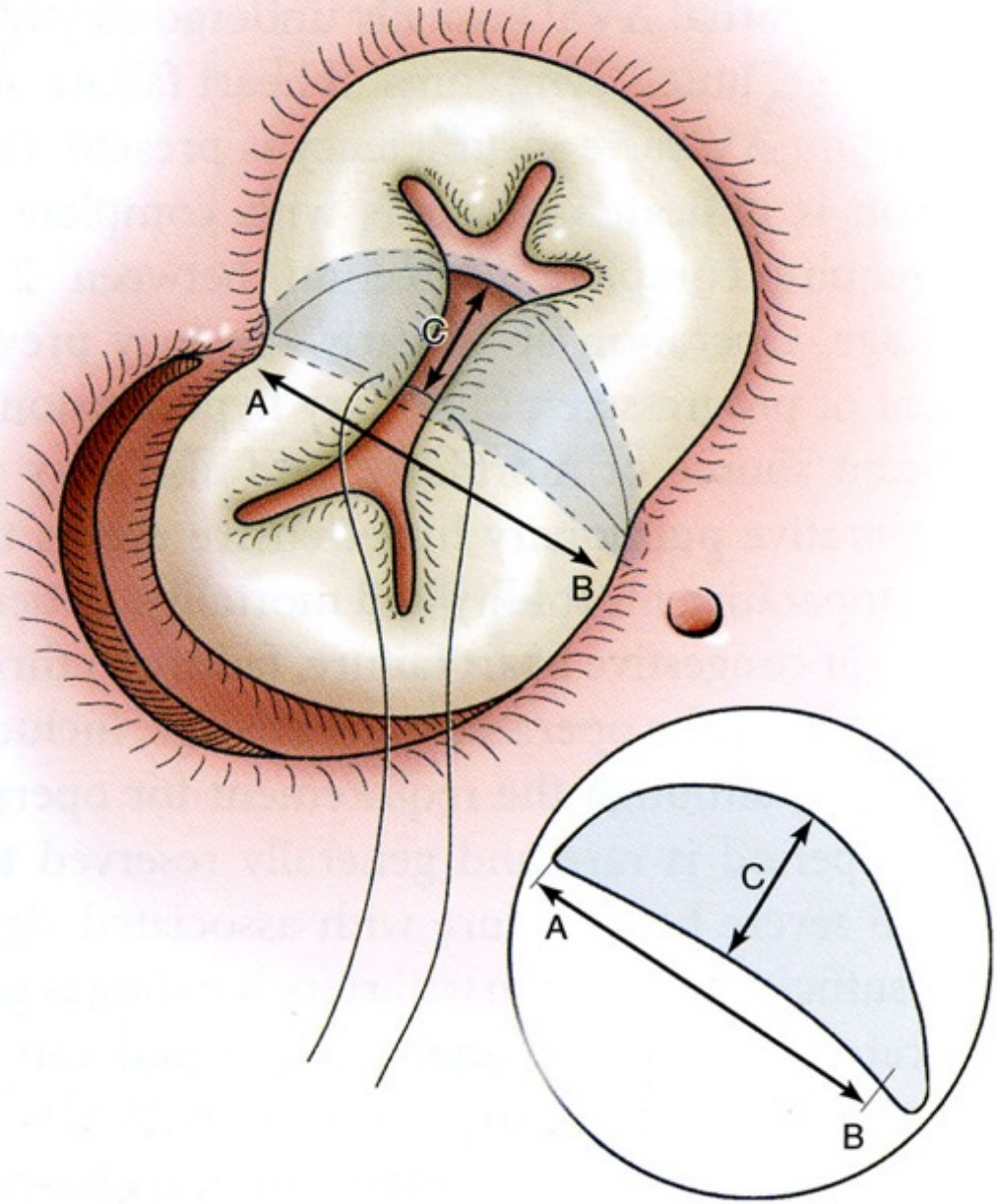
C
A
B
C
A
B

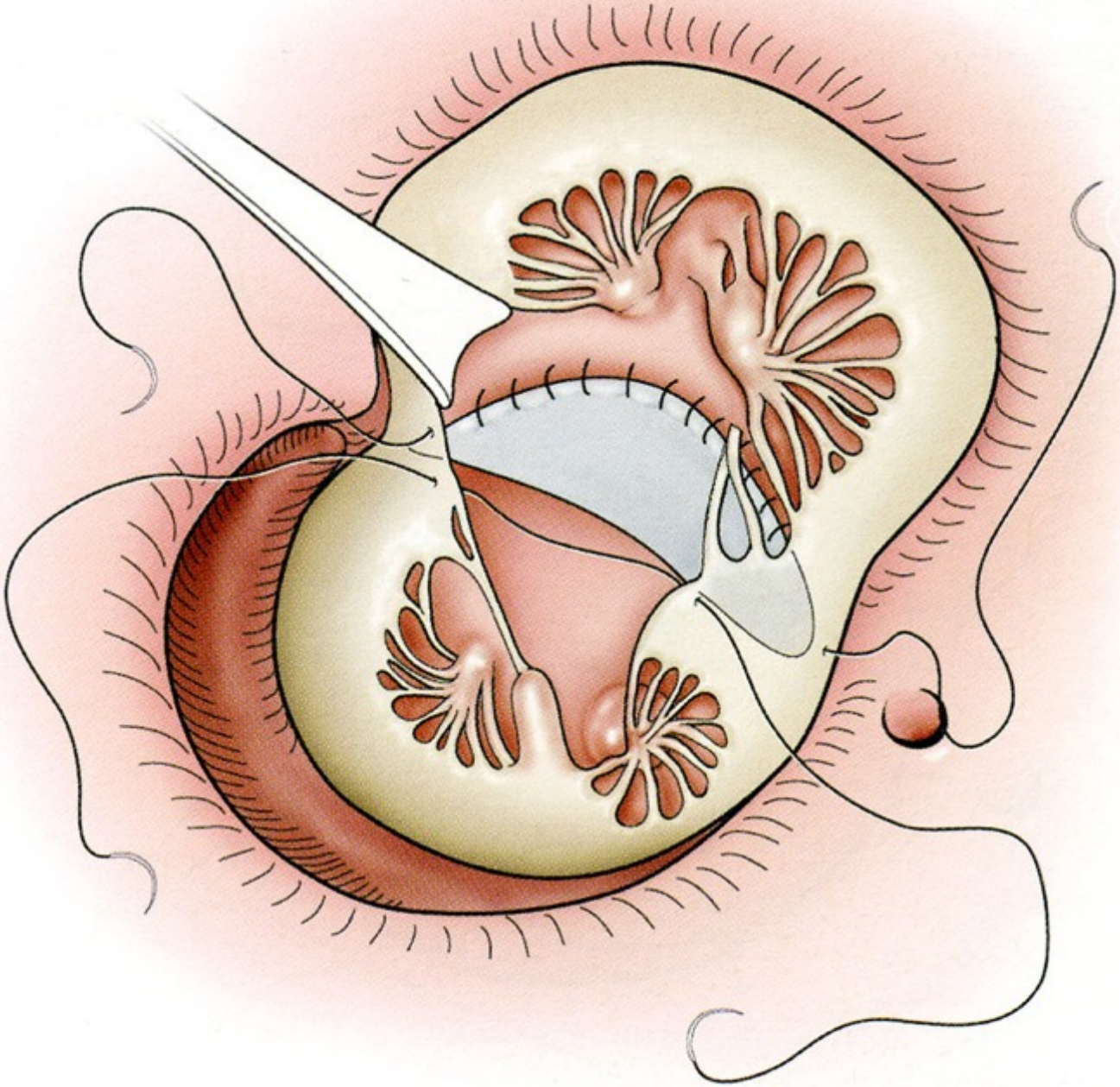

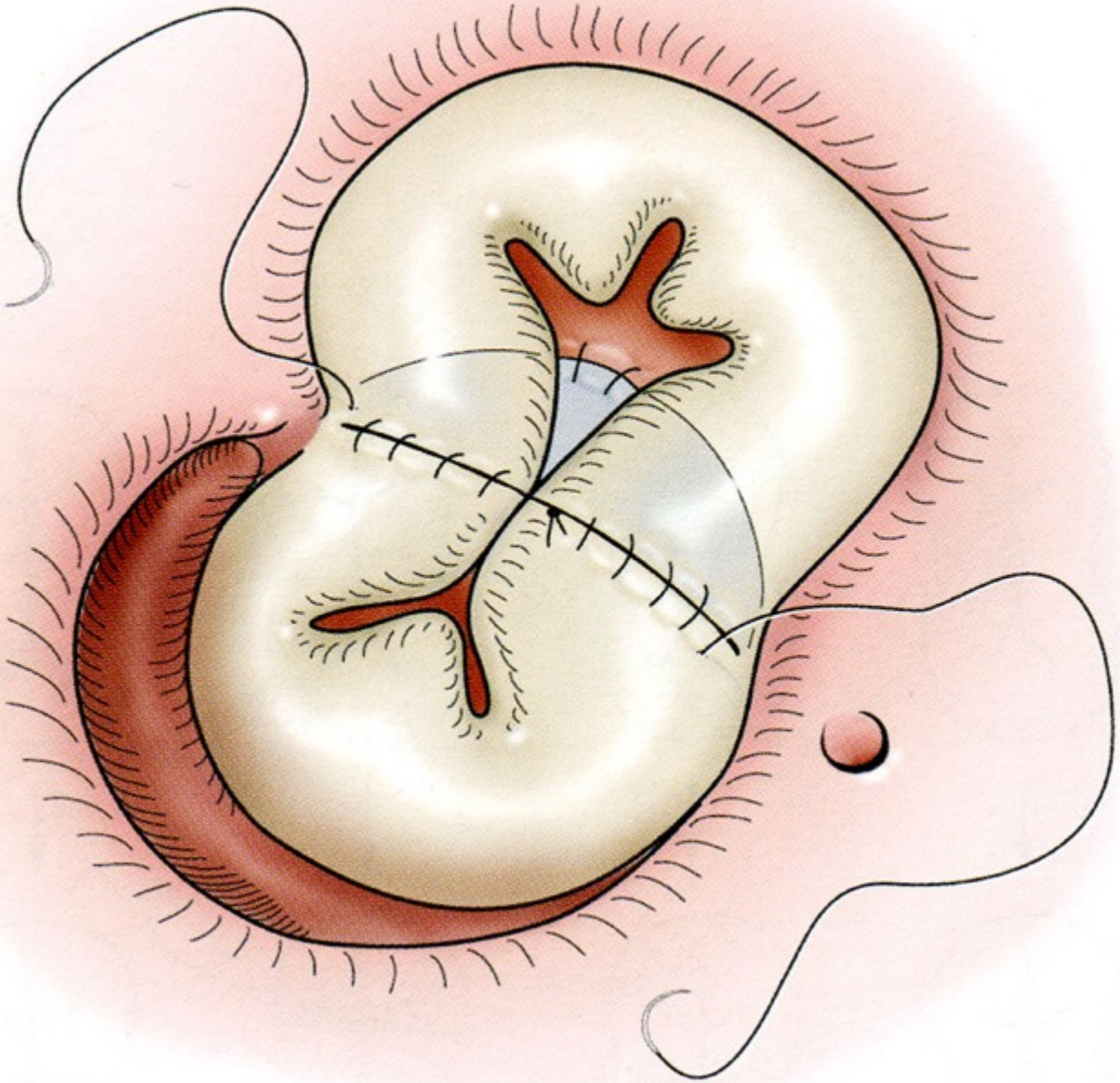

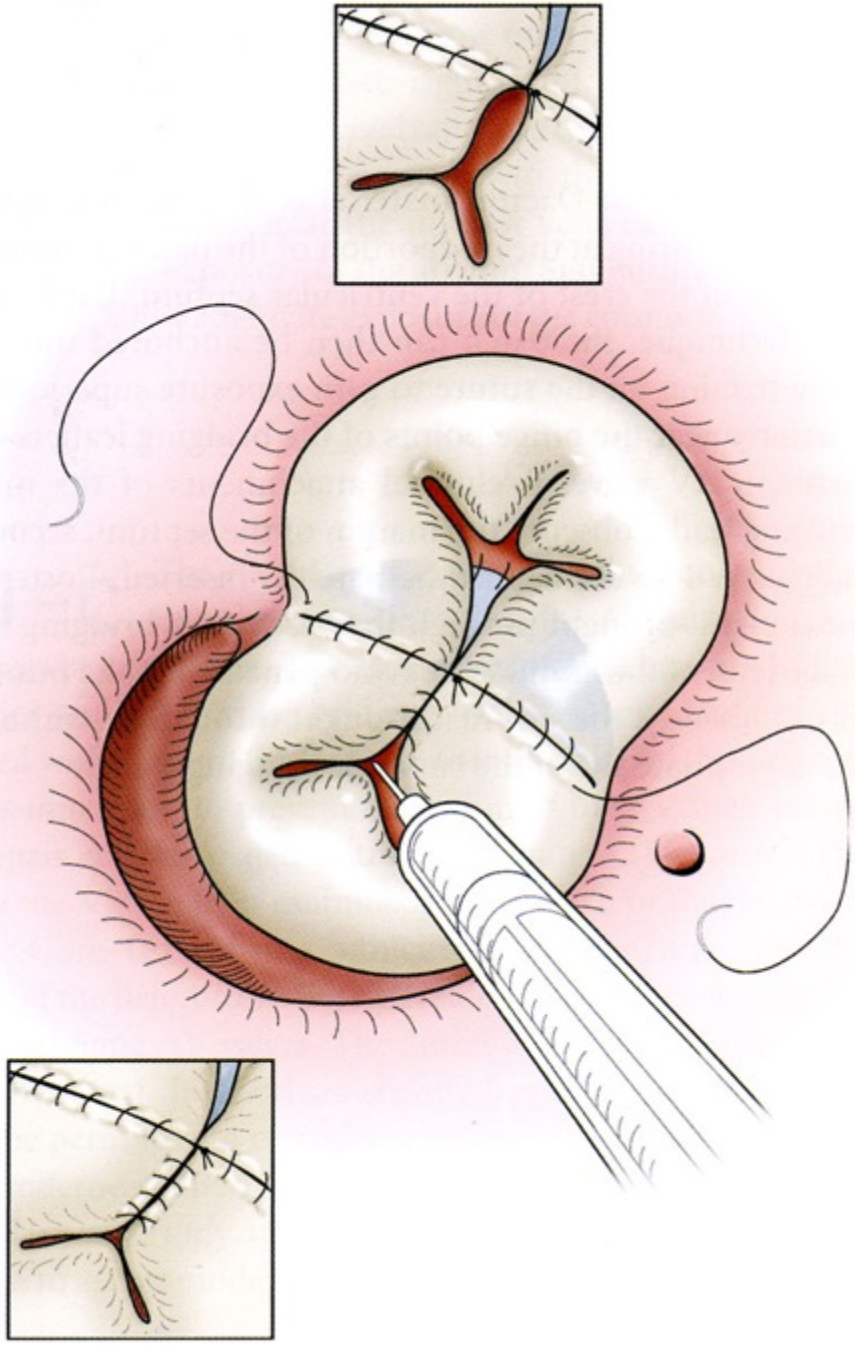

CAV complet

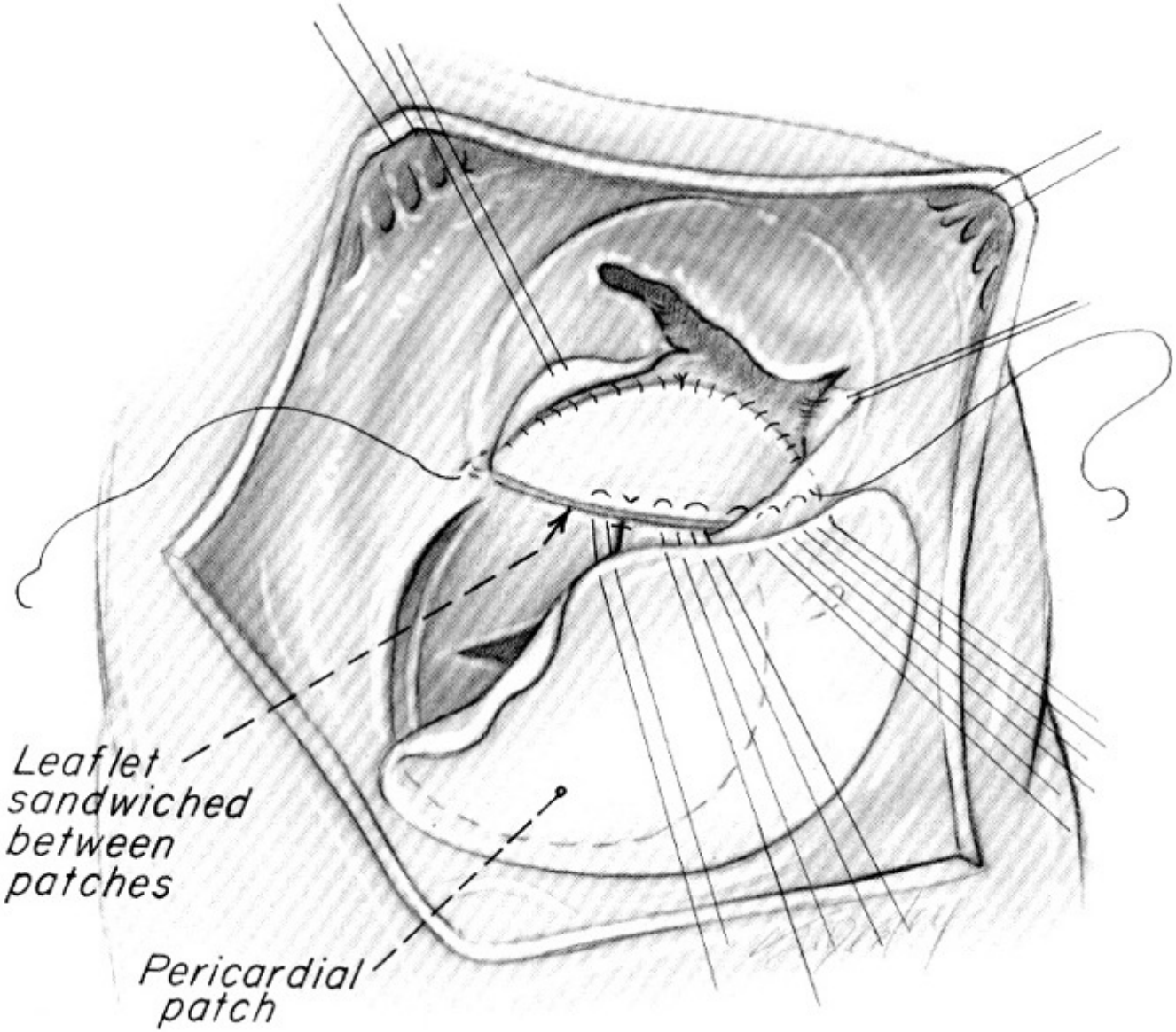

Créer deux valves AV fonctionnelles

- valve AV gauche
- valve AV droite
- intérêt écho per-opératoire

CAV : réparation mitrale

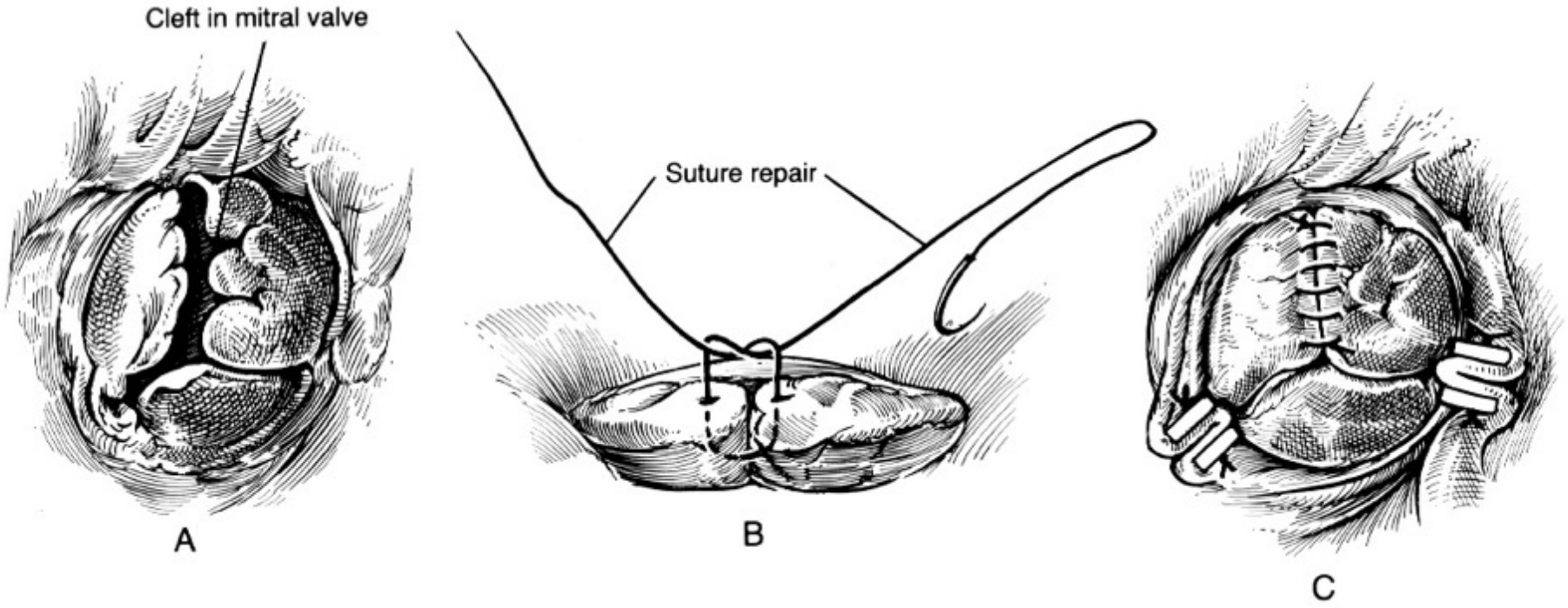

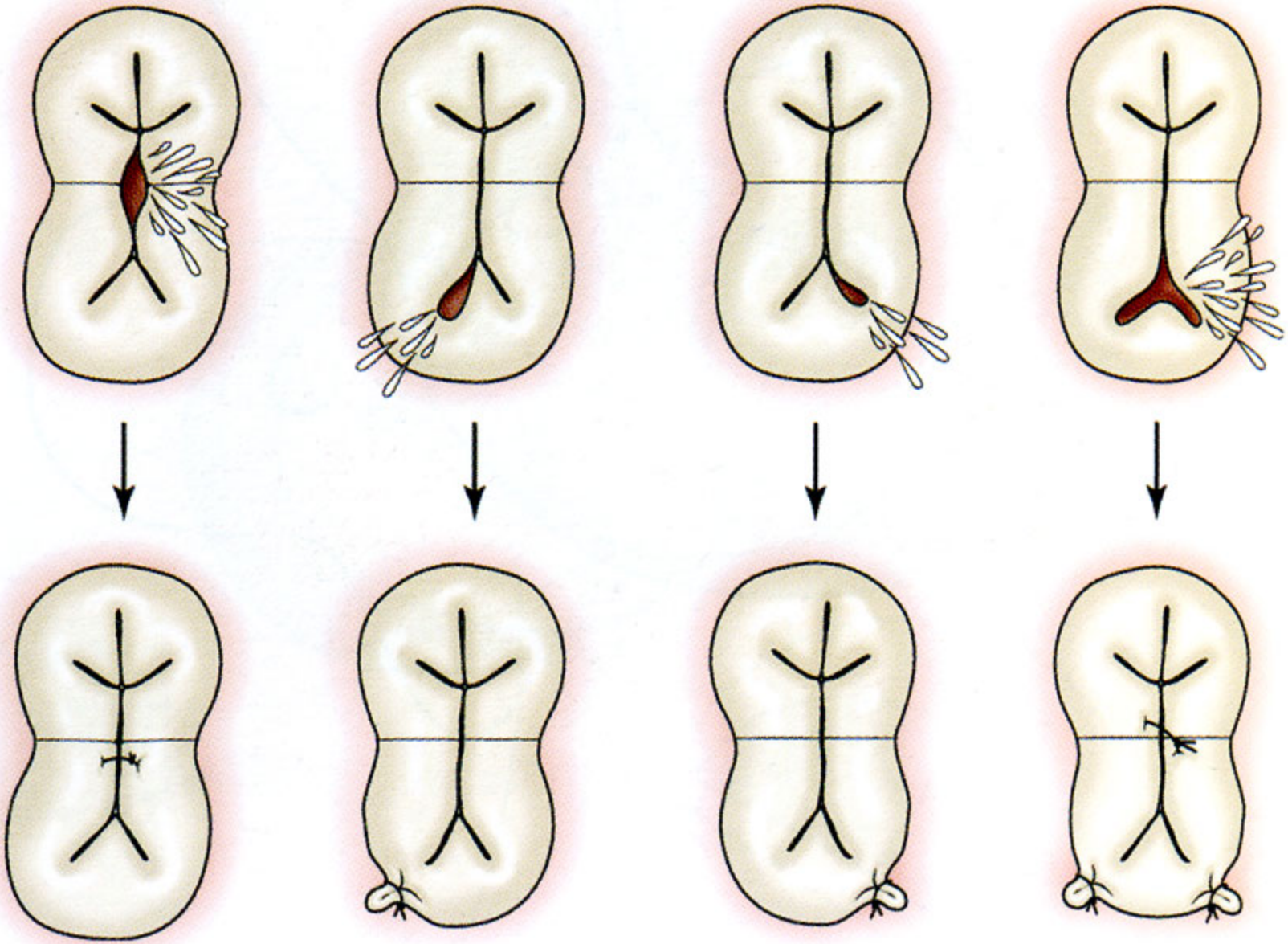

CAV : annuloplastie mitrale

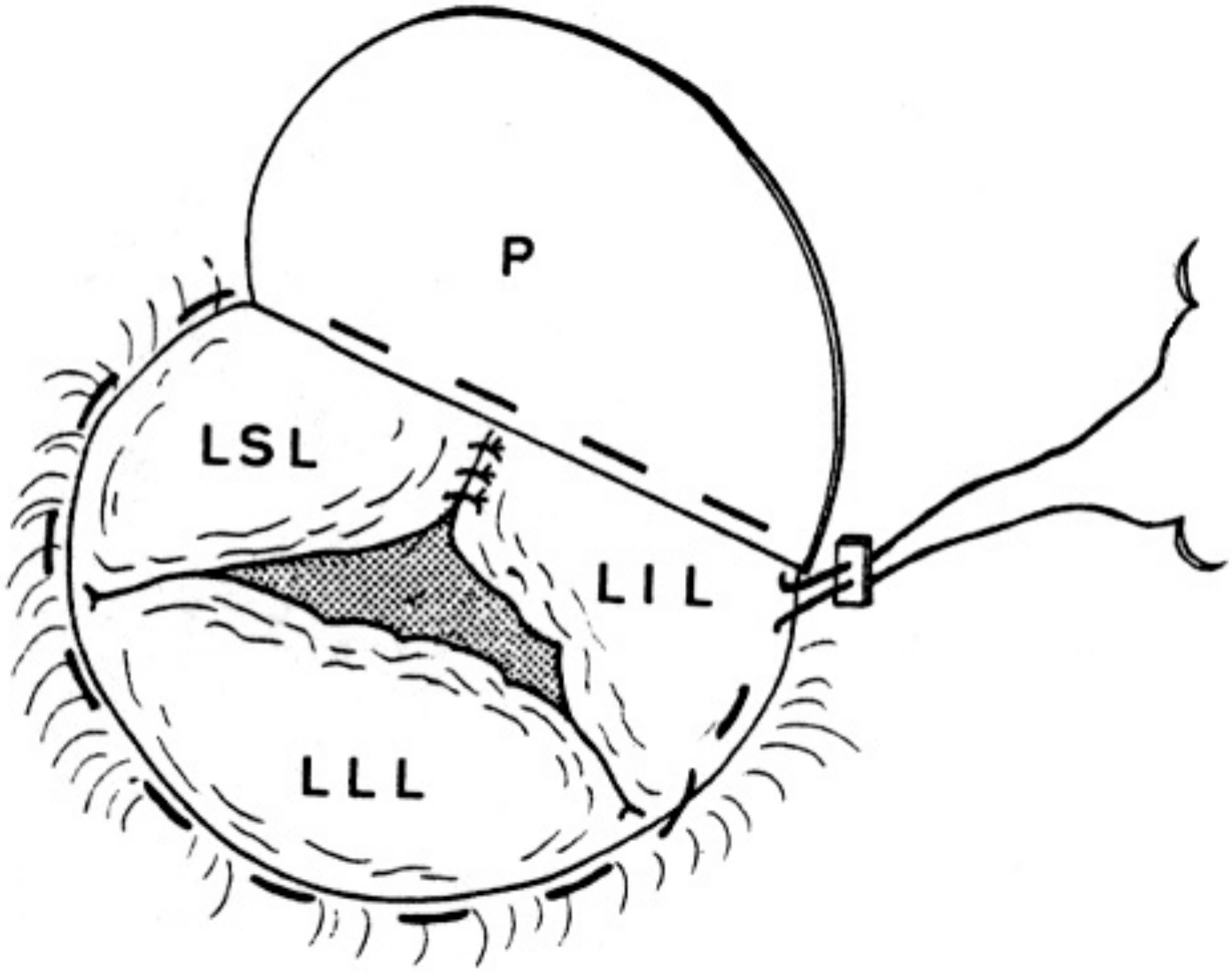

CAV : orifice mitral accessoire

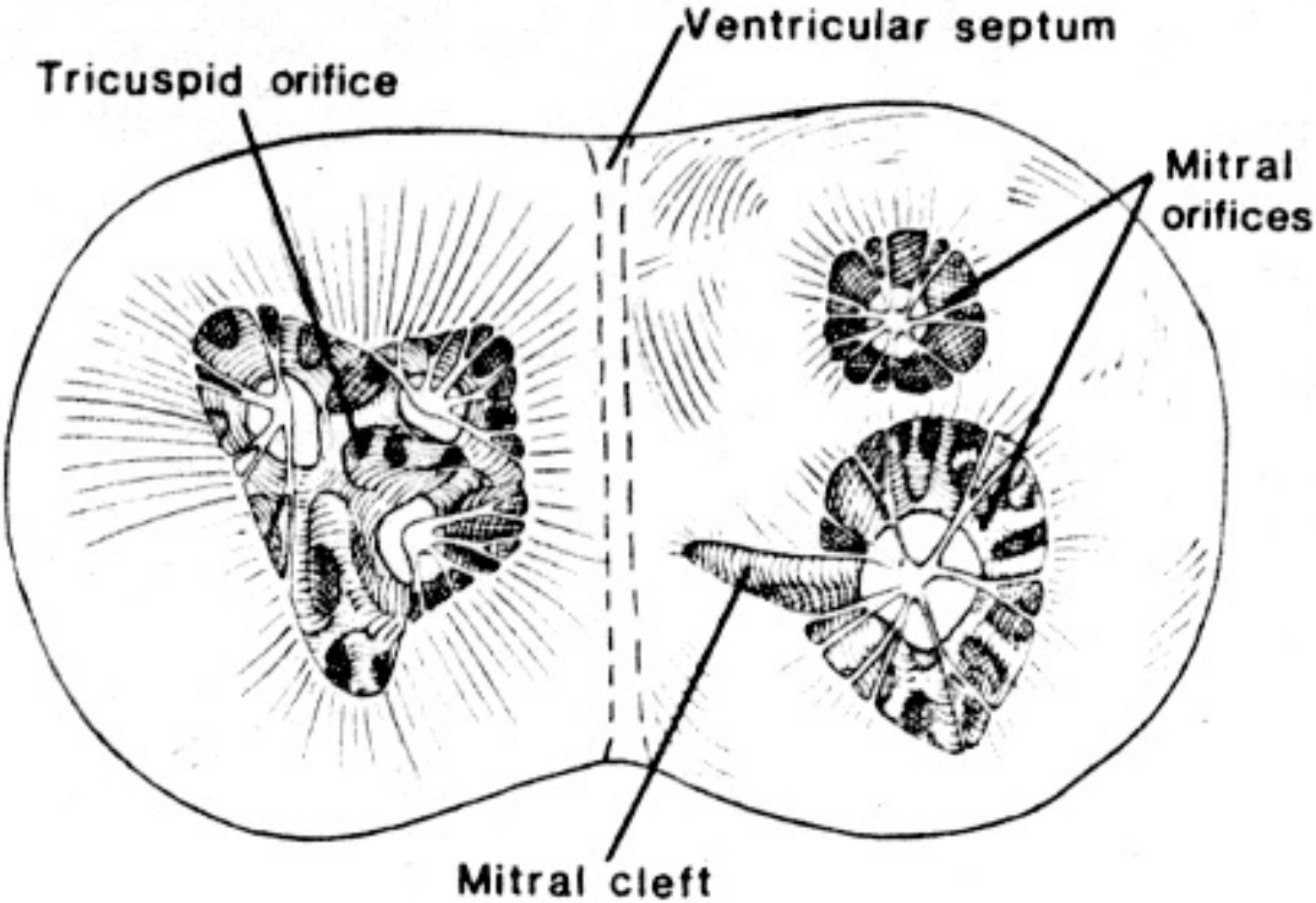

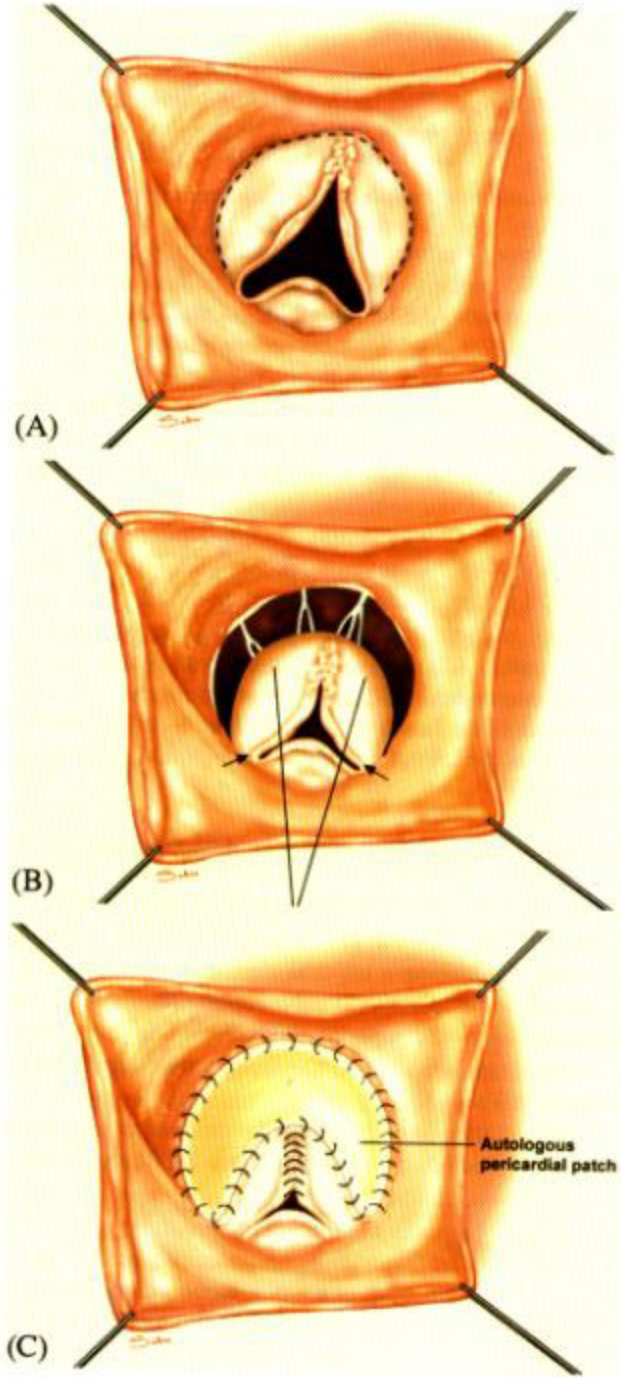
(A)
(B)
(C)
Autologous
pericardial patch

Eviter la lésion des voies de conduction

- position anormale des voies de conduction

- les points de suture doivent les éviter

  - sur le septum interventriculaire
  - pendant le cloisonnement inter-auriculaire (laisser le sinus coronaire du côté gauche)

CAV complet

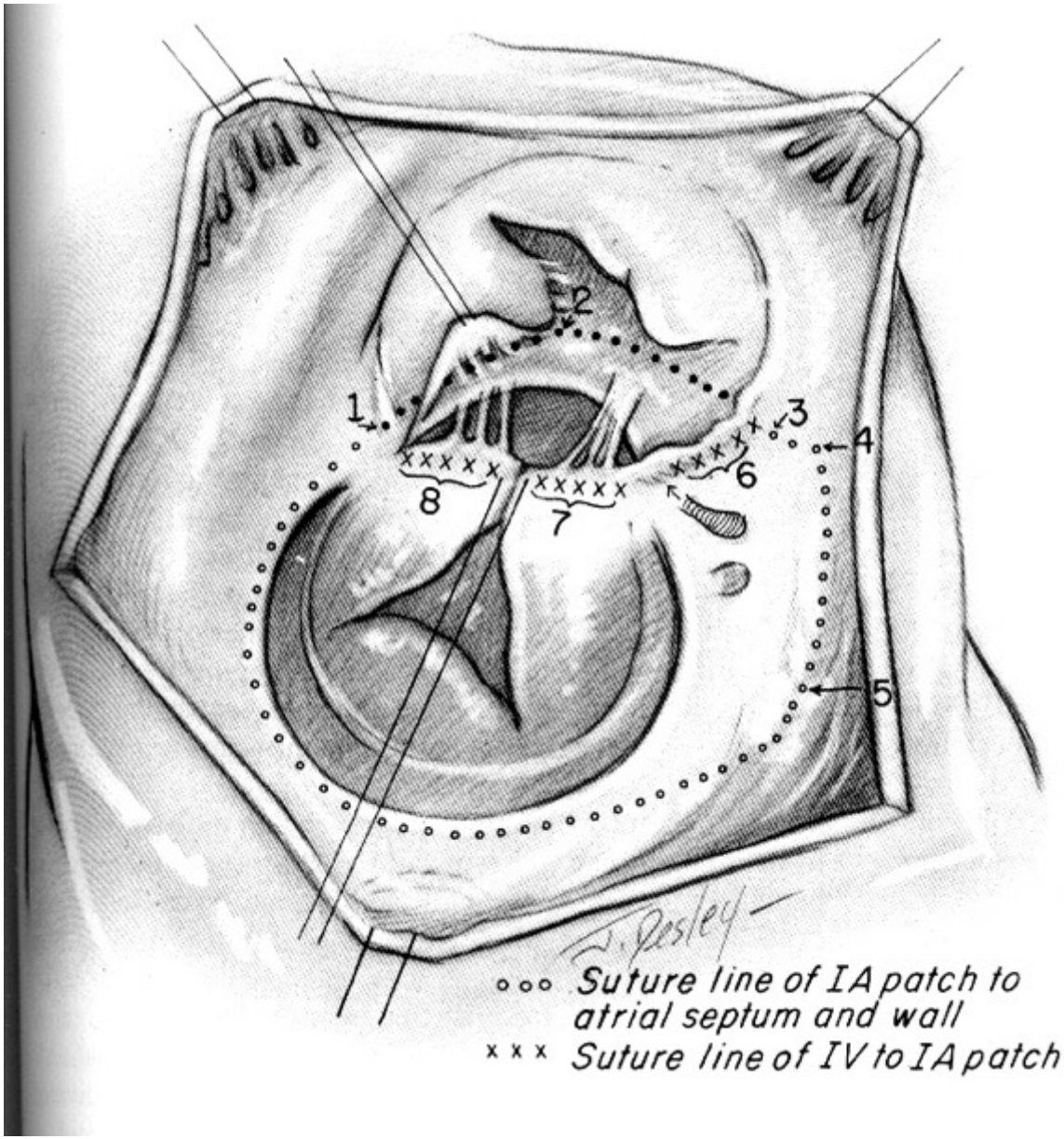
1
2
3
4
5
6
7
8
Suture line of IA patch to atrial septum and wall
Suture line of IV to IA patch

Eviter sténose de la voie sous-aortique

- taille adéquate du patch interventriculaire
- section de cordages anormaux
- résection de tissu valvulaire accessoire

Laisser CIA résiduelle calibrée

- droite – gauche : HTAP
- gauche – droite : insuffisance mitrale,
  défaillance VG.

Identifier les patients avec ventricules déséquilibrés

- déséquilibre majeur : ventricule unique
- déséquilibre modéré
  - absence de règle précise
  - traitement individualisé

Lésions résiduelles potentielles

- CIV résiduelle
- insuffisance mitrale / sténose mitrale
- insuffisance tricuspidienne
- sténose sous-aortique