TRONC ARTERIEL COMMUN

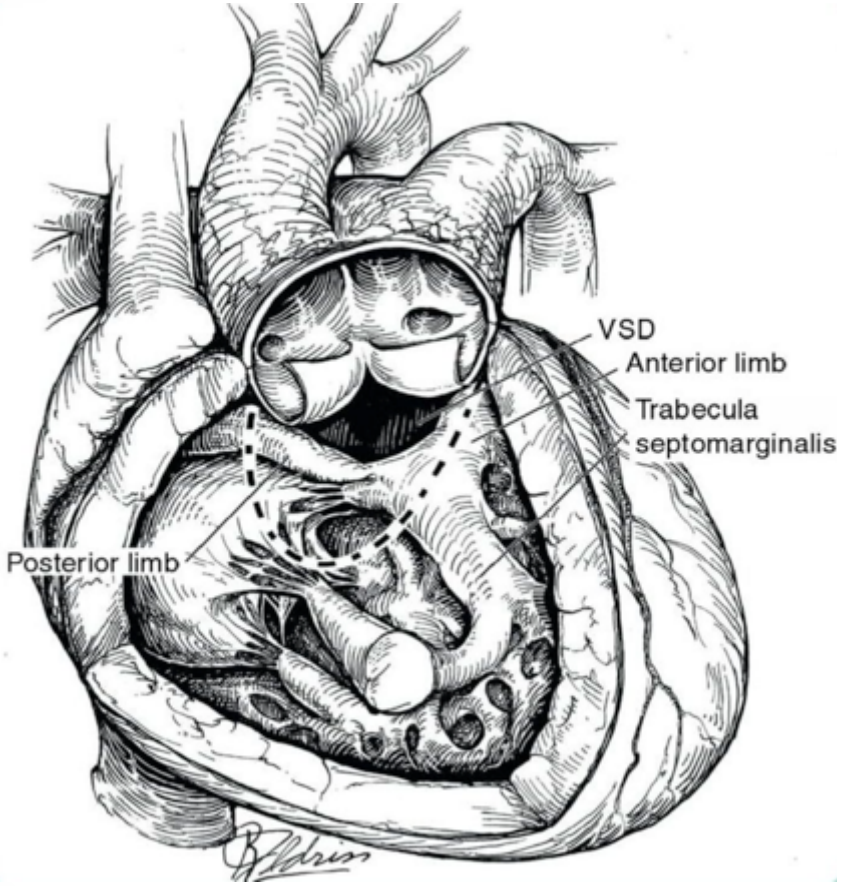

Zakaria Jalal

Cardiopathies congénitales de l'enfant et de l'adulte
Hôpital cardiologique Haut Lévêque Pessac

DEFINITION

- 1.4% des cardiopathie congénitales
- Cardiopathie conotroncale
- Echec de septation conale et aorticopulmonaire
- Diagnostic anténatal
- Souvent associé à un 22q11

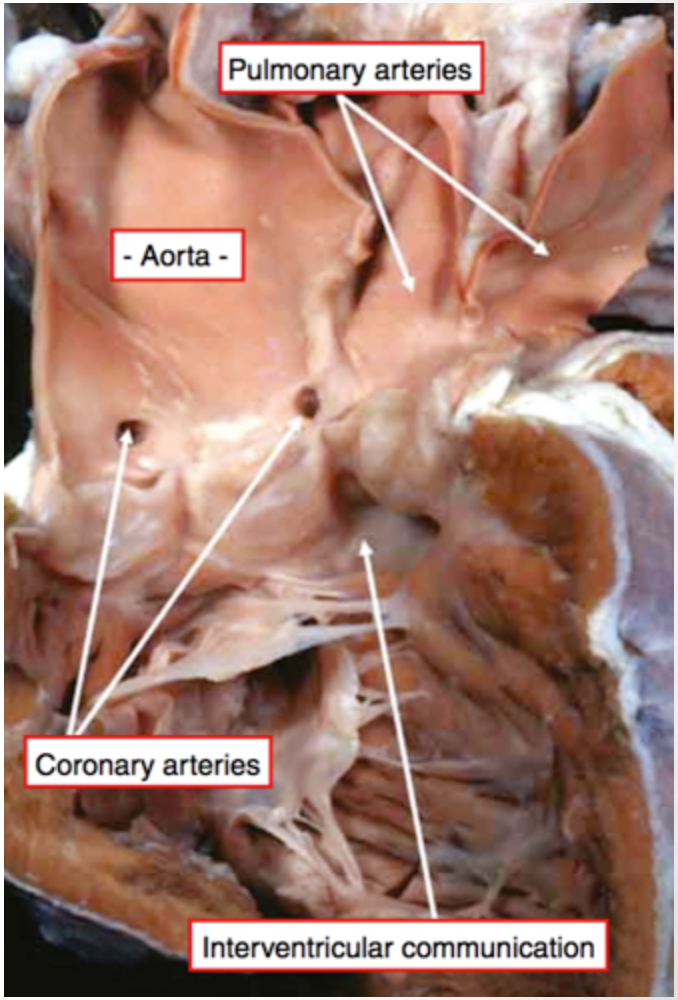

EMBRYOLOGIE

- Cell
  ->
- Expe
  - t
    d
  - p
    d
    C
  - a
- Hon

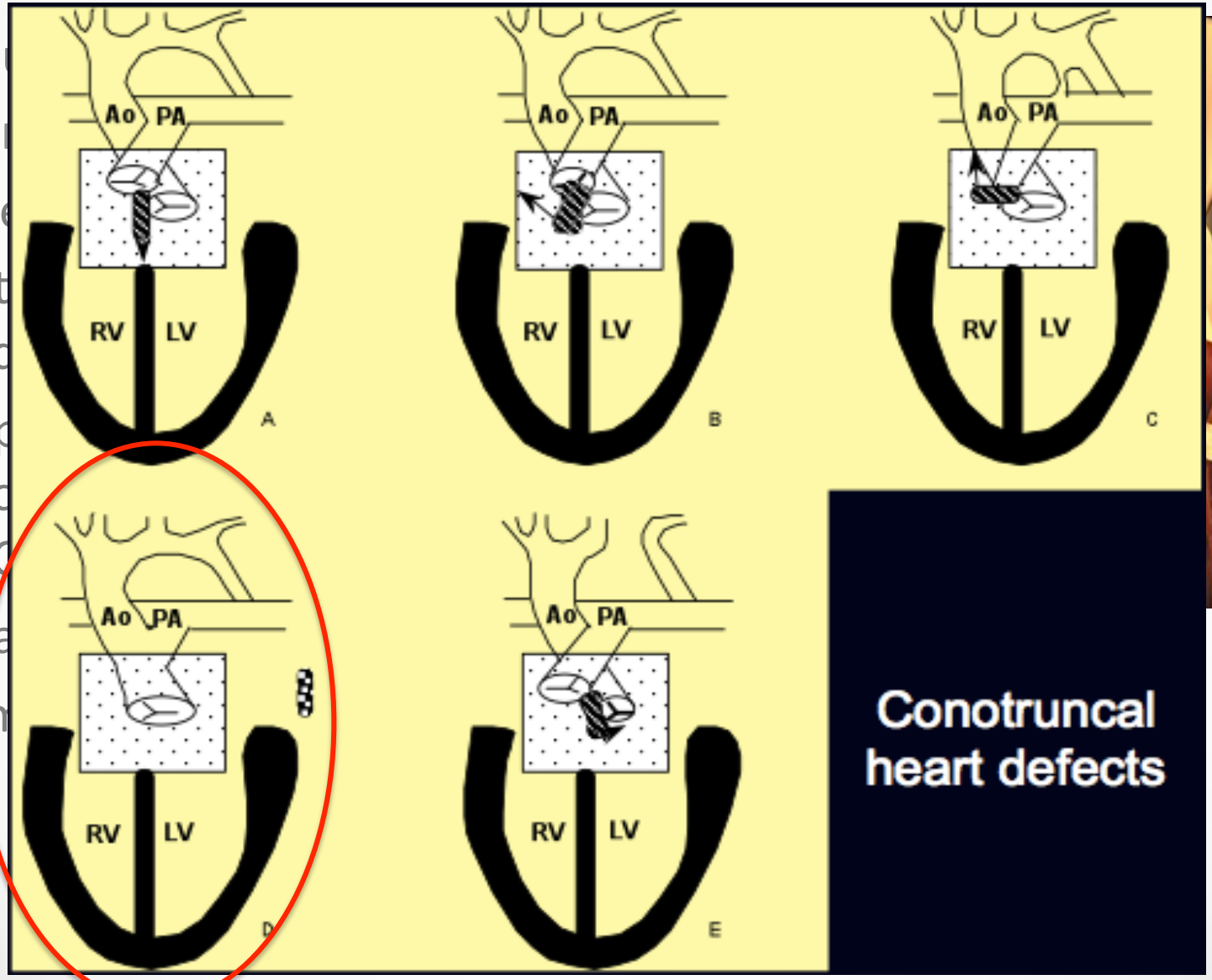

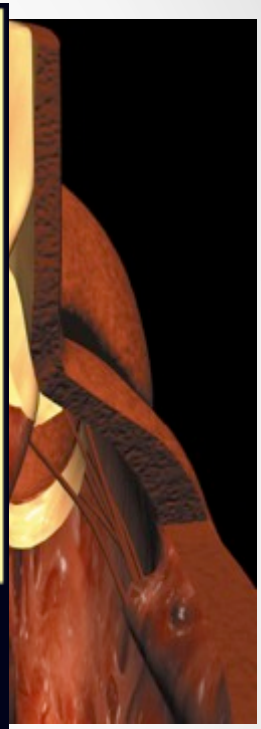

ANATOMIE

- CIV large cono-troncale
- Valve troncale avec tronc commun
  - Tricuspide 2/3
  - Bi ou Quadricuspide 1/3
- Naissance branches pulmonaires variable = Classification de Van Praagh
- Anomalies coronaires
- Crosse aortique droite

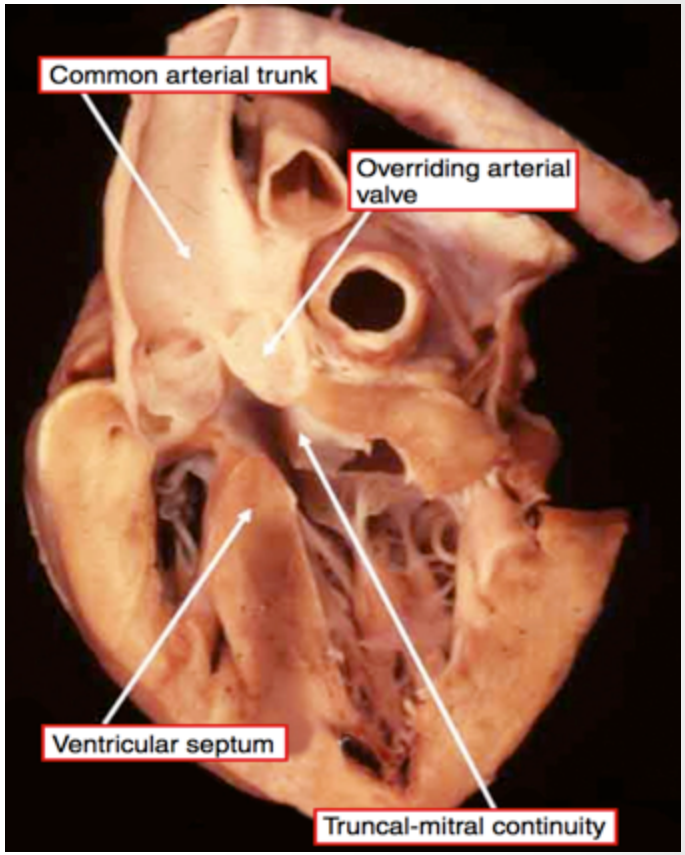



Houyel et al. J Anat 2013

FORMES ANATOMIQUES

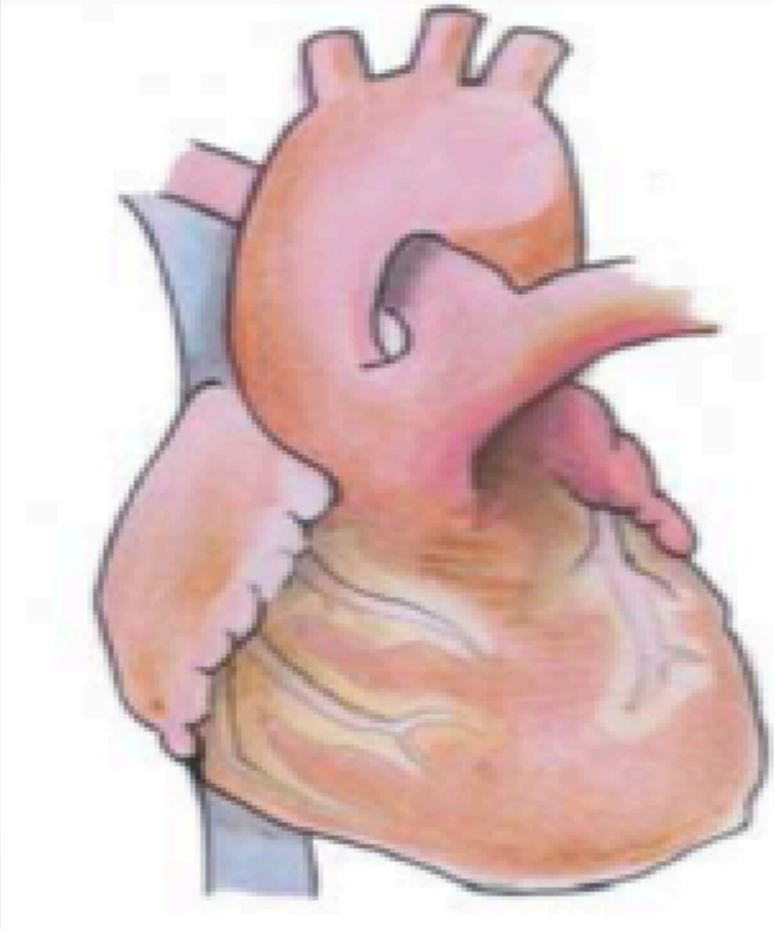

Type I
Présence d'un TAP
65 %

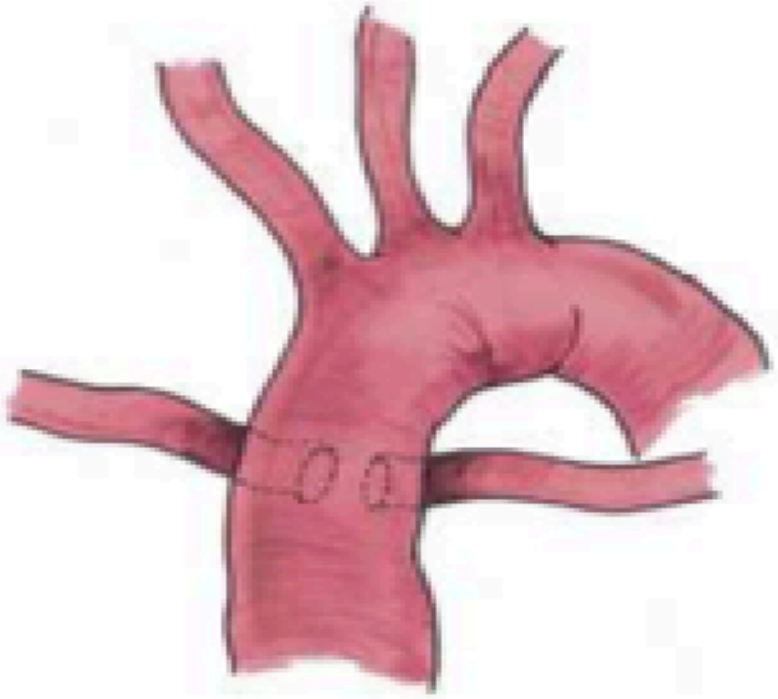

Type II
Branches naissant séparément
25 %

FORMES ANATOMIQUES

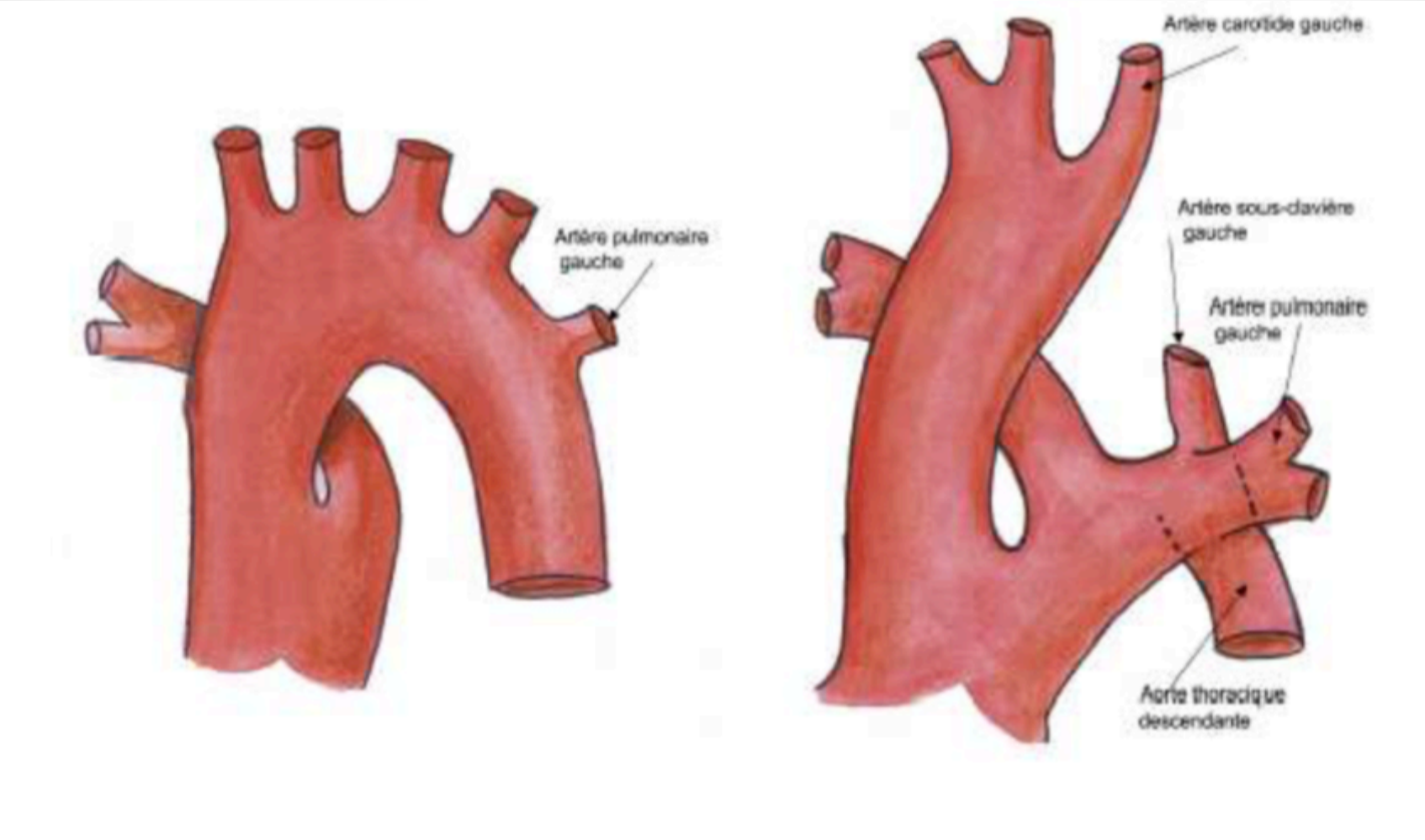

Type III
APG de l'Ao desc

Type IV
I + IAAo
90 % del 22q1.1

PHYSIOPATHOLOGIE

- **Cardiopathie à sang mélangé**, Sat Ao = Sat AP
- Qp/qs évalué de manière non invasive
- **Qp/Qs = Sat Ao – Sat SVM / Sat VP – Sat AP**
- Shunt: ratio résistances systémiques/pulmonaires
- Cyanose modérée à la naissance
- Augmentation du débit pulmonaire avec baisse des RVP
- Artériolite pulmonaire à partir de 6 mois

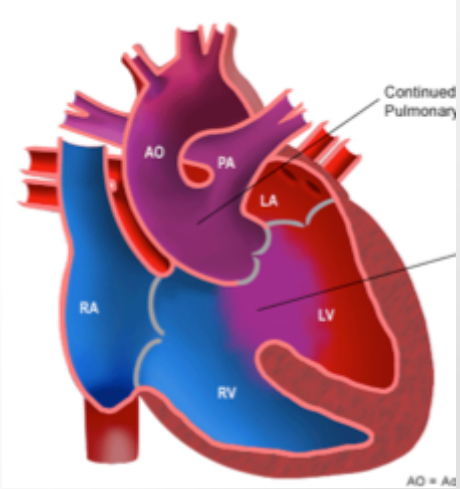

CIRCONSTANCES DE DECOUVERTE

- Diagnostic anténatal : fish 22q1.1
- Discrète cyanose ou désaturation
- Souffle systolique (double souffle si fuite valve troncale)
- Signes d' hyperdébit pulmonaire ++
- Dysmorphie faciale, autres signes 22q1.1

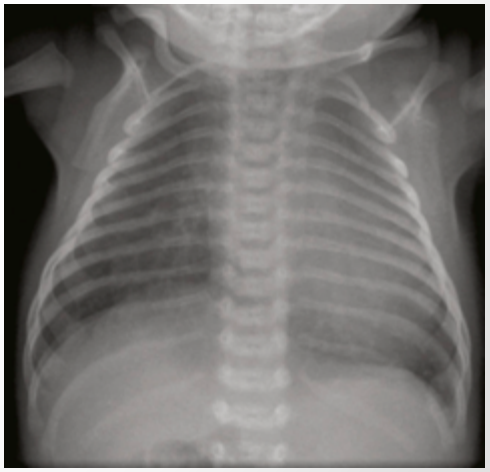

ETT

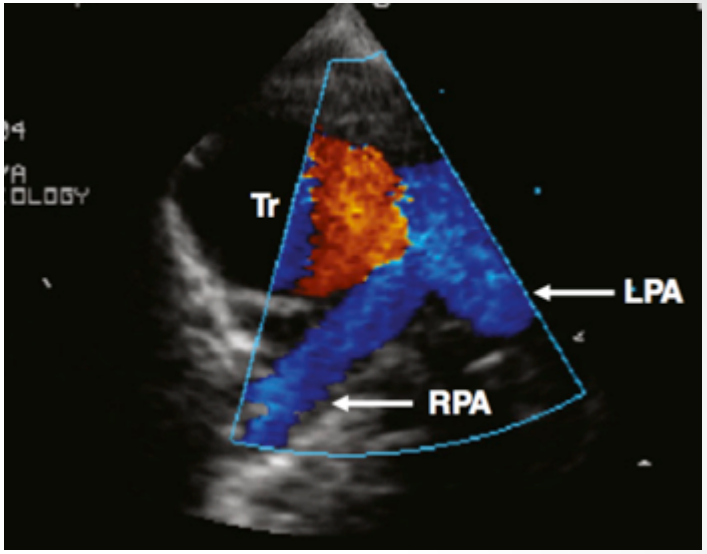

- Diagnostic positif
  - CIV conotroncale
  - Tronc commun Ao - AP
- Analyse de la valve troncale (nbr feuillets, fonction)
- Disposition coronaire
- Retentissement (dilatation cavités gauches)
- Lésions associées

ETT

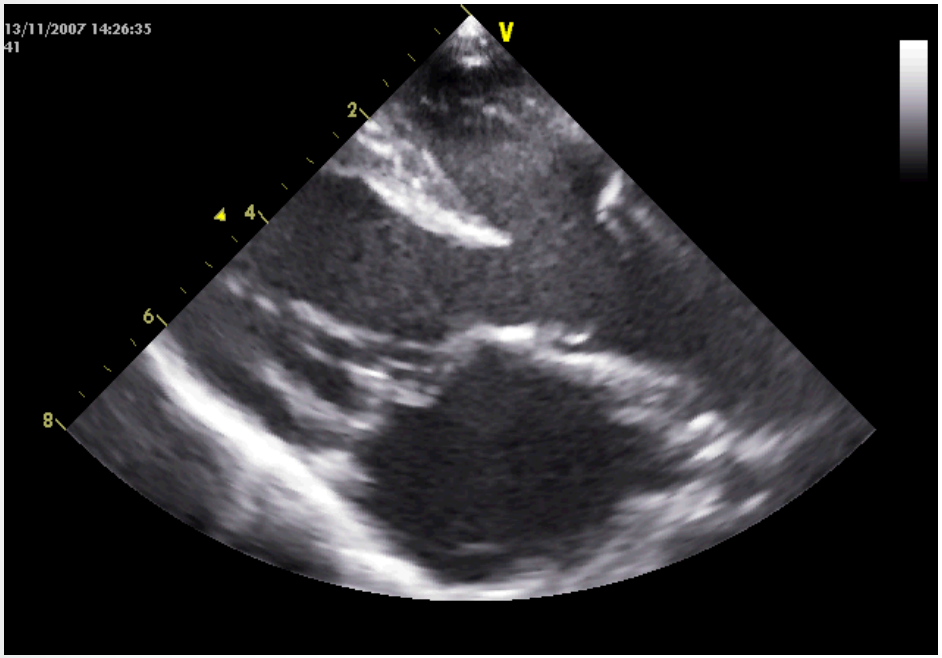

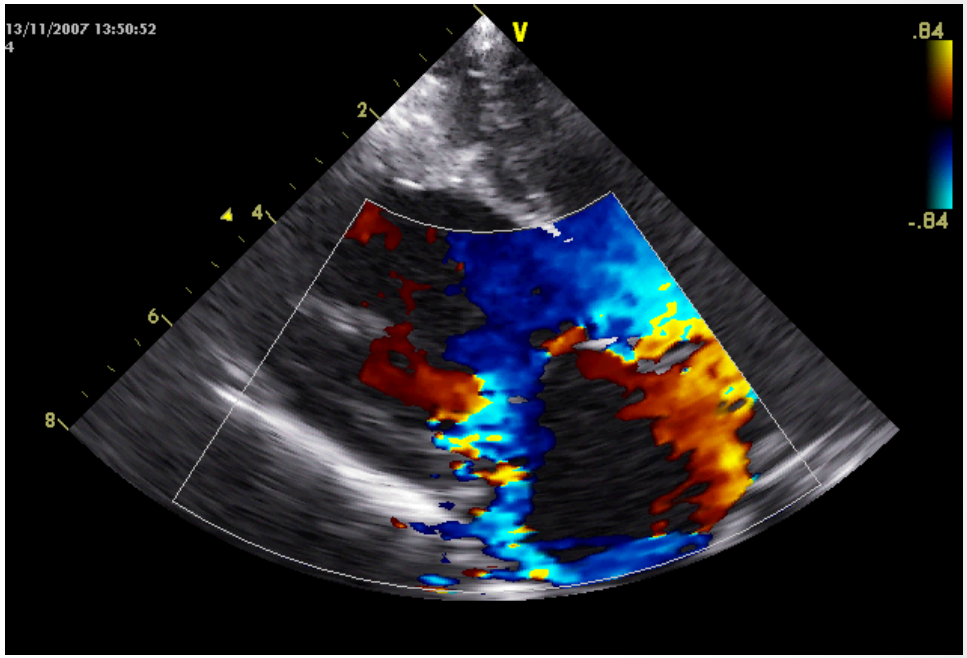

CIV conotroncale

ETT

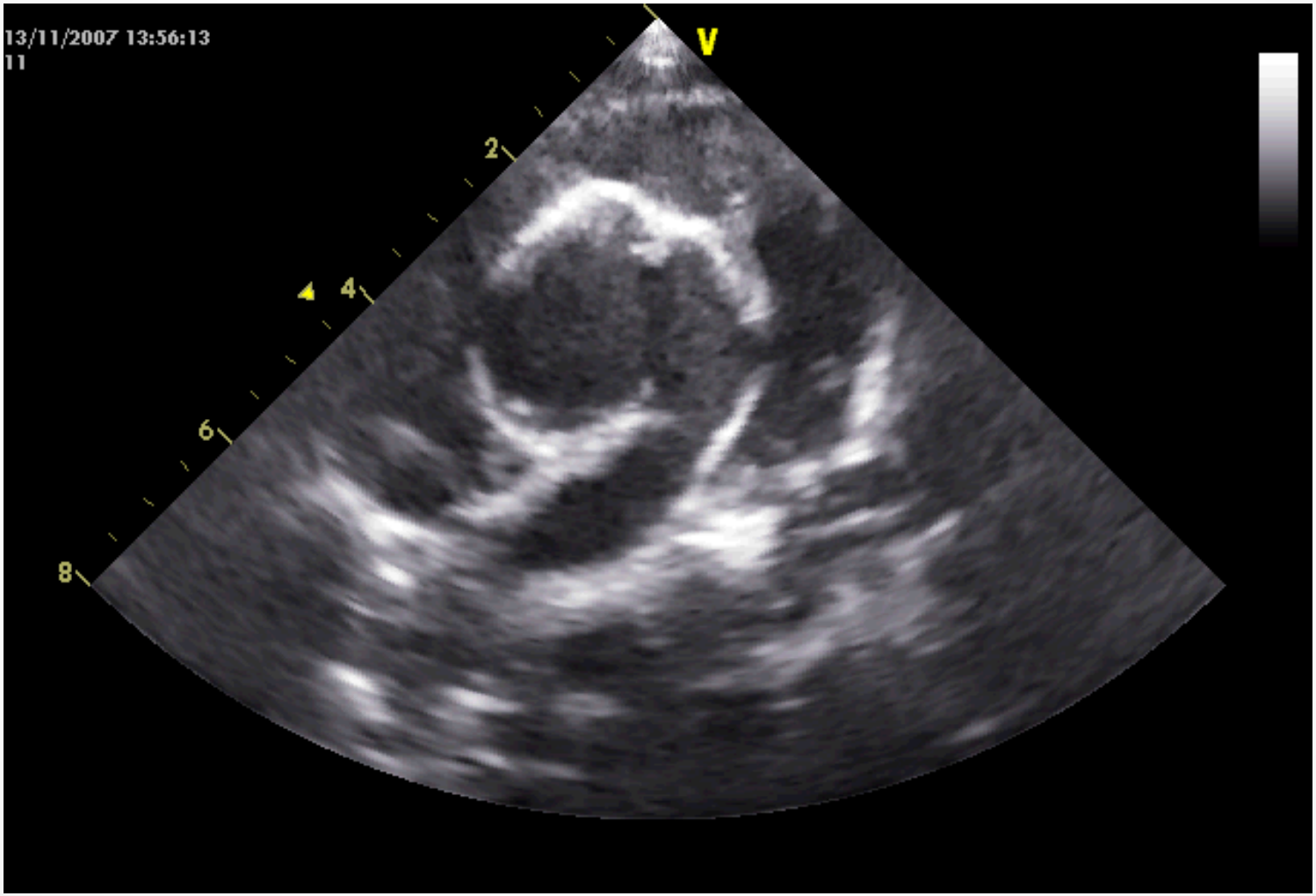

ETT

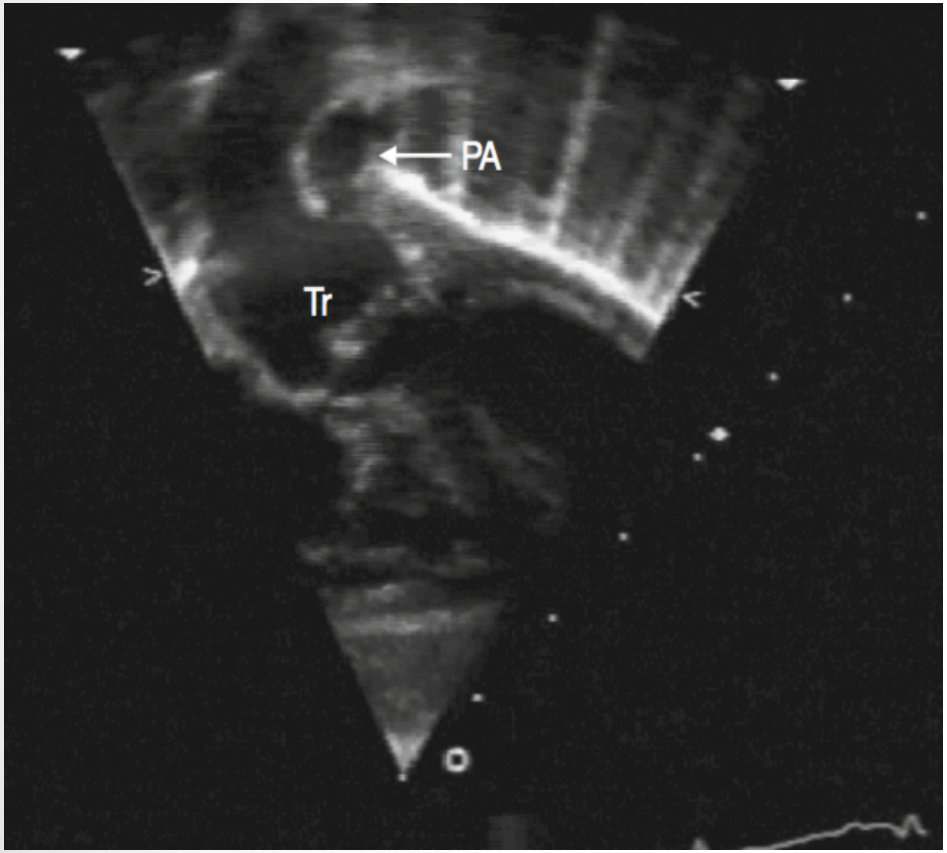

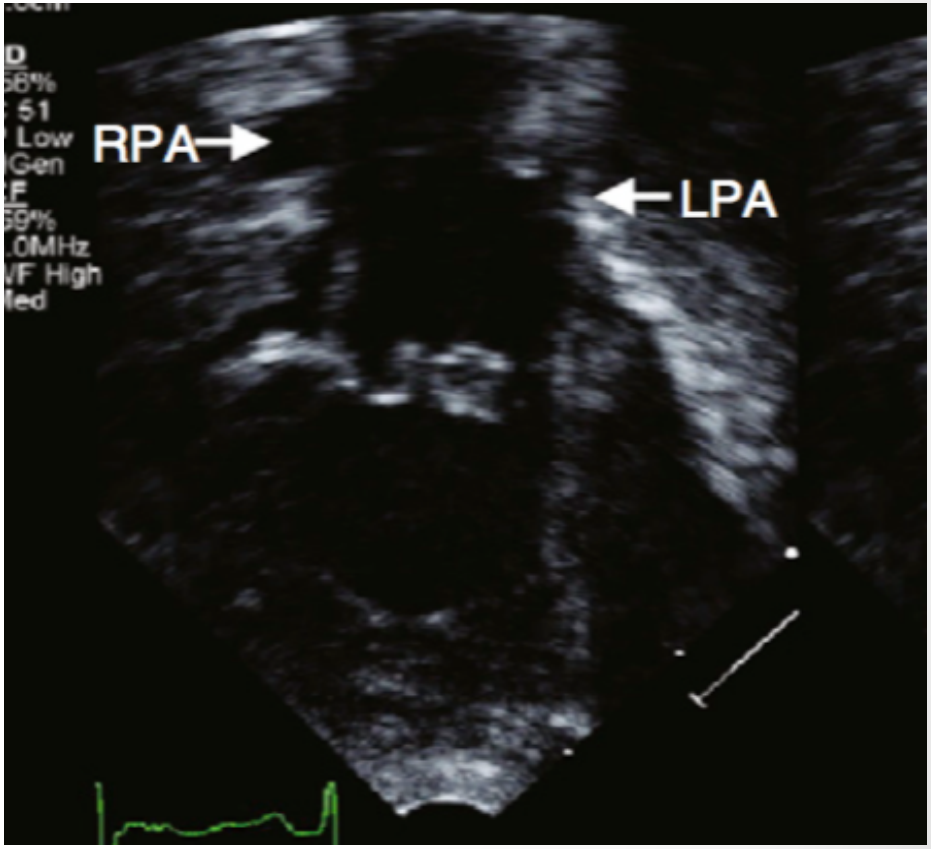

PRISE EN CHARGE PRÉOPÉRATOIRE

- Gestion du shunt en jouant sur les RVS / RVP
- Diurétiques si signes congestifs
- Chirurgie pour cure complète avant 1 mois

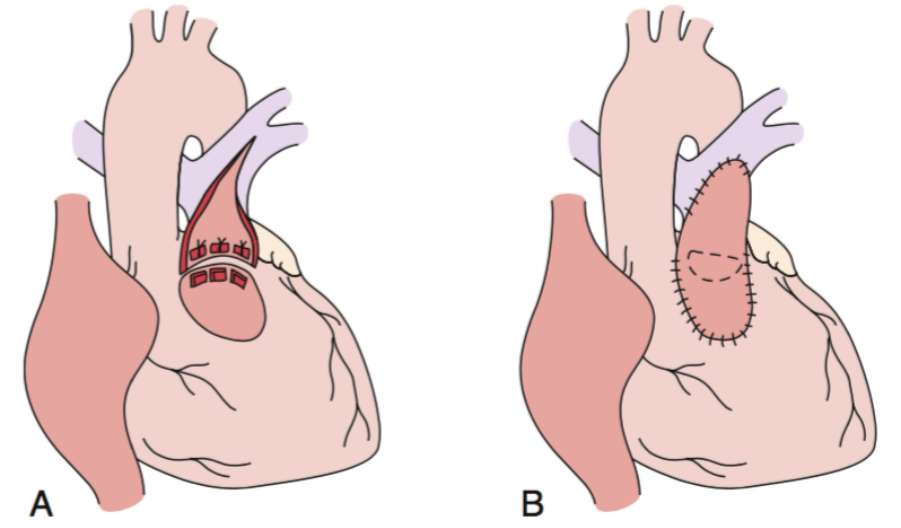

DEVENIR À LONG TERME

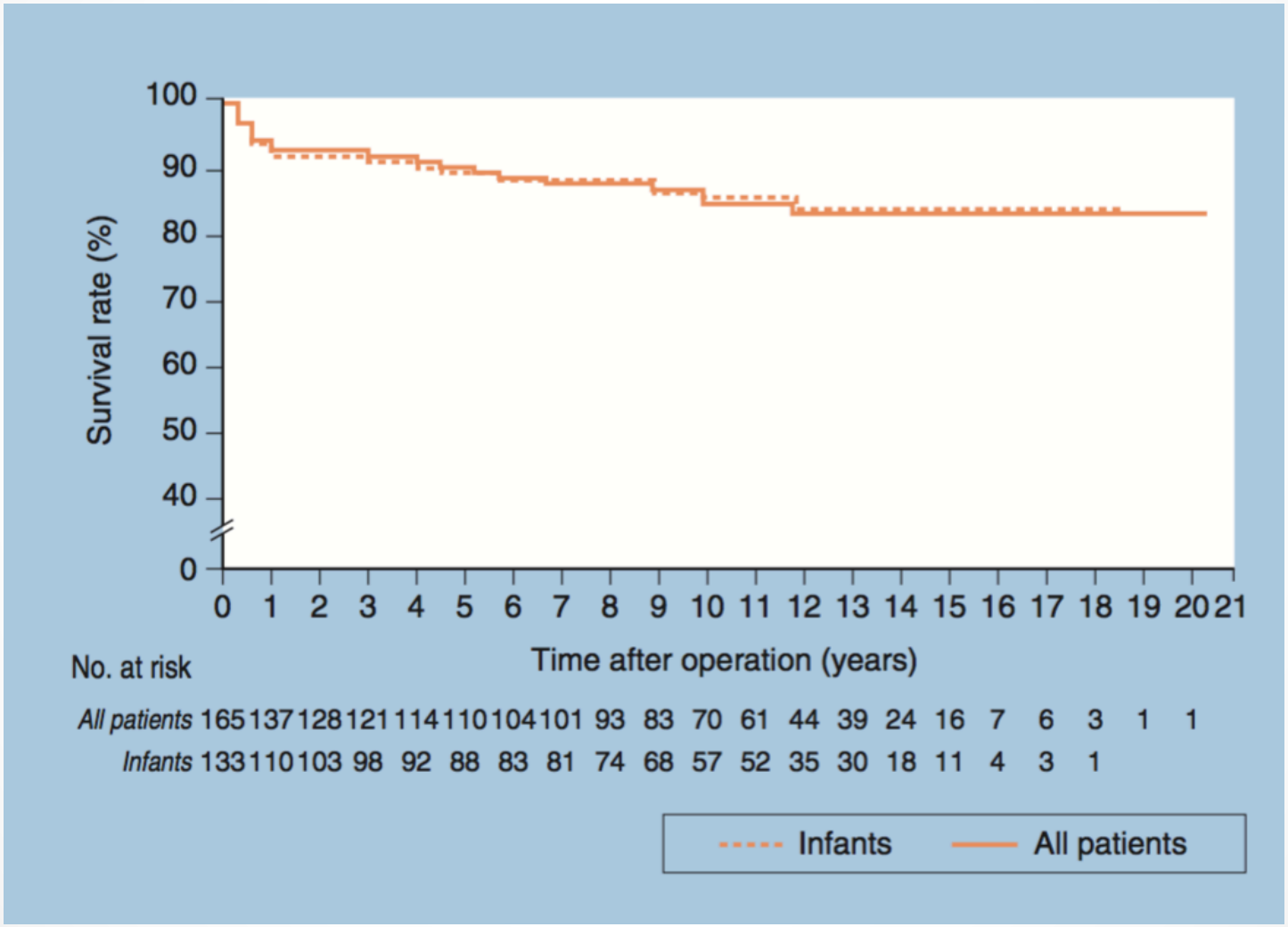

Rajasinghe et al. JTCS 1997

COMPLICATIONS

- Dysfonction voie droite
- Sténose branches pulmonaires
- Valve troncale
- CIV résiduelle
- Dilatation aorte ascendante
- Dysfonction VG
- Arythmies
-

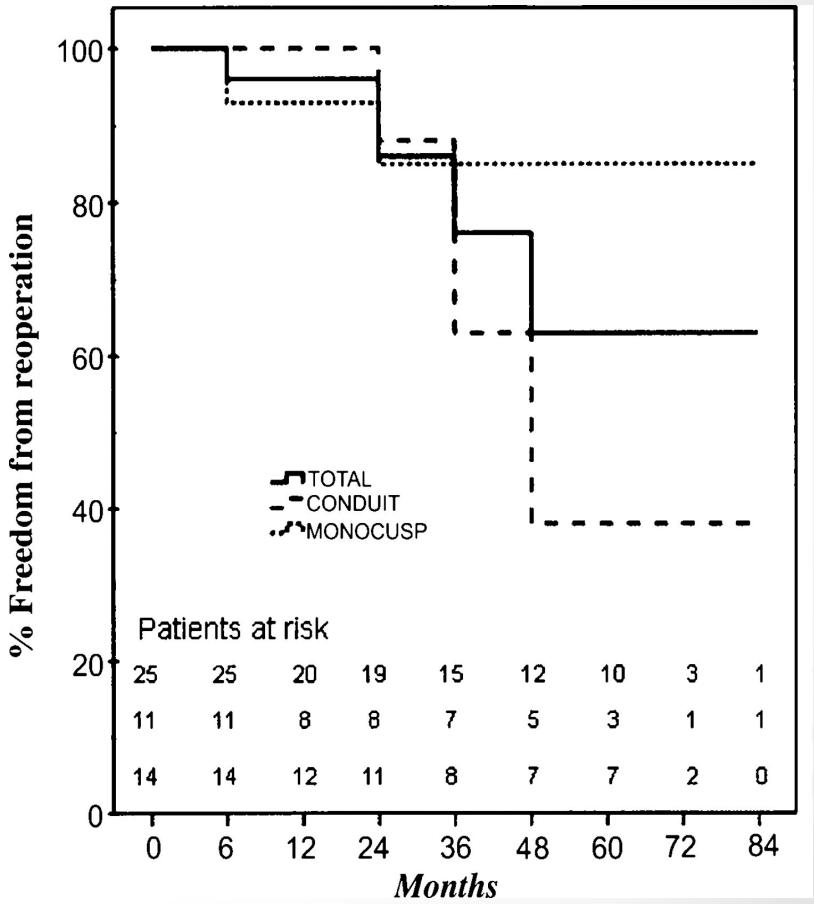

Raisky et al. EJCTS 2009

VALVULATION PERCUTANEE

Clinical and Hemodynamic Outcomes up to 7 Years After Transcatheter Pulmonary Valve Replacement in the US Melody Valve Investigational Device Exemption Trial

John P. Cheatham, MD; William E. Hellenbrand, MD; Evan M. Zahn, MD; Thomas K. Jones, MD; Darren P. Berman, MD; Julie A. Vincent, MD; Doff B. McElhinney, MD

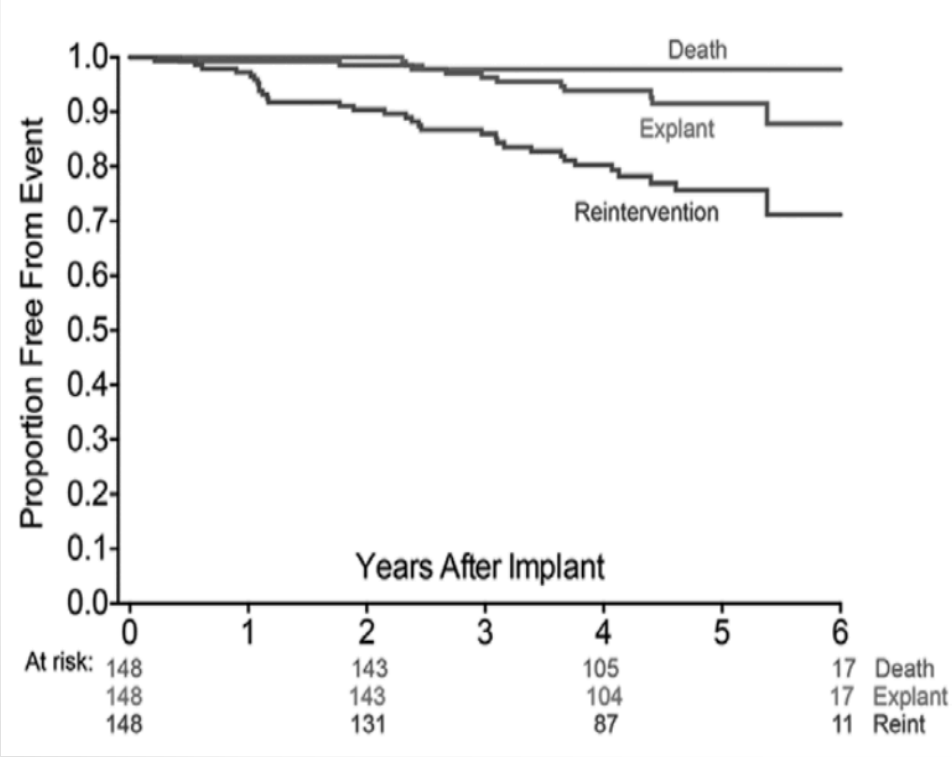

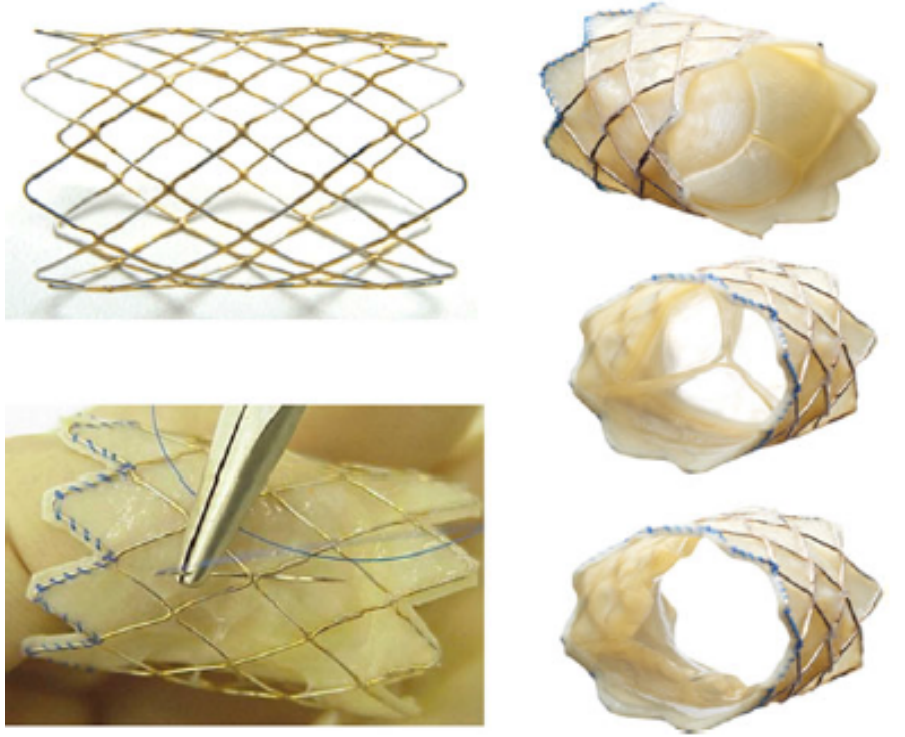

MELODY VALVE

Cheatham et al. Circulation 2015

VALVULATION PERCUTANEE

Transcatheter Pulmonary Valve Replacement With the Edwards Sapien System

The Toronto Experience

William M. Wilson, MBBS,* Lee N. Benson, MD,† Mark D. Osten, MD,* Ashish Shah, MD,* Eric M. Horlick, MDCM*

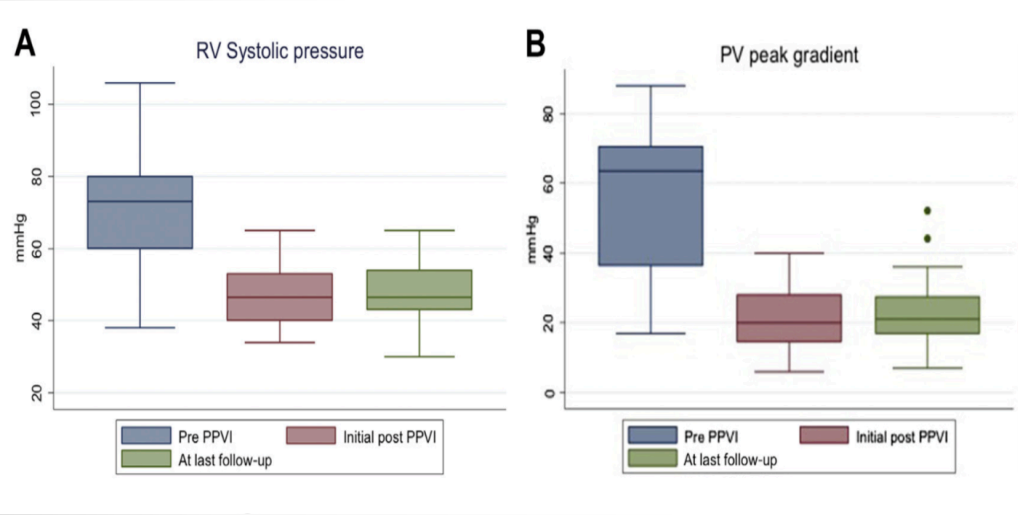

SAPIEN VALVE

Wilson et al. JACC 2016

ENDOCARDITE VALVE MELODY

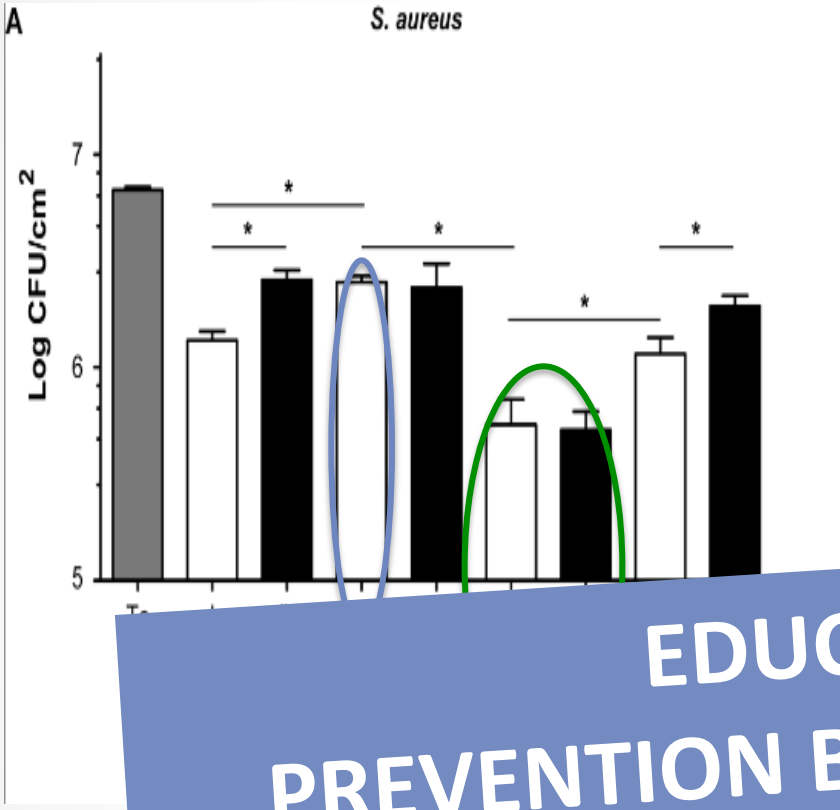

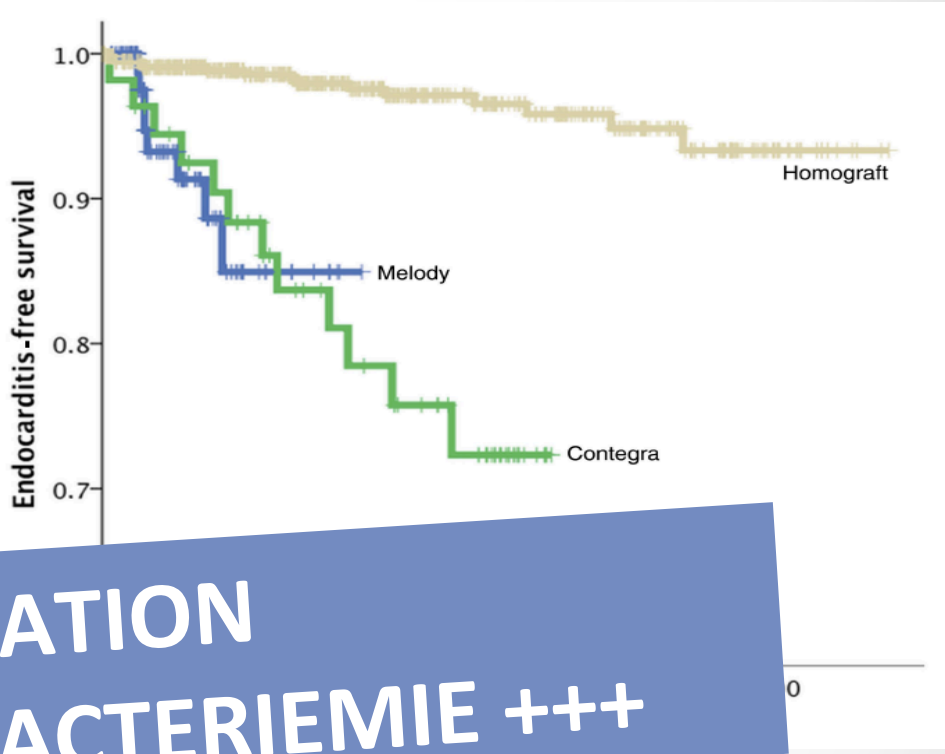

EDUCATION
PREVENTION BACTERIEMIE +++

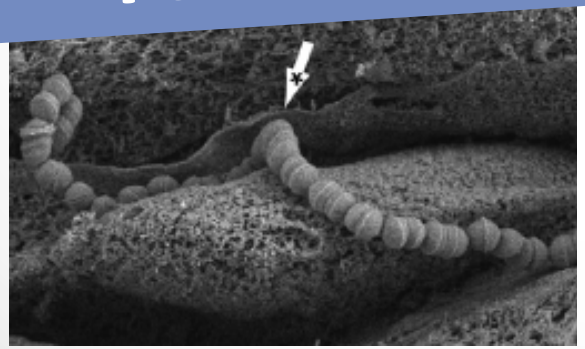

Substrat valvulaire - VJB

Malekzadeh-Milani et al. JCTS 2014
Van Dijck et al. Heart 2014
Jalal et al. IJC 2015

PERSPECTIVE

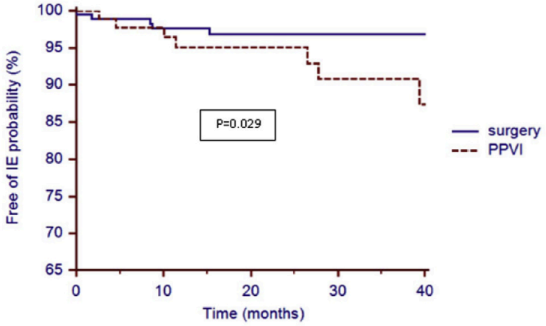

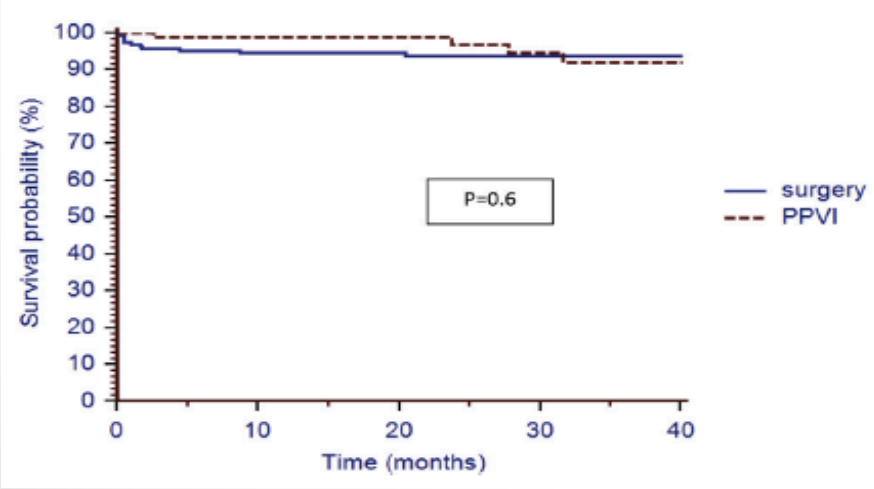

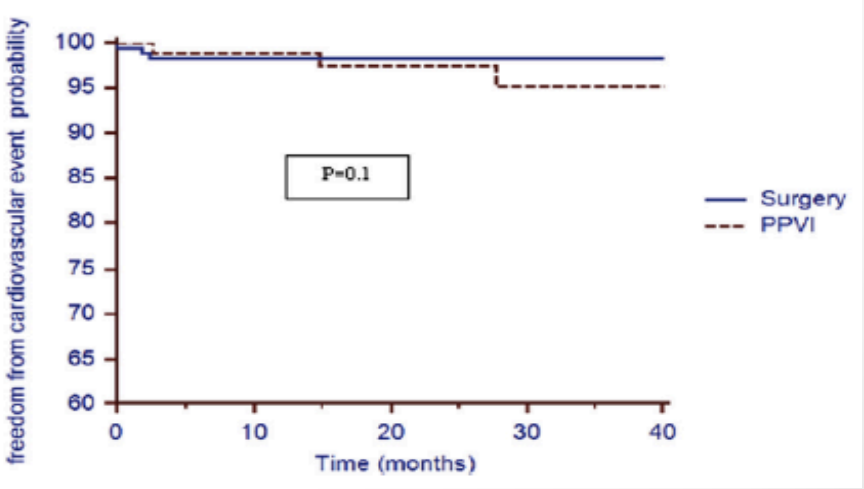

Conclusion

- Cardiopathie à sang mélangé
- Evaluation lésions associées
- Réparation chirurgicale avant 1 mois
- Réintervention sur la voie d'éjection droite
- Techniques percutanées