COARCTATION AORTIQUE

CHU Bordeaux
Service de chirurgie cardio-vasculaire, Pr. Roques
Alexandre Metras

DEFINITION

Rétrécissement congénital de l'aorte isthmique
Après la naissance de l'ASCG et le canal / ligament artériel

EXAMEN CLINIQUE NEONATAL SYSTEMATIQUE

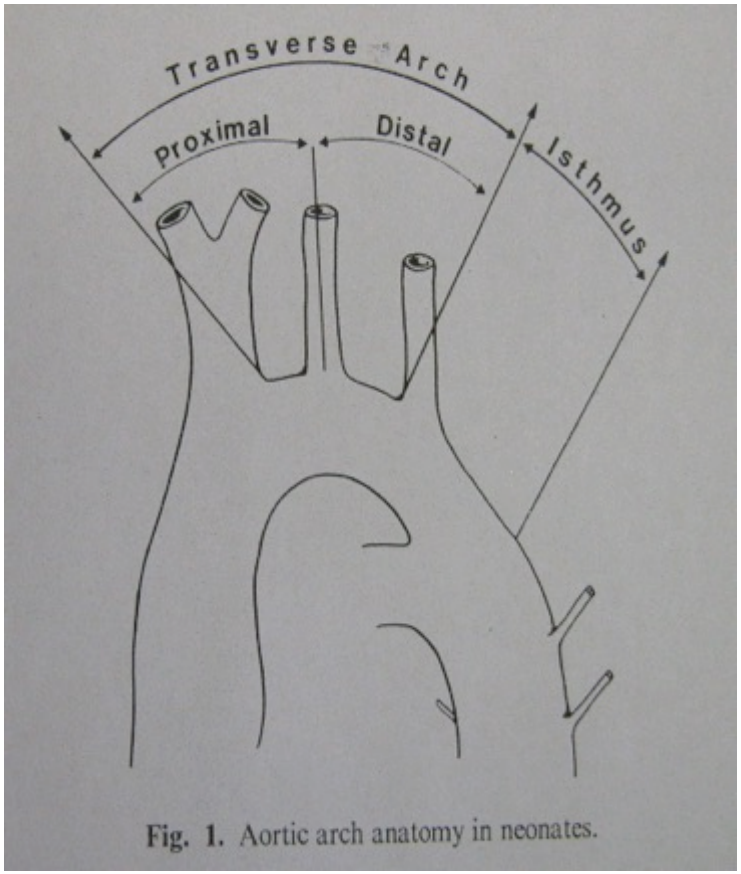

Fig. 1. Aortic arch anatomy in neonates.

Classification :
Néonatale
Du grand enfant/Adulte

SYMPTOMATIQUE - ASYMPTOMATIQUE

Hypoplasie de l'arche aortique
Canal artériel perméable
Malformations cardiaques
- CIV
- Bicuspidie aortique
- Complexes

PHYSIOPATHOGENIE

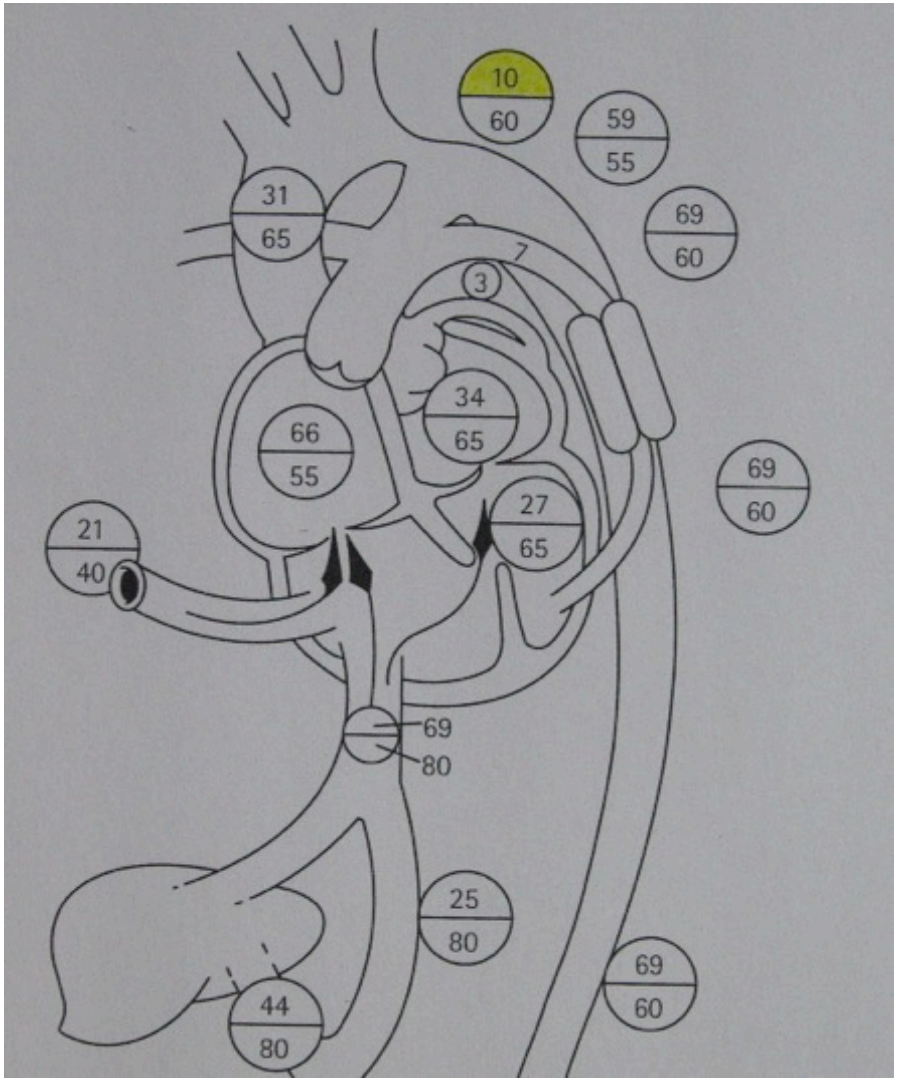

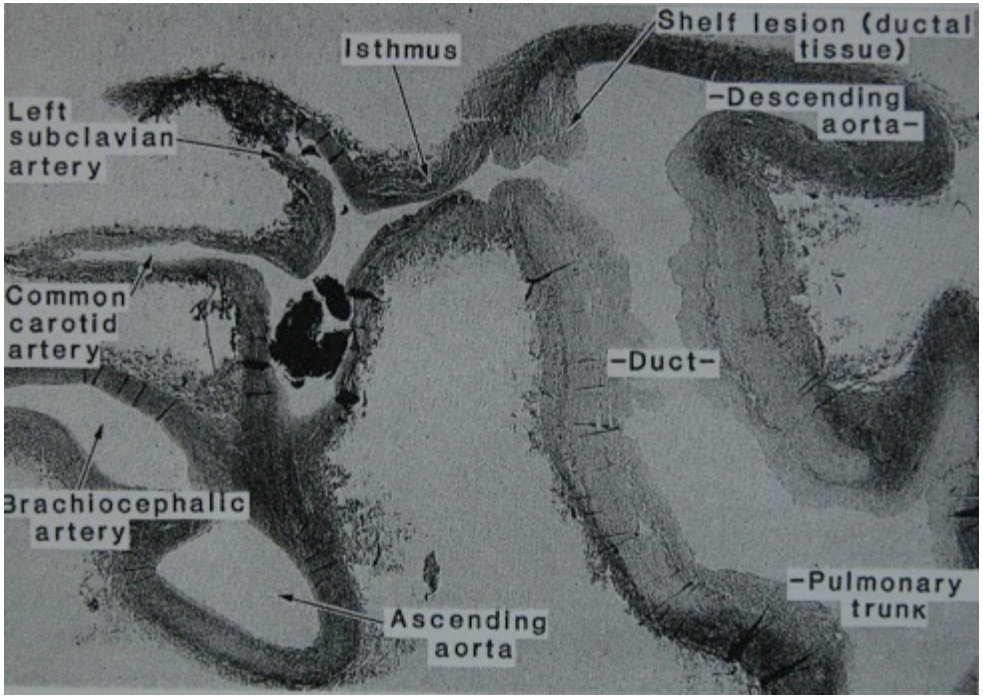

HEMODYNAMIQUE

MIGRATION TISSU DUCTAL

EVOLUTION NATURELLE et COMPLICATIONS

Circulation collatérale
Anévrysmes artériels : intracraniens – arteres Intercostales
Retentissement myocardique
Dilatation des artères coronaires

British Heart Journal, 1970, **32**, 633–640.

Natural history of coarctation of the aorta

Maurice Campbell
From the Cardiac Department, Guy's Hospital, London S.E.1, and the Institute of Cardiology, London W.1

TABLE 2 *Causes of death in coarctation of the aorta (304 necropsies)*

Causes of death	*Per cent*	*Mean age and usual decades*	
Congestive heart failure	25·5	39	3rd to 5th
Not directly connected	24	47	4th to 6th
Aortic rupture	21	25	2nd and 3rd
Bacterial endocarditis	18	29	First five
Intracranial haemorrhage	11·5	29	2nd and 3rd
All cases	100	34·4 years	

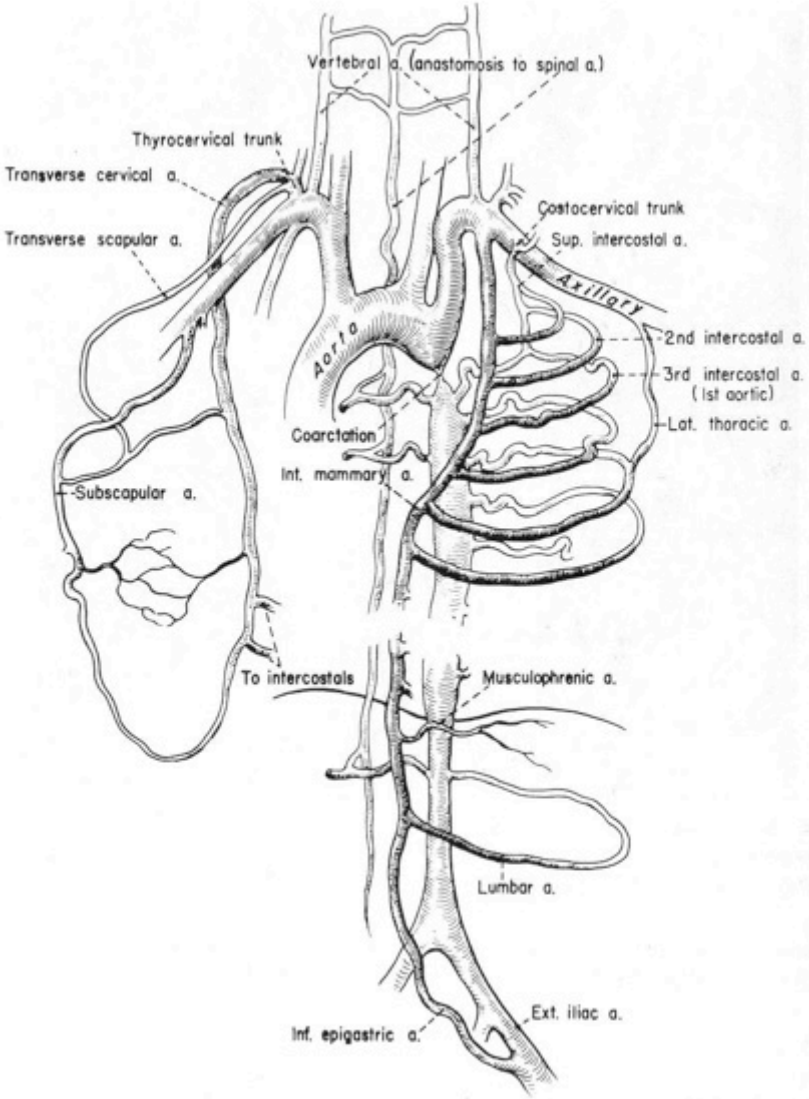

EVOLUTION NATURELLE et COMPLICATIONS

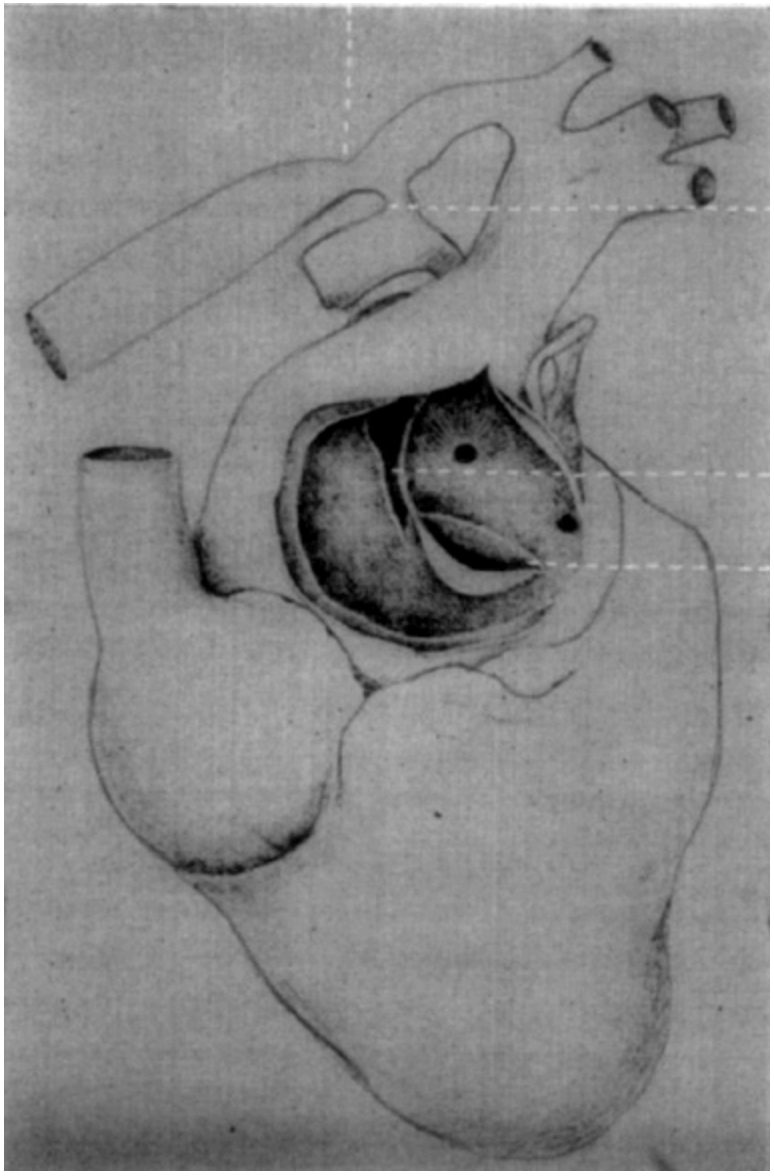

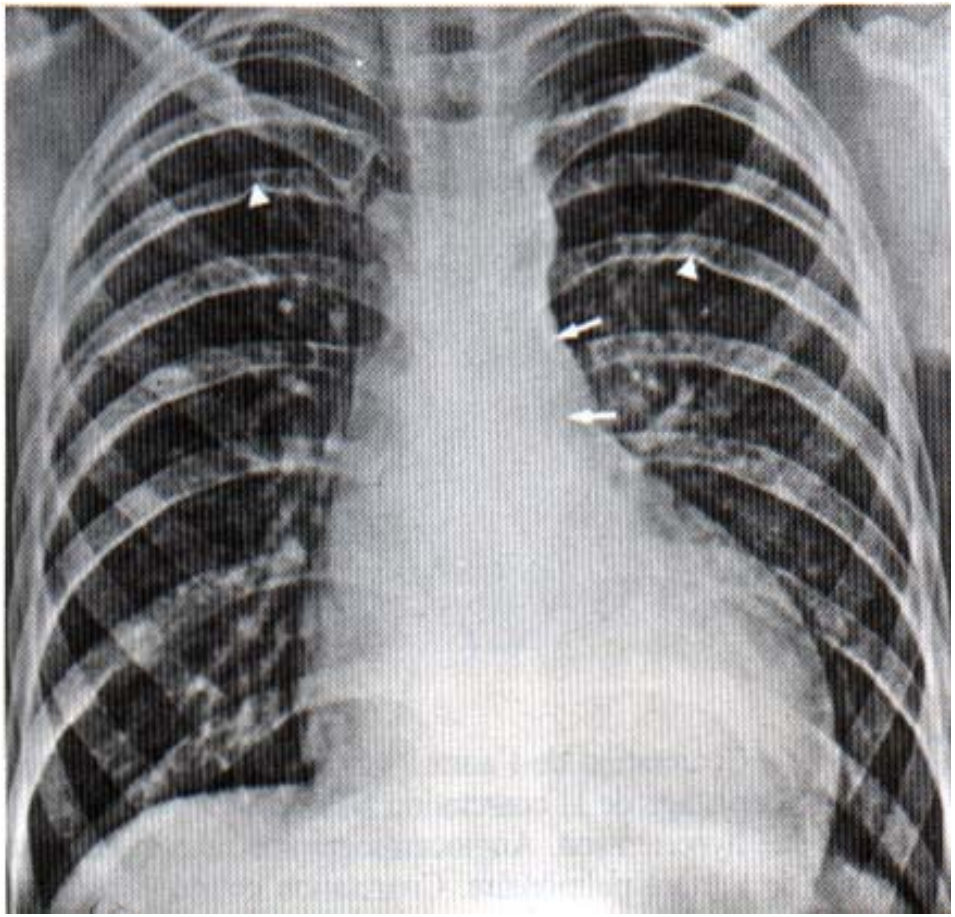

DIAGNOSTIC PARACLINIQUE

ECHOGRAPHIE TRANS-THORACIQUE

- Fait le diagnostic positif – Evaluation de la Sténose
- Recherche les lésions associées
  - Lésions de l'aorte transverse
  - Lésions intra-cardiaques – recherche de shunts
- Fonction VG
- HTAP
- Canal artériel perméable
- (Diagnostic anté-natal)

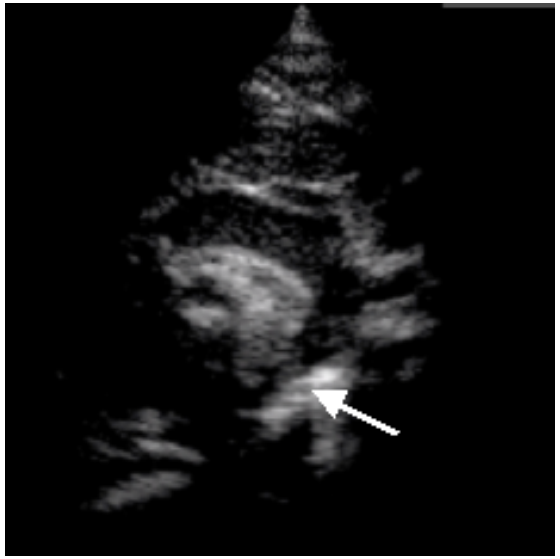

SCANNER

- Siège et étendue
- Hypoplasie
- Collatérales
- Anomalies associées

IRM

- Retentissement sur le VG
- Anomalies associées

EN PRATIQUE – FORMES CLINIQUES

FORME NEONATALE SEVERE

- Dans le 1er mois
- Insuffisance cardiaque – Oedeme pulmonaire - collapsus
- Pouls fémoraux absents
- Bas débit en aval : Acidose – Ice rénale – Enterocolite nécrotique
- Ducto-dépendance

FORME de L'ENFANT

- Insuffisance cardiaque
- Polypnée et retard de croissance
- Irritabilité – Sueurs – Difficultés d'alimentation

FORME DU GRAND ENFANT – ADULTE

- HTA
- Intolérance à l'effort
- ASYMPTOMATIQUE (COLLATÉRALITÉ +++)
- Gradient de pression, pouls diminués
- Rx du thorax : Vx intercostaux dilatés, érosion des cotes

TECHNIQUE CHIRURGICALE

HISTOIRE

Clarence CRAFOORD

Robert E. GROSS

VOIE D'ABORD

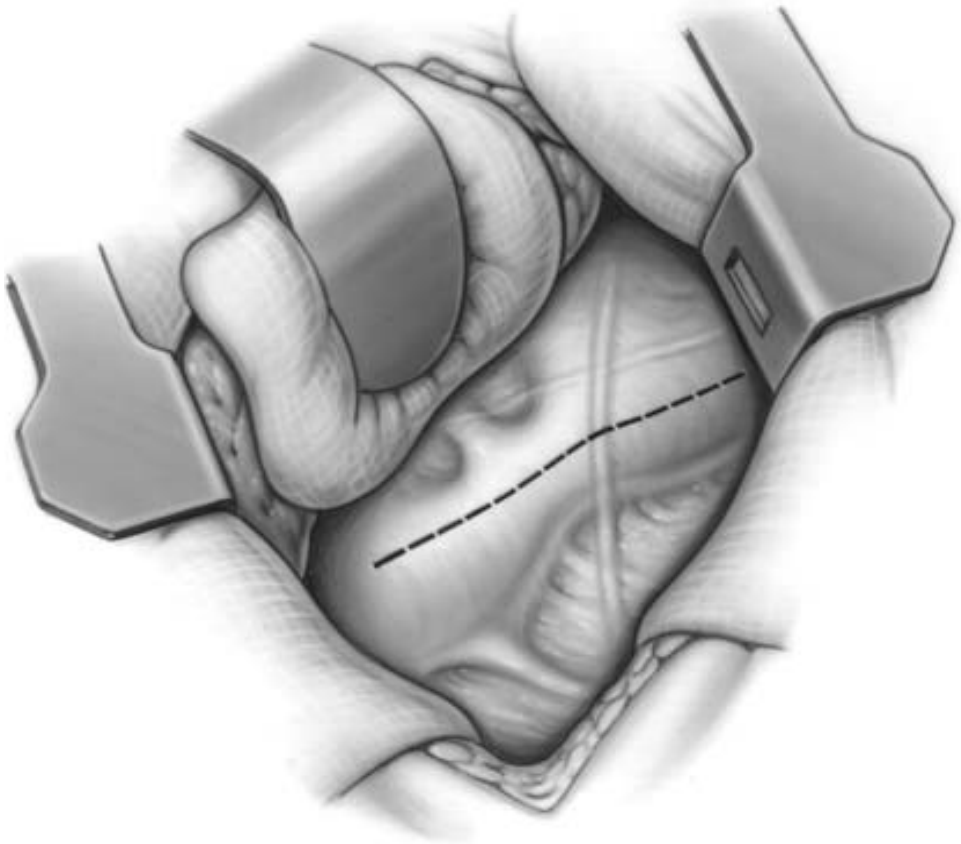

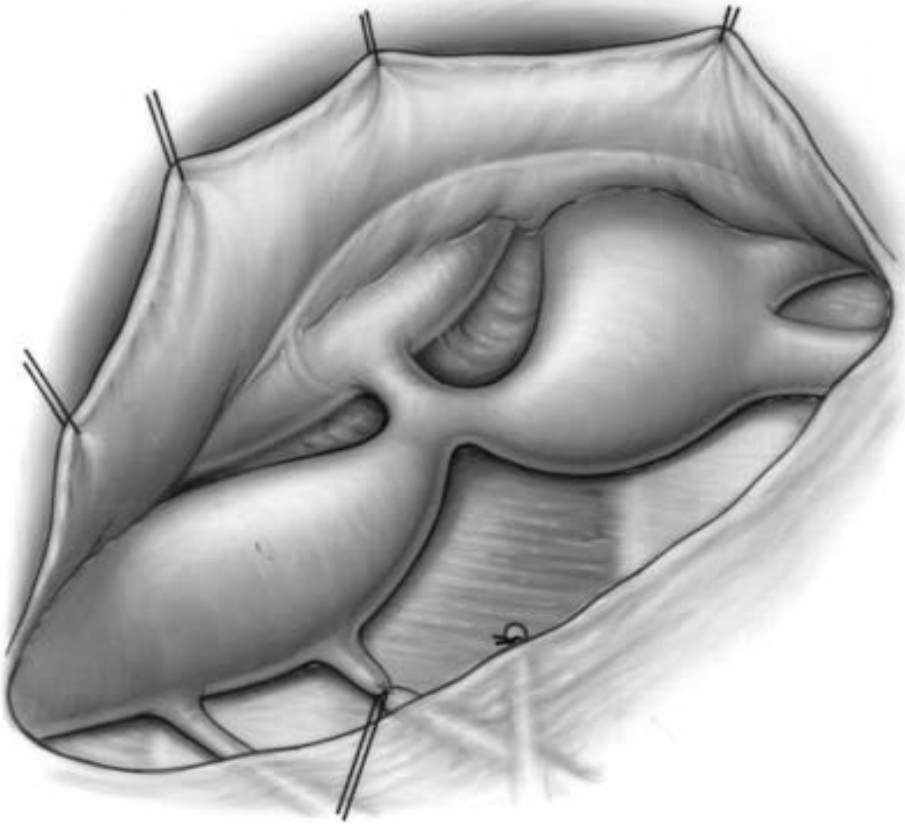

TECHNIQUE de CRAFOORD – End to End Anastomosis

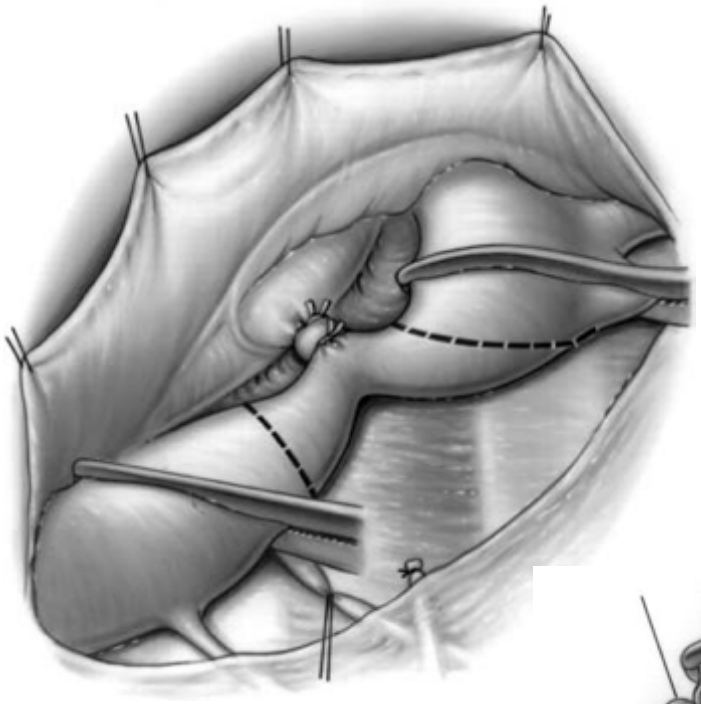

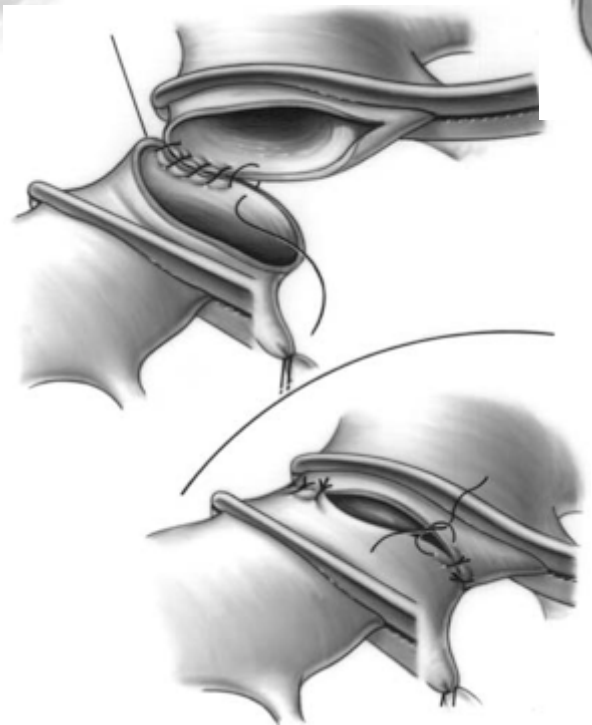

Technique de WALDHAUSEN

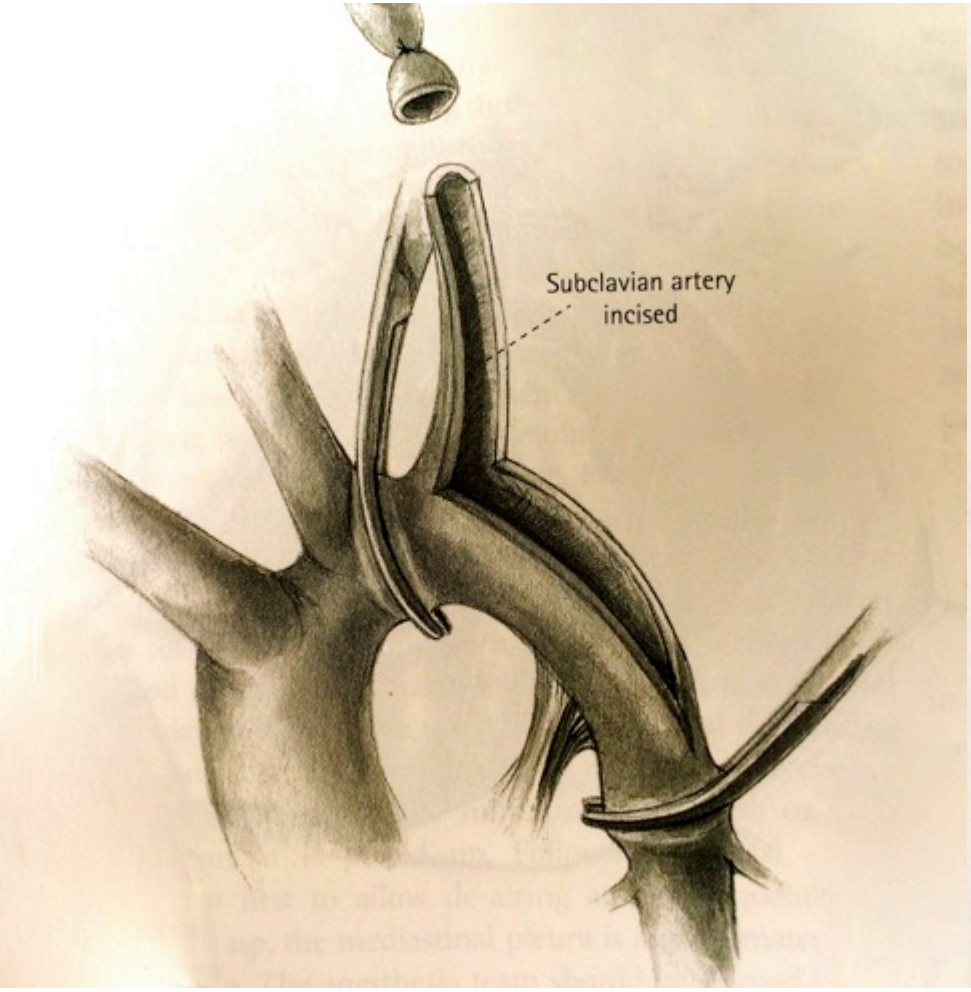

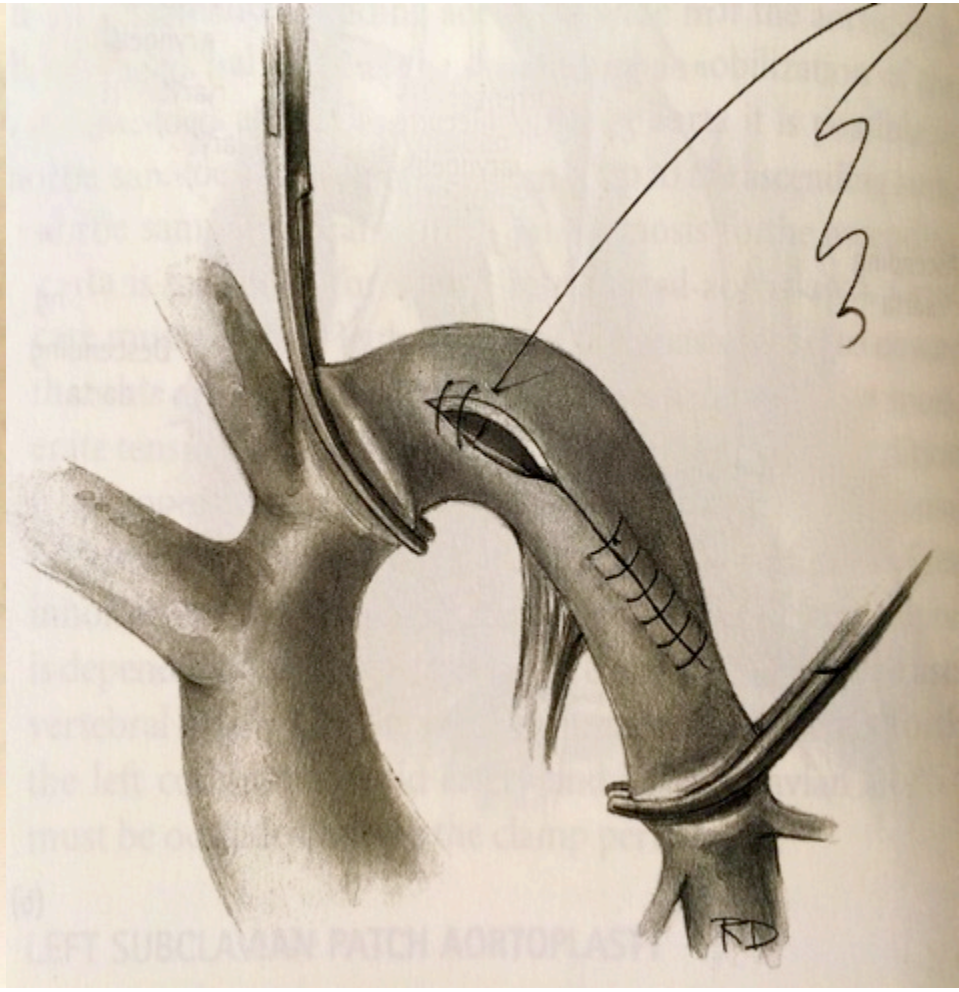

AORTOPLASTIE – PATCH SOUS CLAVIERE

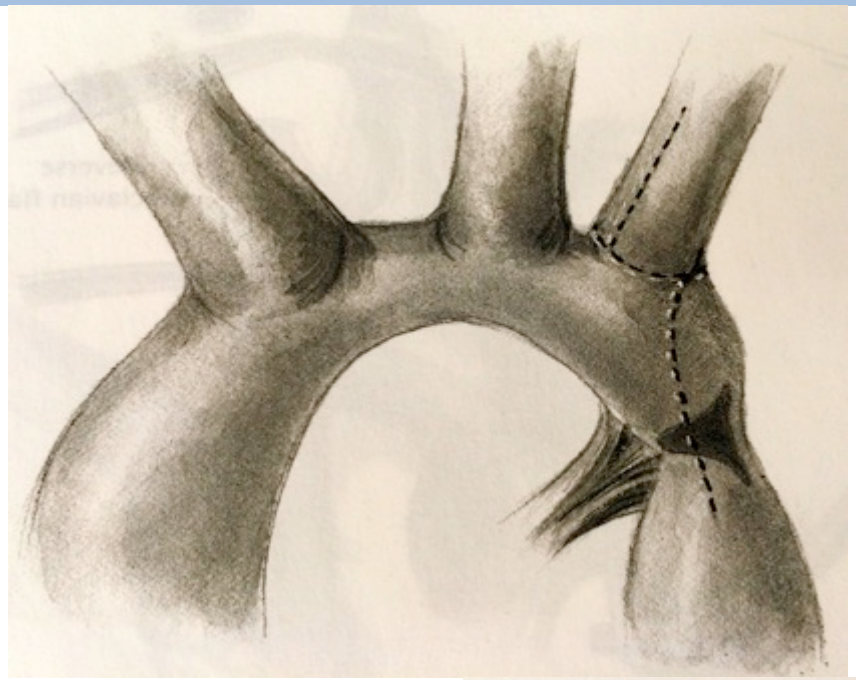

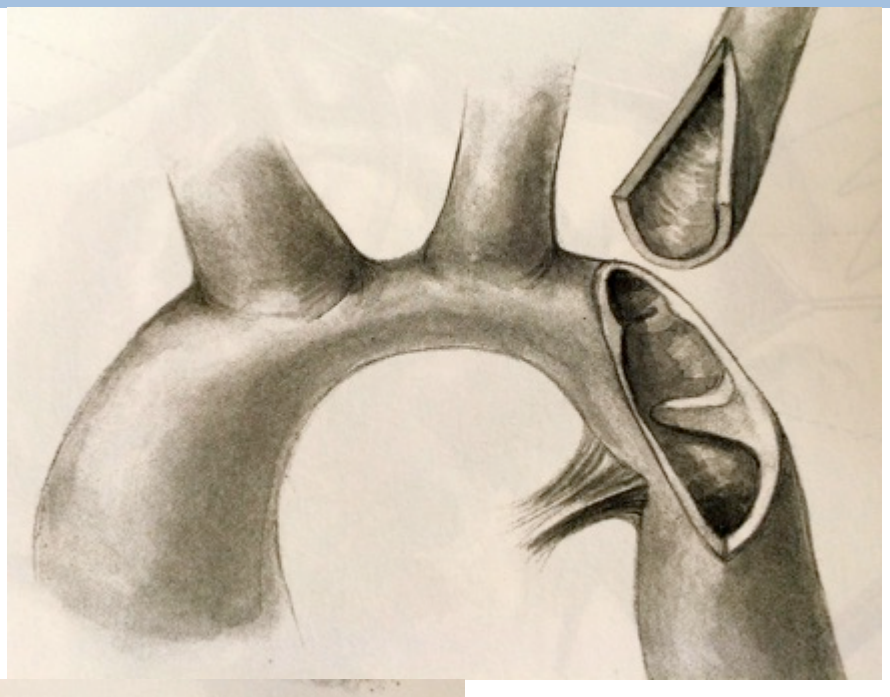

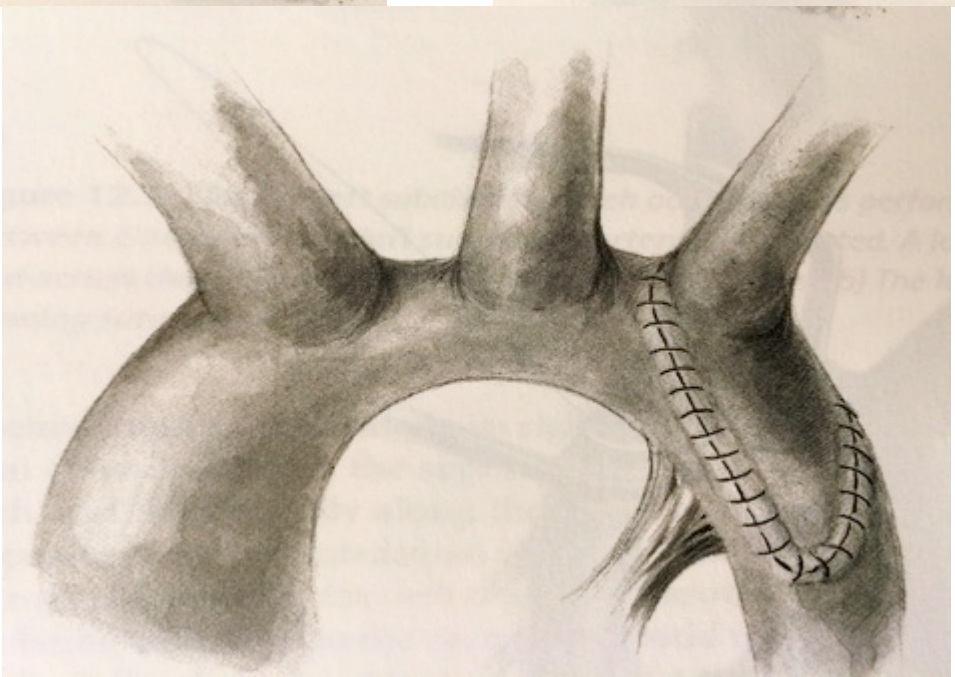

HYPOPLASIE AORTE TRANSVERSE

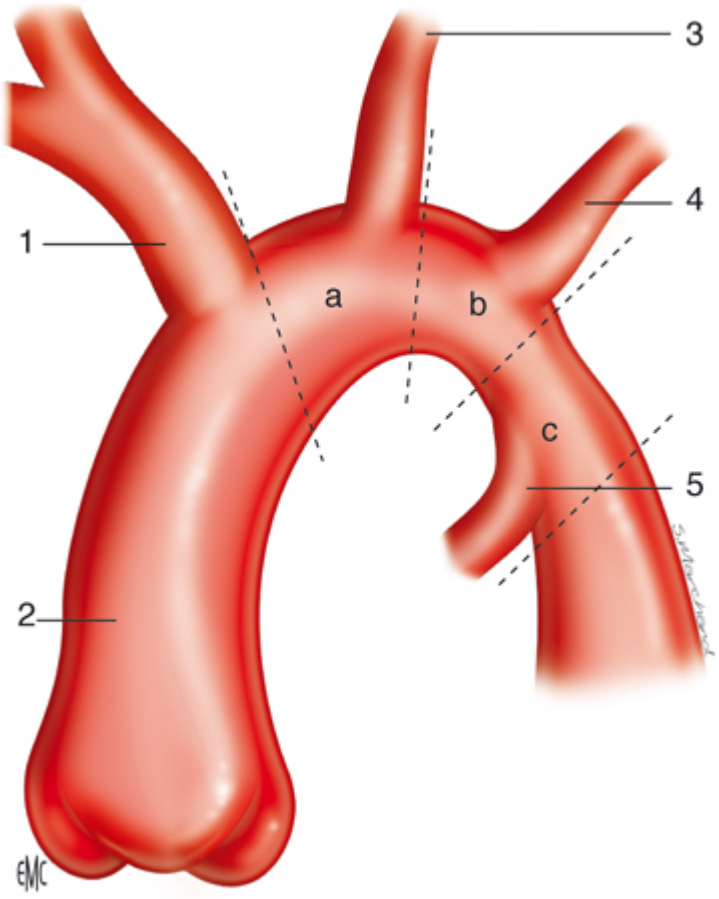

Proximal – 0,5%

Diamètre **< 60 %**

Distal – 30%

Diamètre **< 50%**

Isthme

Diamètre **< 40%**

Chez le nourrisson
< 1mm/kg + 1 mm

HYPOPLASIE AORTE TRANSVERSE – SEGMENT DISTAL

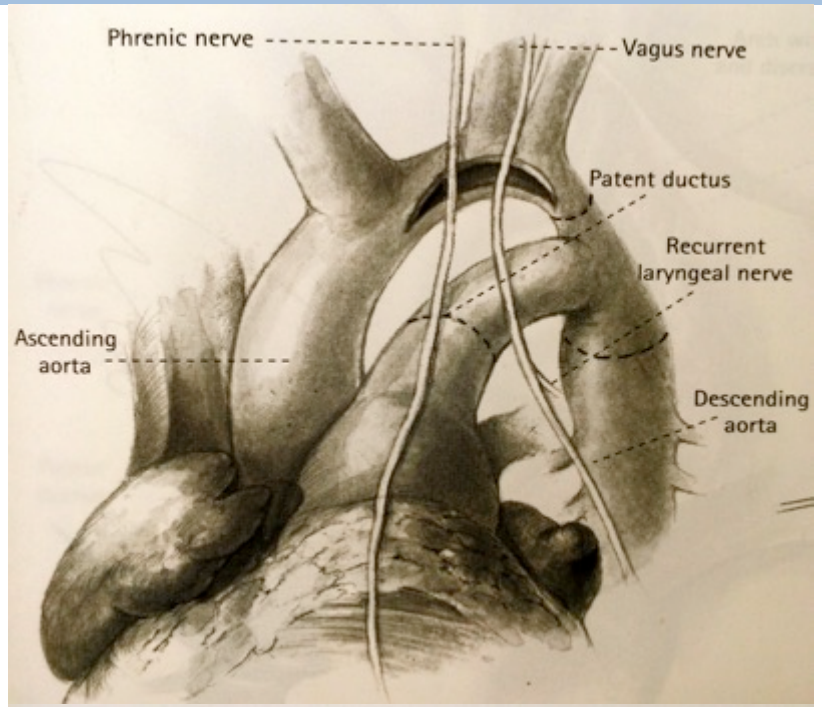

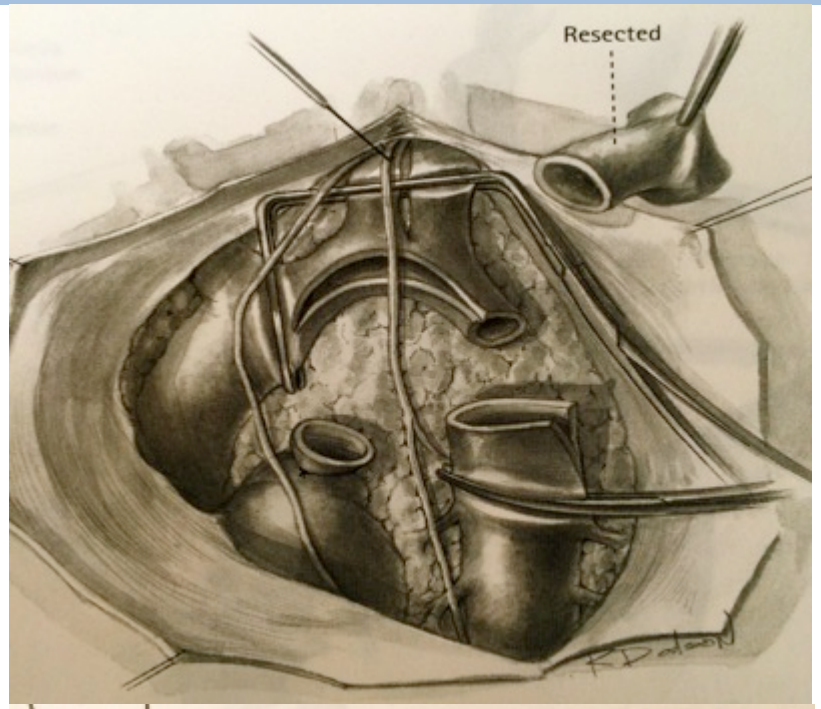

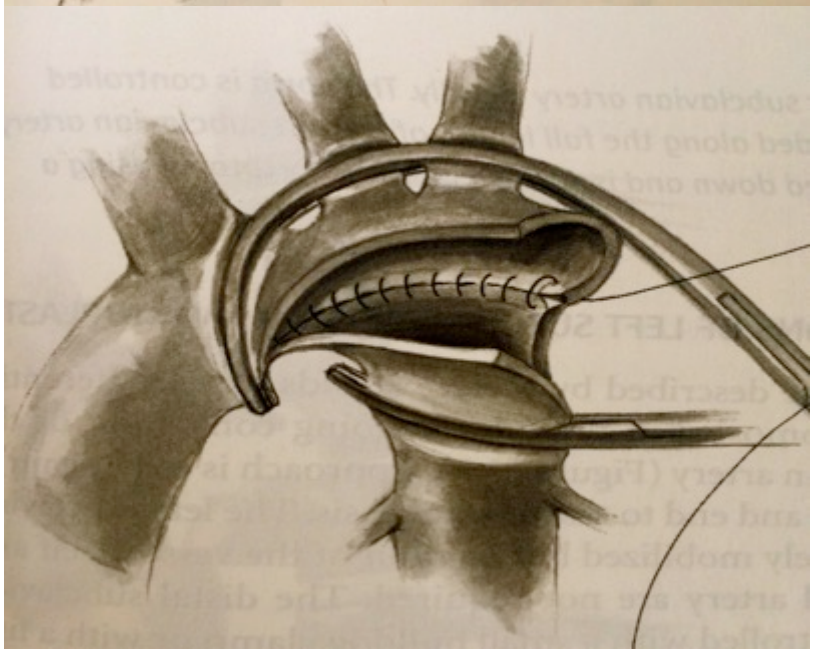

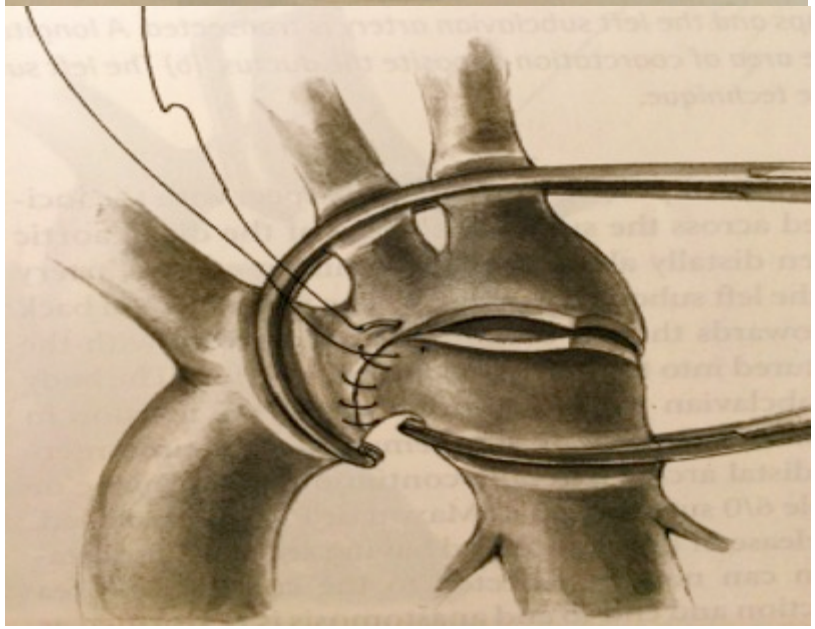

HYPOPLASIE AORTE TRANSVERSE – SEGMENT DISTAL

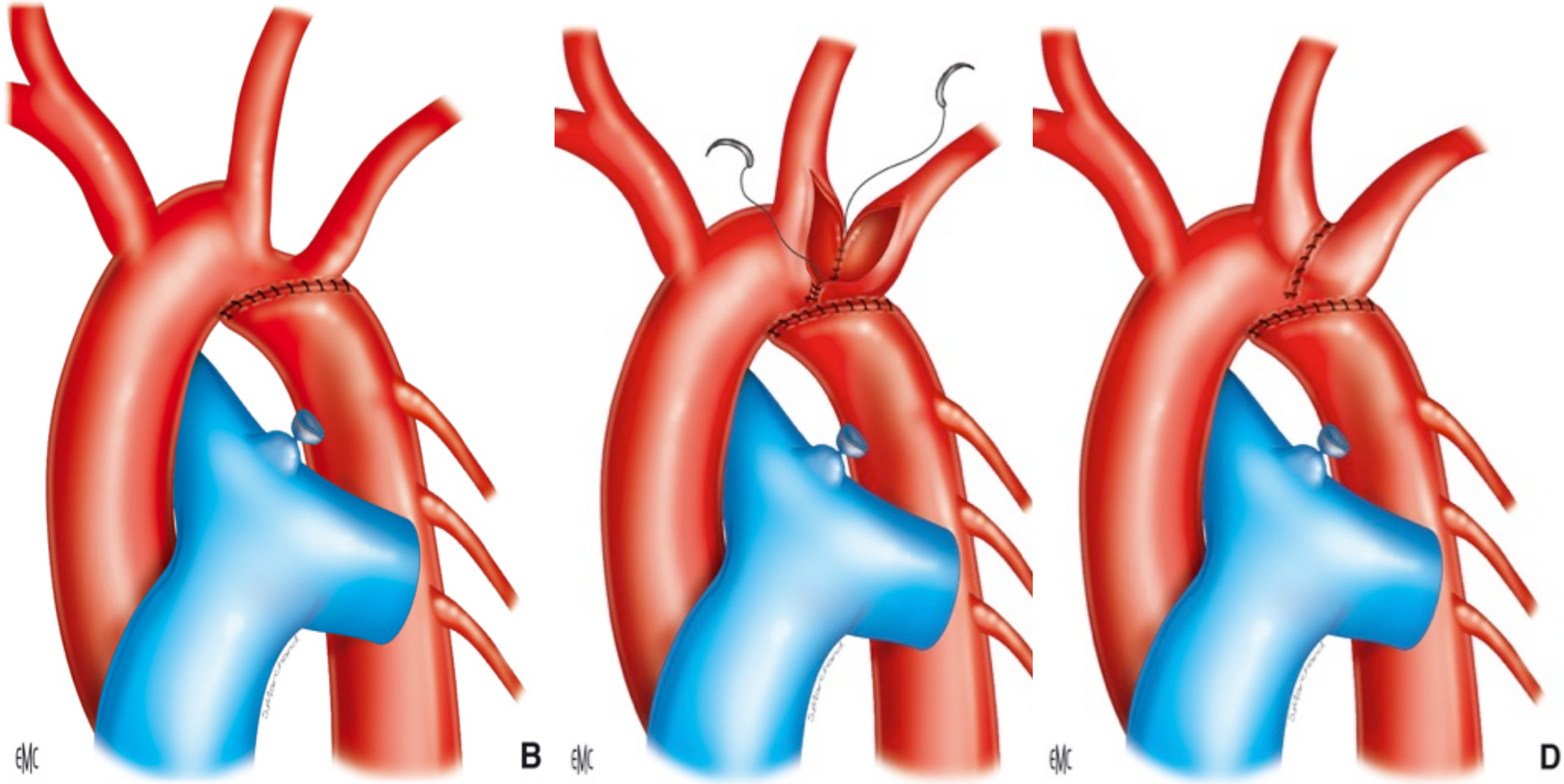

AORTOPLASTIE AVEC PATCH INVERSE de SOUS CLAVIERE

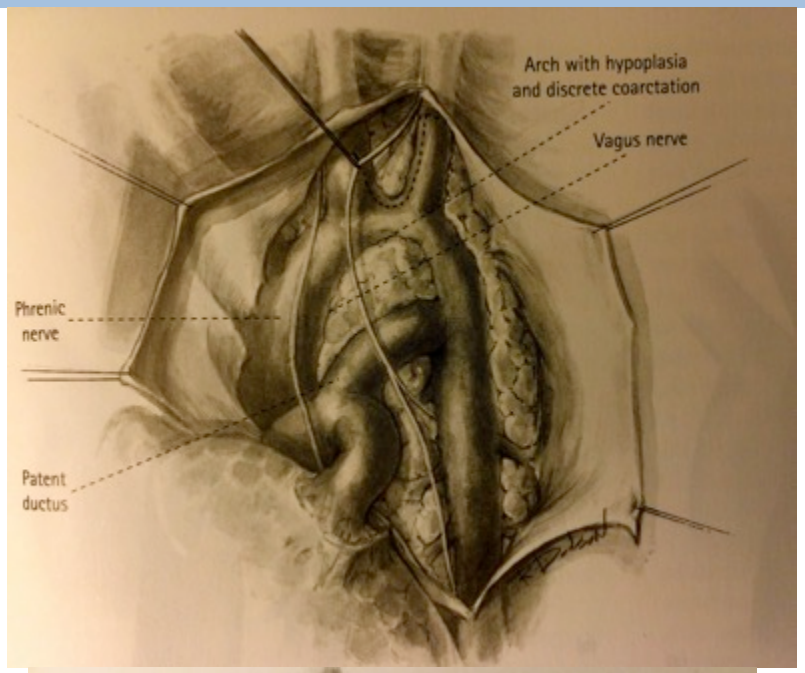

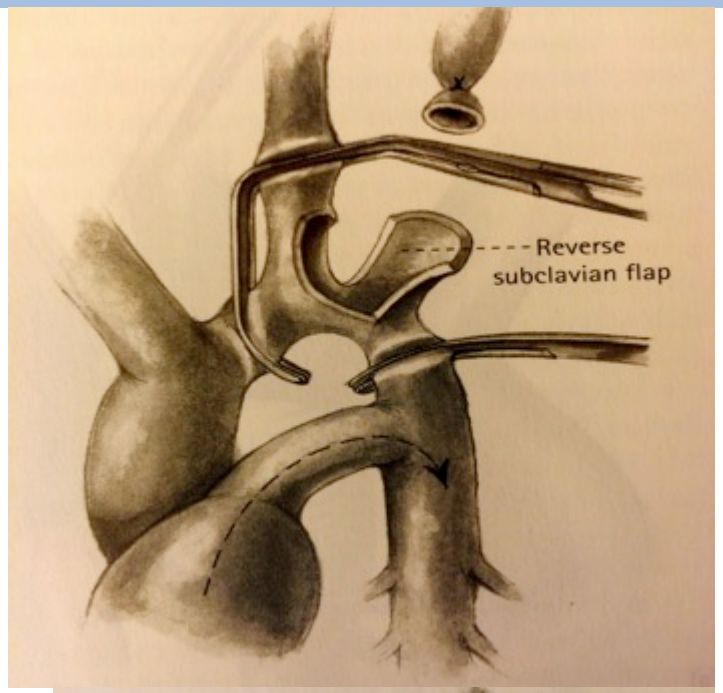

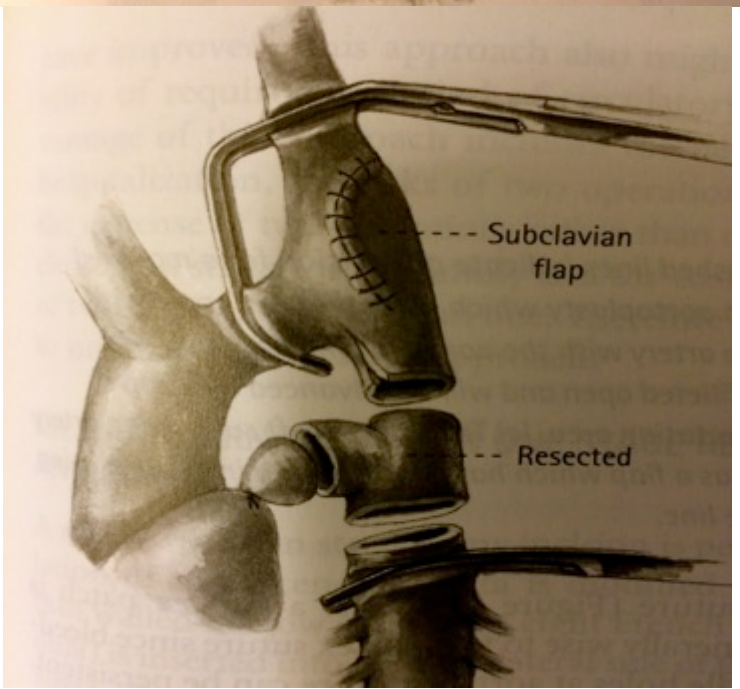

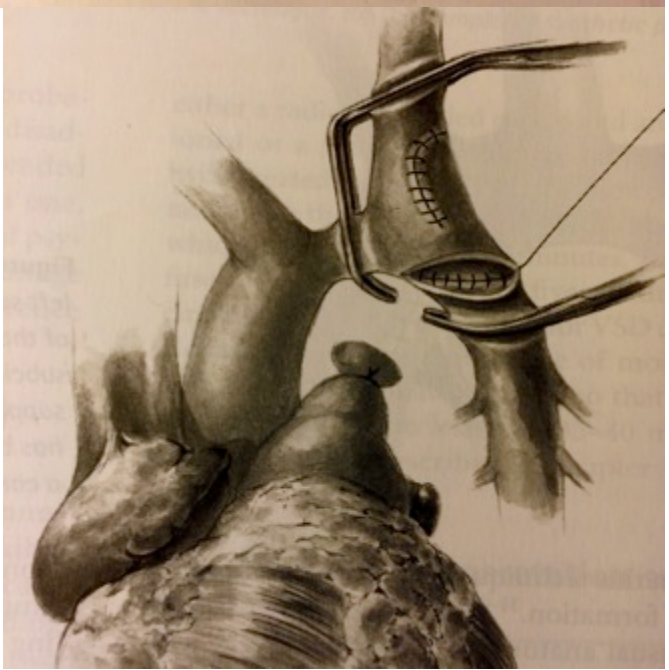

MATERIEL SYNTHETIQUE

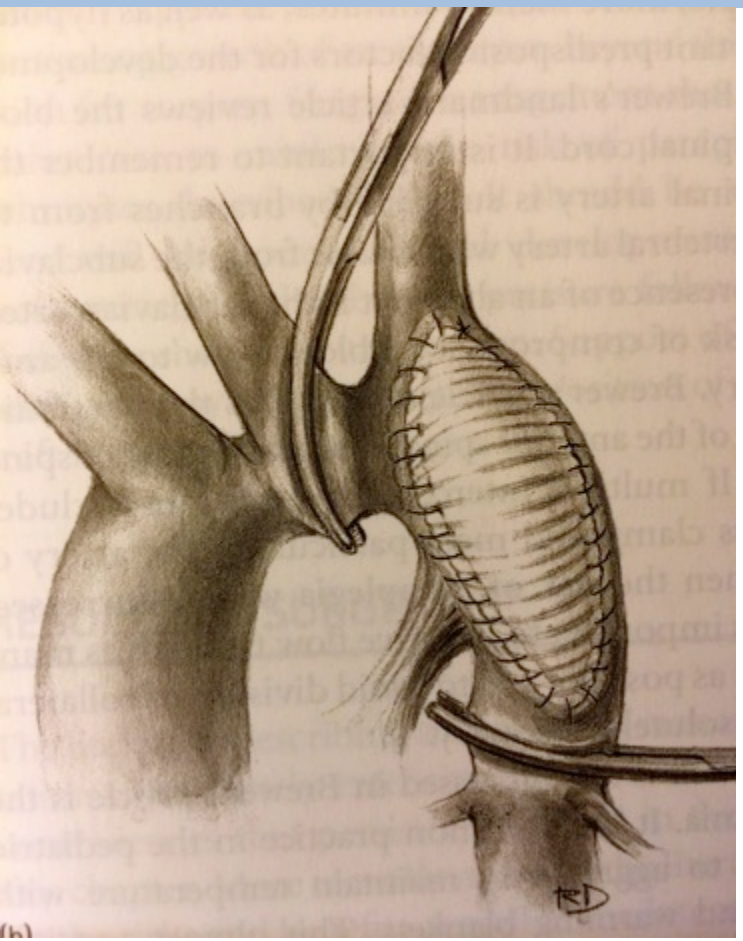

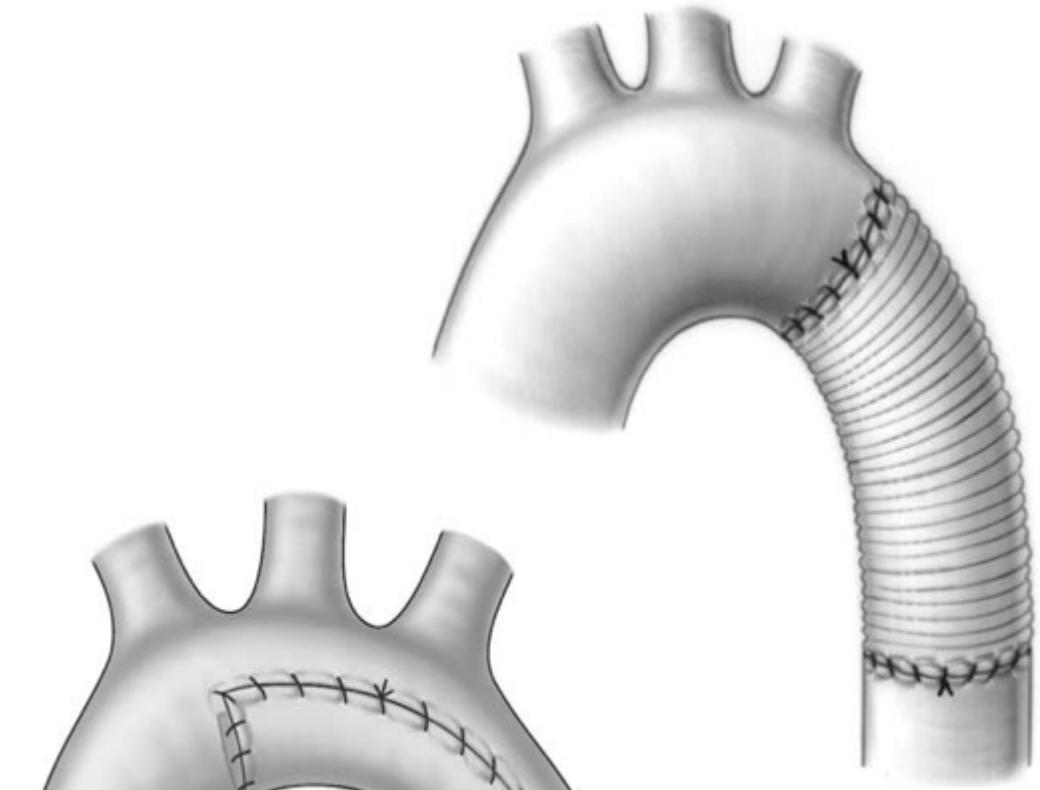

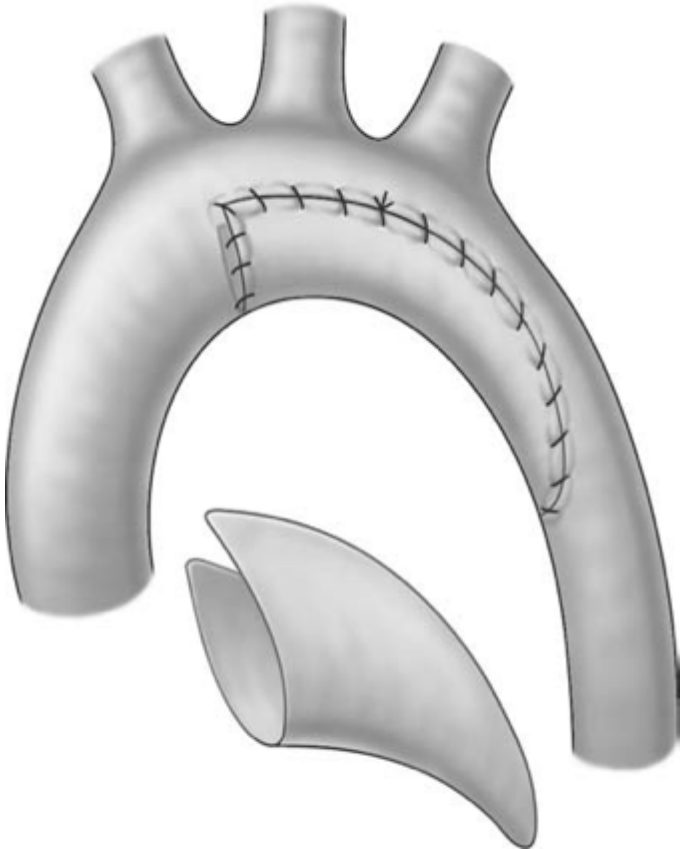

CURE DE COARCTATION AVEC CEC – Thoraco gauche

Chez le grand enfant en cas de **FAIBLE COLLATERALITE** ➔ Paraplégie
Pression inf à **50 mmHg** en aval du clan

SHUNT PASSIF – CEC Périph – CEC Centrale

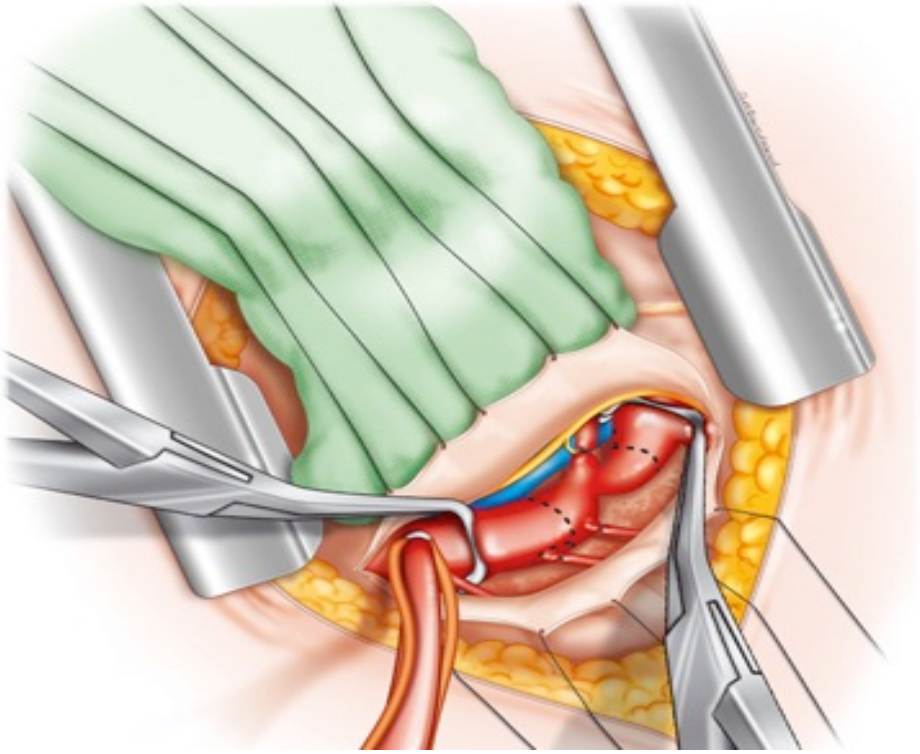

VOIE D'ABORD ANTERIEURE - STERNOTOMIE

INDICATIONS

Hypoplasie du segment **PROXIMAL**

Hypoplasie du segment distal avec **tronc bovin**

Cure de Coarctation + **LESION ASSOCIEE** (CIV, TGV, Shone)

Truncus Arteriosus (type A,B, C)

Canulation artérielle :

AORTIQUE puis dans le TABC

INDIRECTE dans le TABC (tube de PTFE)

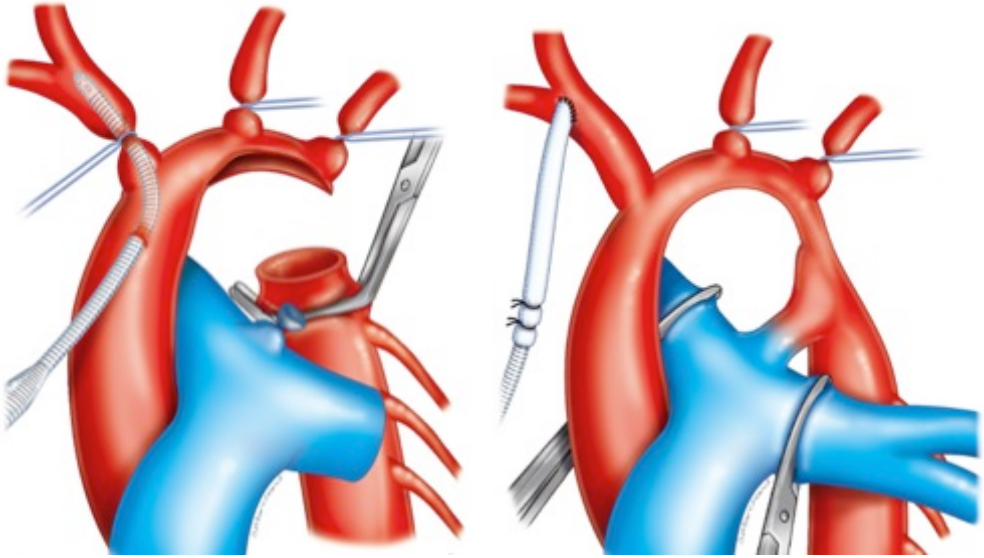

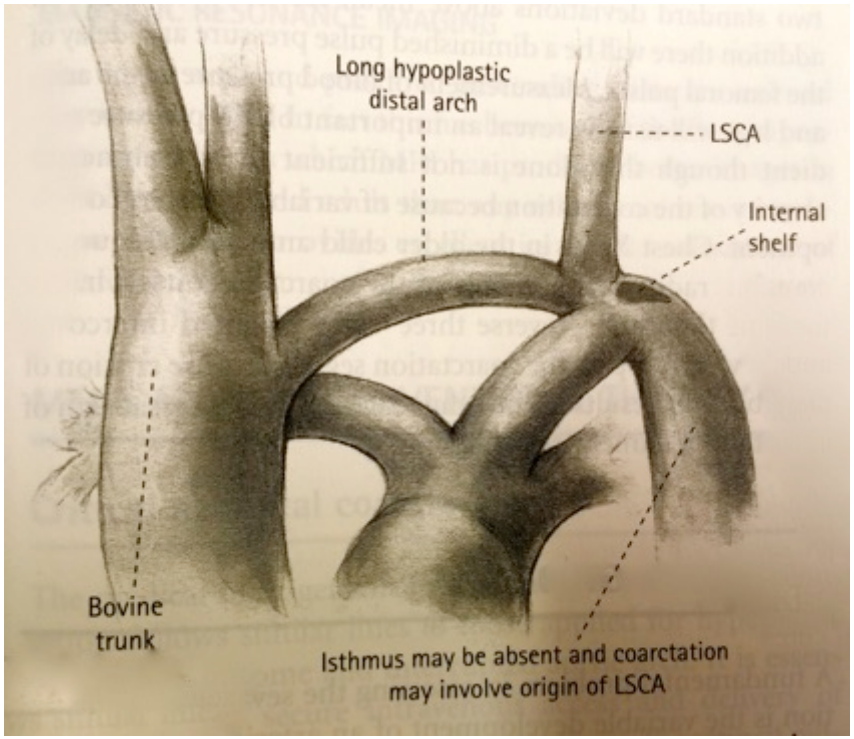

CoA + CIV : Traitement en 1 ou 2 temps +/- approche hybride

INDICATION CHIRURGICALE

Forme symptomatique du nouveau-né sévère, précoce

Mesures de réanimation

PGE1 + inotropes + ventilation artificielle

➔ **CHIRURGIE**

Forme atténuée du nouveau-né

Traitement défaillance cardiaque

➔ Bonne réponse : attendre 2 à 3 mois

➔ Réponse médiocre : chirurgie rapide

Forme asymptomatique

Risques : Mortalité - Resténose

➔ Entre 3 et 6 mois

Forme de l'Adulte et du grand Enfant

Symptomatique : HTA, Insuffisance cardiaque

Gradient membre sup – inf > 20 mmHg

COMPLICATIONS PRECOCES

Hémorragie

Grands enfants, Adultes : COLLATERALITE

HTA paroxystique

jusqu'à 30%

Paraplégie

Entre 0,4 – 1,5%
Durée de clampage
Collatéralité

Ileus réflexe

Insuffisance rénale

Chylothorax

Paralysie récurrentielle

COMPLICATIONS TARDIVES

RECOARCTATION

Distinguer : **RÉSIDUELLE – RECIDIVE**

Peut résulter d'un défaut technique

Pas de technique initiale ayant montré une réelle différence

Indication à traiter si gradient supérieur à 20-30 mmHg…. A discuter

Chirurgie ou Angioplastie possible :

pas de surdilatation ; pas de cutting balloon ; pas de stent si possible

Hypertension résiduelle

patients opérés trop tard

Formation d'Anevrysmes

Après utilisation de patch/tube

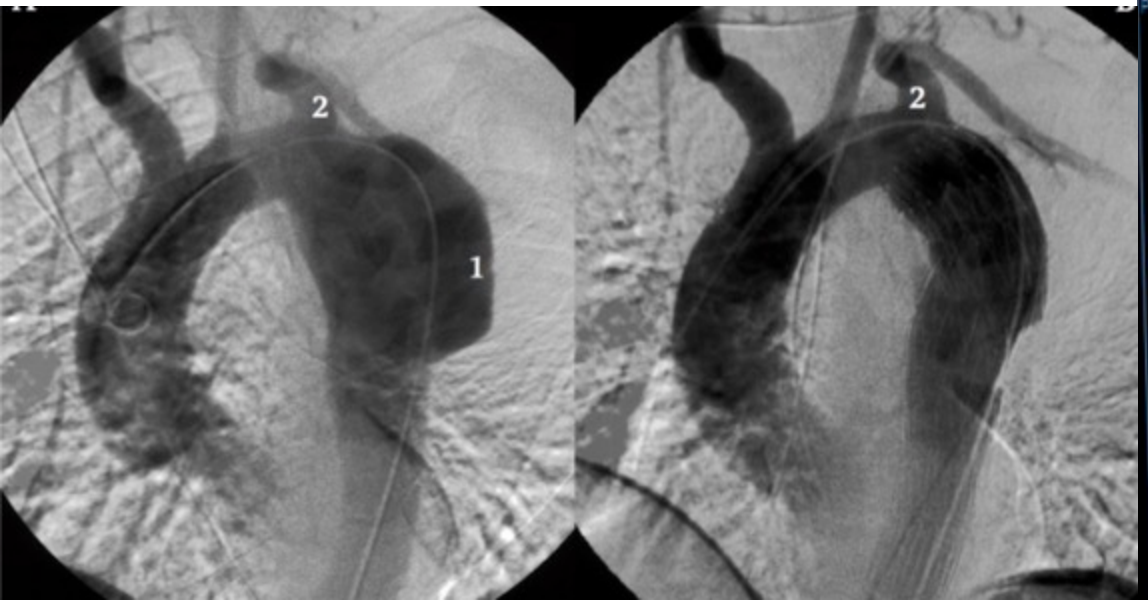

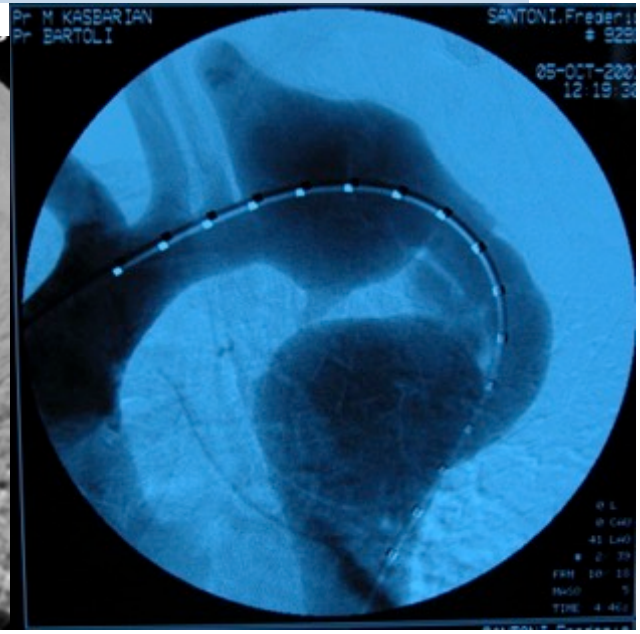

RESULTATS CHIRURGIE

EACTS Congenital Database (1981-2011)

	n	CEC	Mortalité
Resection End-to-end	555	21	0,5%
Extended End-to-End	671	36	0,6%
Patch sous-claviere	54	0	1,85%
Patch Aortoplastie	91	36	1%

NX-NES

	n	CEC	Mortalité
Resection End-to-end	411	29	0,24%
Extended End-to-End	246	29	0%
Patch sous-claviere	19	0	0%
Patch Aortoplastie	151	34	0%

ENFANTS

	n	CEC	Mortalité
Resection End-to-end	9	0	0%
Extended End-to-End	14	7	0%
Patch sous-claviere	0		
Patch Aortoplastie	10	8	0%
Prothese	60	25	0%

ADULTES

RESULTATS CHIRUGIE A LONG TERME

TABLE 1. Clinical Follow-up and Survivorship

Age (yr)	Initial patients (*n*, %)		Perioperative death/Lost to follow-up (*n*)	Late follow-up (*n*)	Reoperation for recurrent coarctation (*n*, %)*		Hypertension at late follow-up (*n*, %)†		Survivorship (%)
<1	31	5	2/2	27	7	26	2	7‡	93
1–4	39	6	0/2	37	2	5	6	16	95
5–9	109	17	2/19	88	1	1	14	16	96
10–14	108	17	2/7	99	3	3	19	19	91
15–19	94	14	2/10	82	1	1	25	30	88
20–24	72	11	1/5	66	0	0	29	44	81
25–29	60	9	2/3	55	1	2	16	29	77
≥30	133	21	6/10	117	2	2	34	29	59
Total	646	100	17/58	571	17	3	145	25	82 (overall)

Age de la réparation est le facteur prédictif à long terme de survie

Chirurgie devrait être réalisée avant la 1ere année si possible

Coronaropathie est la cause la plus fréquente de décès à long terme

L'age de l'intervention est le meilleur facteur prédictif d'hypertension artérielle à terme

Coarctation of the aorta. Long-term follow-up and prediction of outcome after surgical correction. M Cohen, et al. Circulation, 1989

TRAITEMENT ENDOVASCULAIRE ADULTE

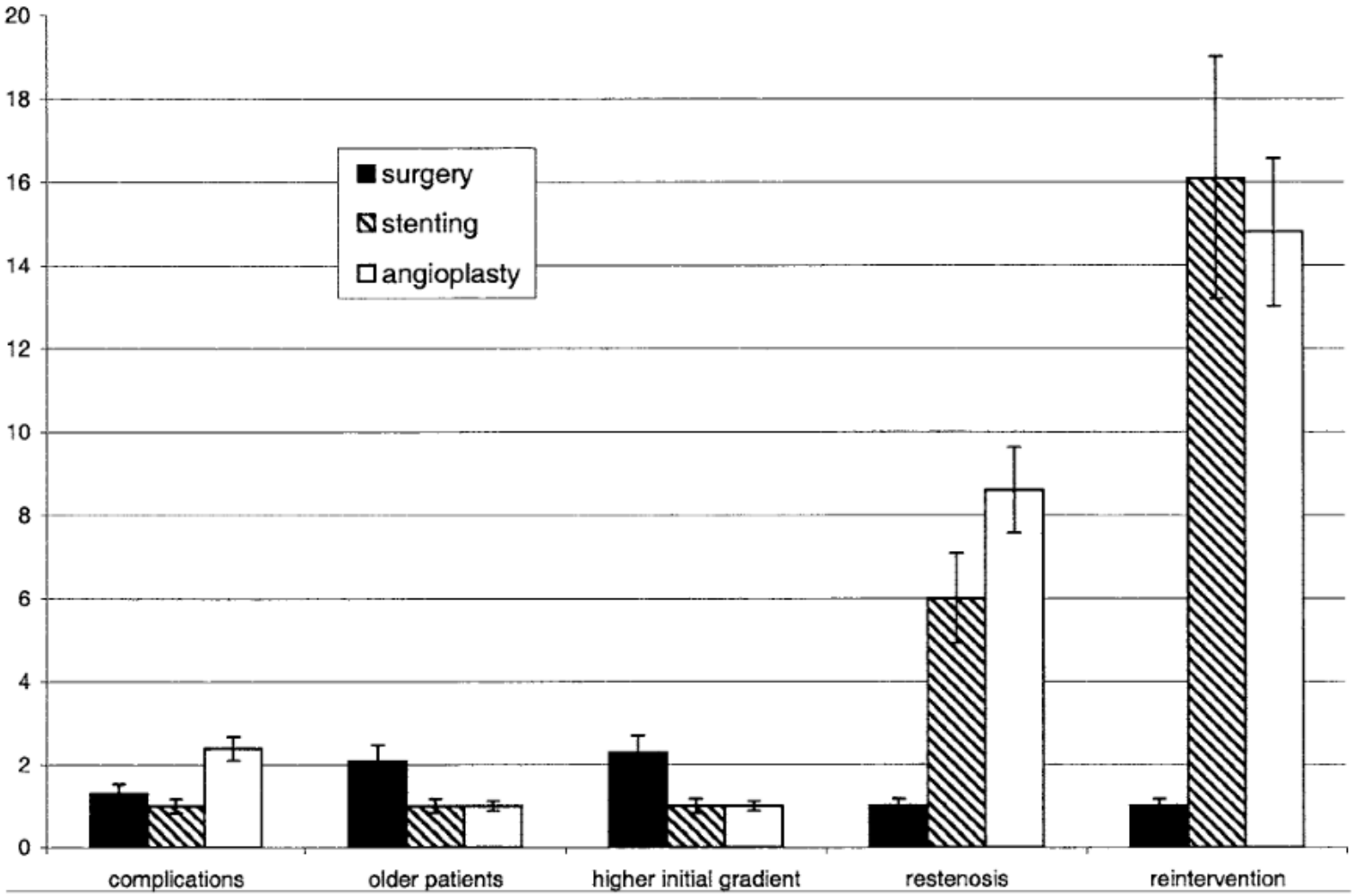

The Results of Catheter-Based Therapy Compared With Surgical Repair of Adult Aortic Coarctation. John Alfred Carr, MD. JACC, 2006

TRAITEMENT ENDOVASCULAIRE ENFANT

Table II. Complications within the 30 days after aortic coarctation intervention grouped depending on the type of treatment

	Surgery	Transcatheter	*P*
Major complications*	2 (7%)	1 (2%)	.553
Aortic rupture	0	1 (2%)	1.000
Urgent reintervention	1 (3%)	1 (2%)	1.000
Blood transfusion	2 (7%)	1 (2%)	.553
Permanent sequelae	0	0	–
Death	0	0	–
Minor complications*	15 (50%)	8 (16%)	.002
Stent migration	0	2 (4%)	.525
Intimal tear	0	4 (8%)	.291
Aortic aneurysm	0	1 (2%)	1.000
Pleural effusion	2 (6%)	0	.138
Chylothorax	1 (3%)	0	.375
Respiratory distress	1 (3%)	0	.375
Access site complications	3 (10%)	3 (6%)	.459
Paradoxical hypertension	11 (36%)	2 (4%)	<.001
Hematuria	0	1 (2%)	1.000
Chest hematoma	0	1 (2%)	1.000
Reperfusion syndrome	1 (3%)	0	.375
Total complications*	15 (50%)	9 (18%)	.005

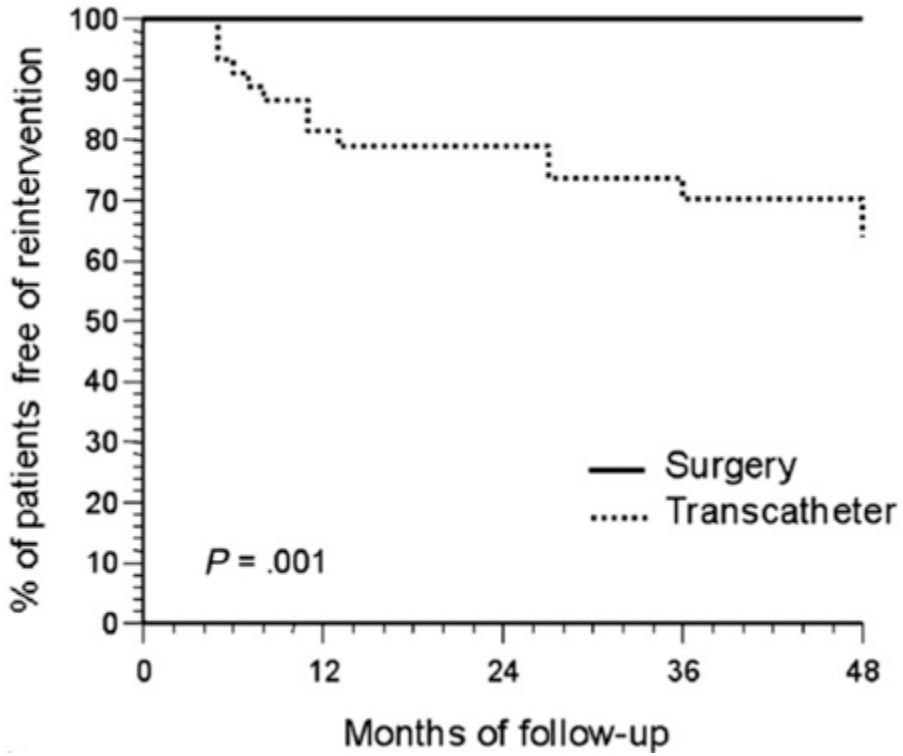

Comparison of surgical and transcatheter treatment for native coarctation of the aorta in patients z 1 year old. The Quebec Native Coarctation of the Aorta Study. Josep Rode´s-Cabau et al. American Heart Journal, 2007

TRAITEMENT ENDOVASCULAIRE

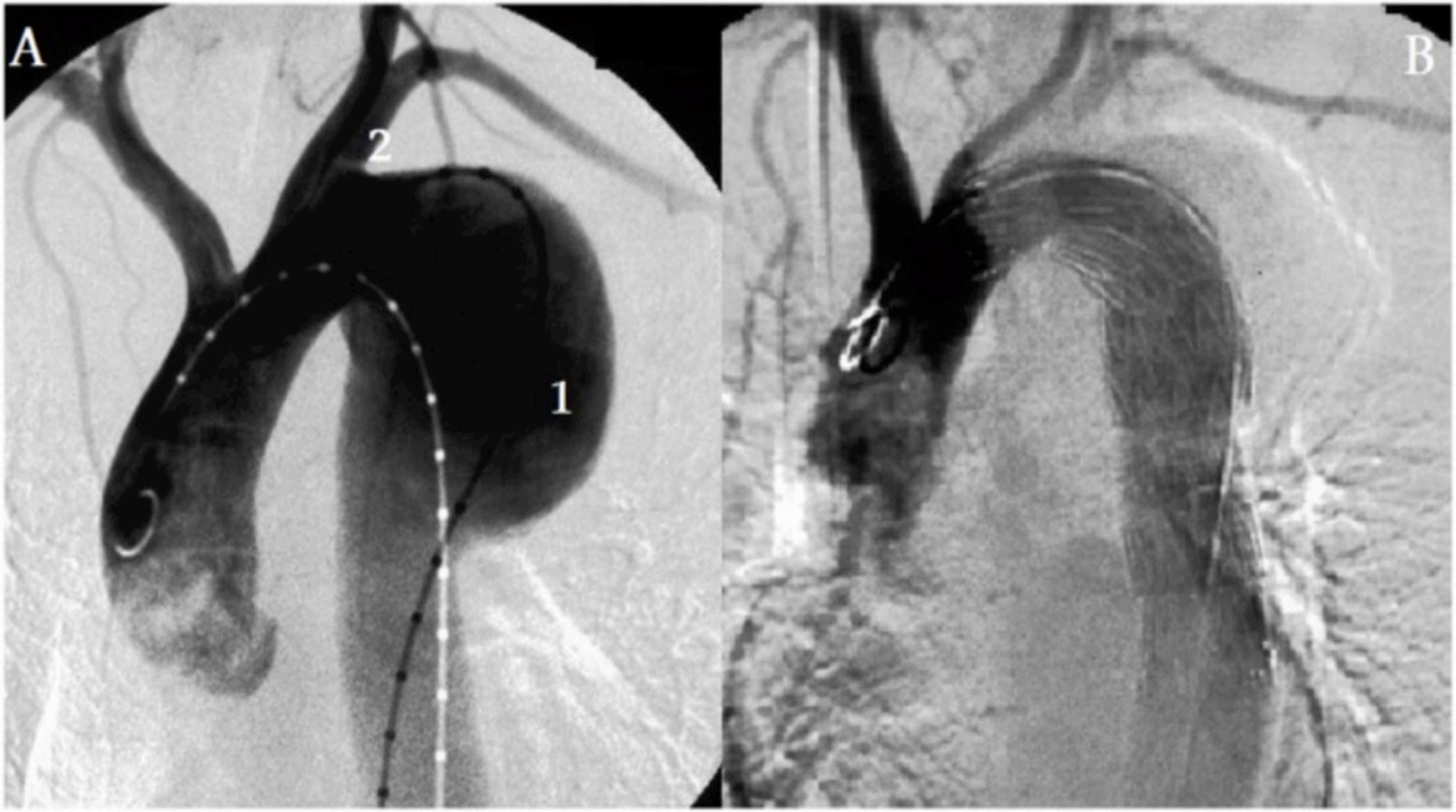

TRAITEMENT ENDOVASCULAIRE

COMPLICATIONS TARDIVES

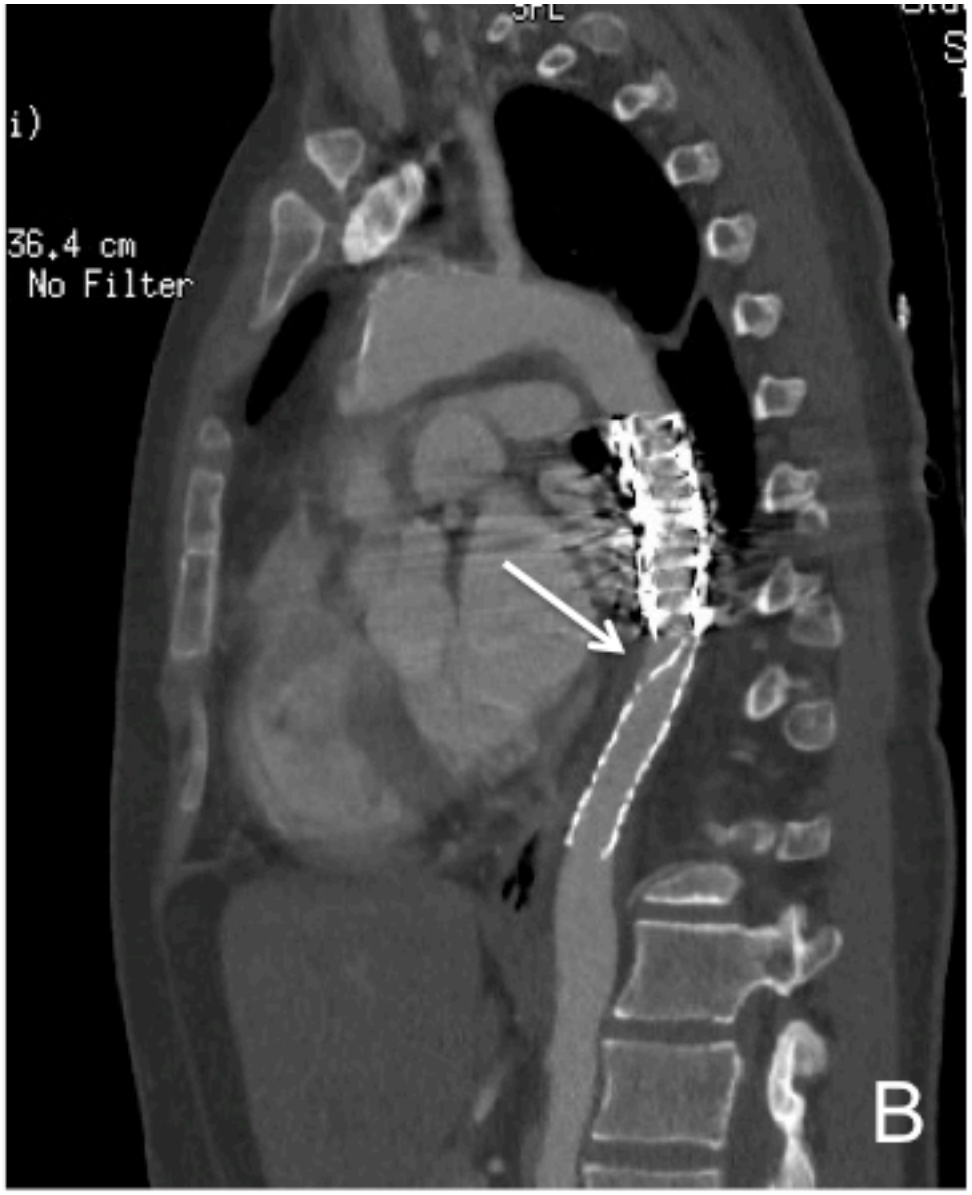

CONCLUSION

Fausse réputation de bénignité, périlleux

Prostine a changé le pronostic des coarctations néonatales

Associée à d'autres malformations : interventions lourdes

Pas de technique supérieure sur la fréquence des récidives

Techniques endovasculaires :

- Enfant : Très discuté
- Adulte : 1ere intention
- RECOARCTATION

INTERRUPTION DE L'ARCHE

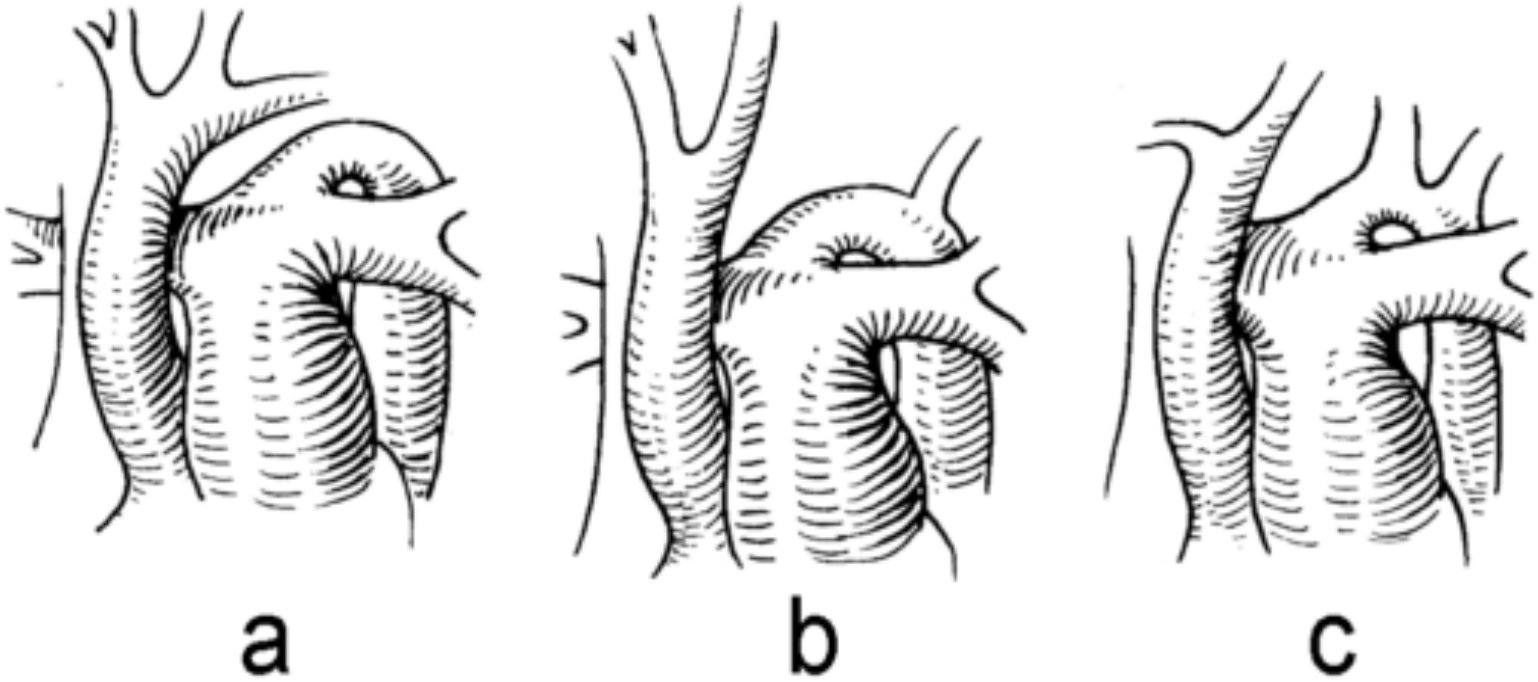

Lésions associées fréquentes:

CIV +++

FAP, TGVx (malpositions), truncus arteriosus

INTERRUPTION DE L'ARCHE

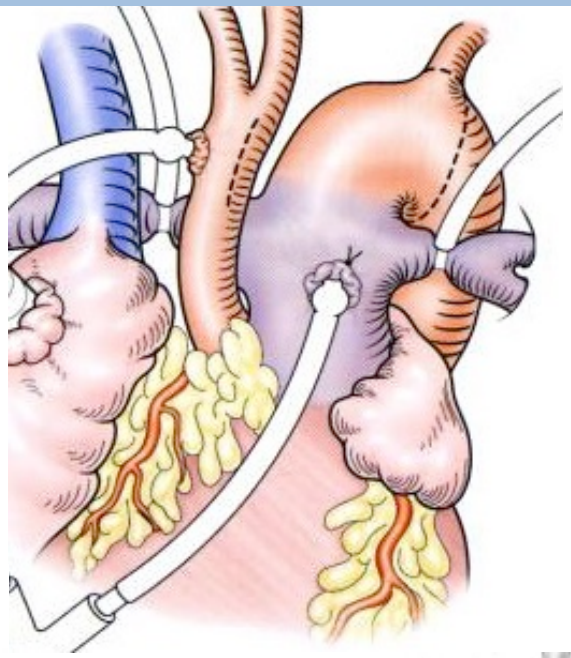

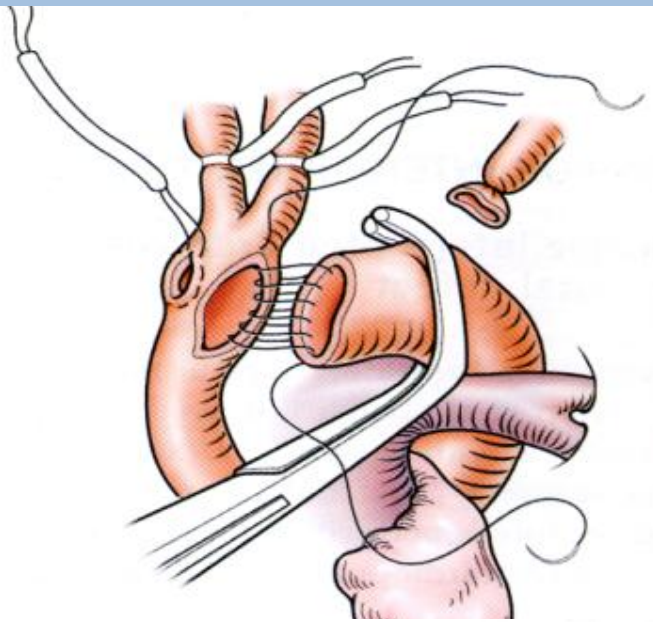

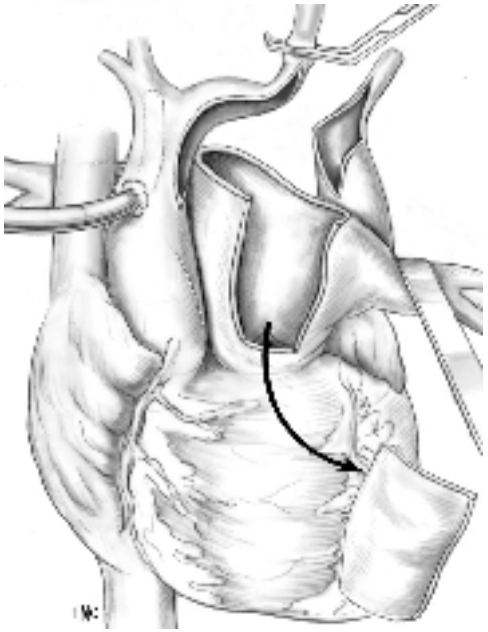

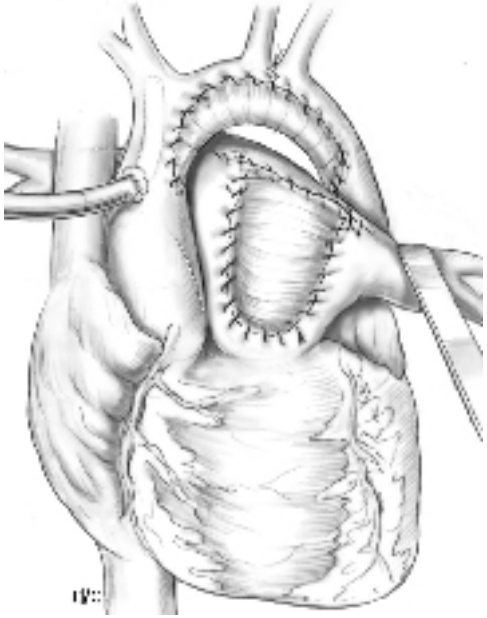

INTERRUPTION DE L’ARCHE

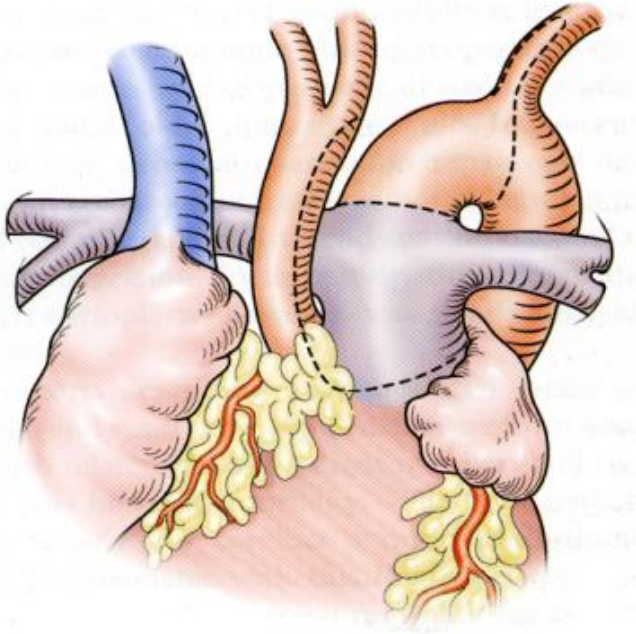

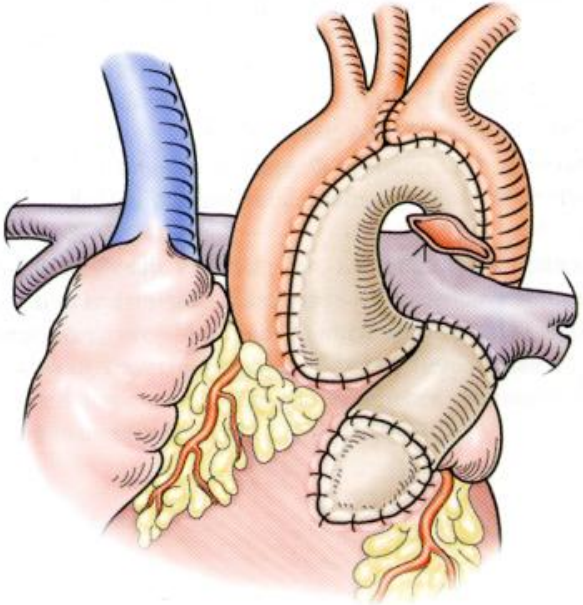

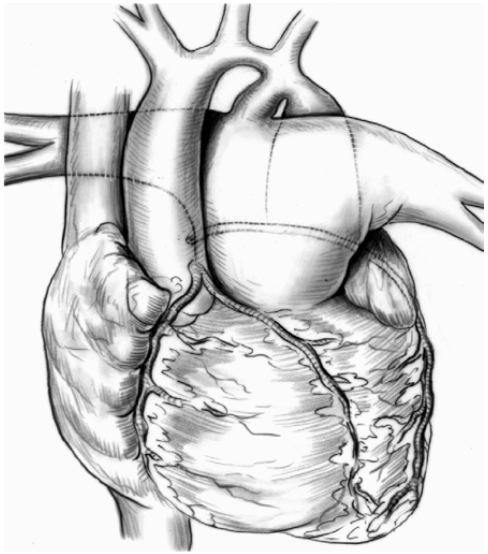

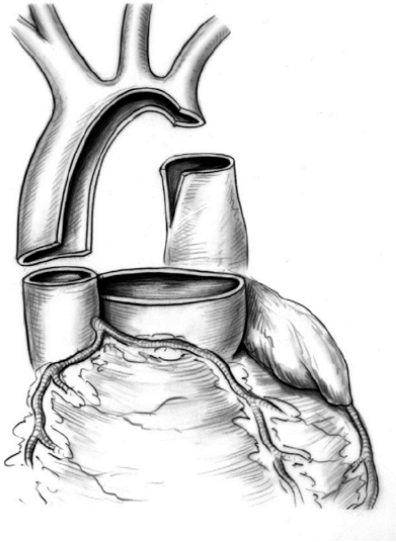

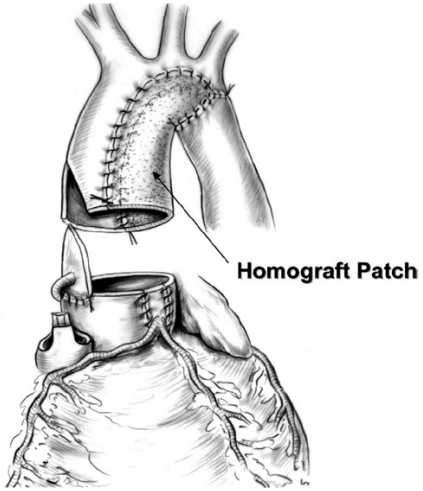

INTERRUPTION DE L'ARCHE

COMPLICATIONS PRÉCOCES

- Saignement
- HTA paroxystique
- Paraplégie
- Iléus réflexe
- Chylothorax
- Paralysie récurrentielle
- **Compression bronchique gauche**
- **Bloc auriculo-ventriculaire**

COMPLICATION TARDIVE

- **Re-coarctation ++++ : traitement endo-vasculaire**
- **Obstacle sous aortique**

COARCTATION AORTIQUE

CHU Bordeaux
Service de chirurgie cardio-vasculaire, Pr. Roques
Alexandre Metras
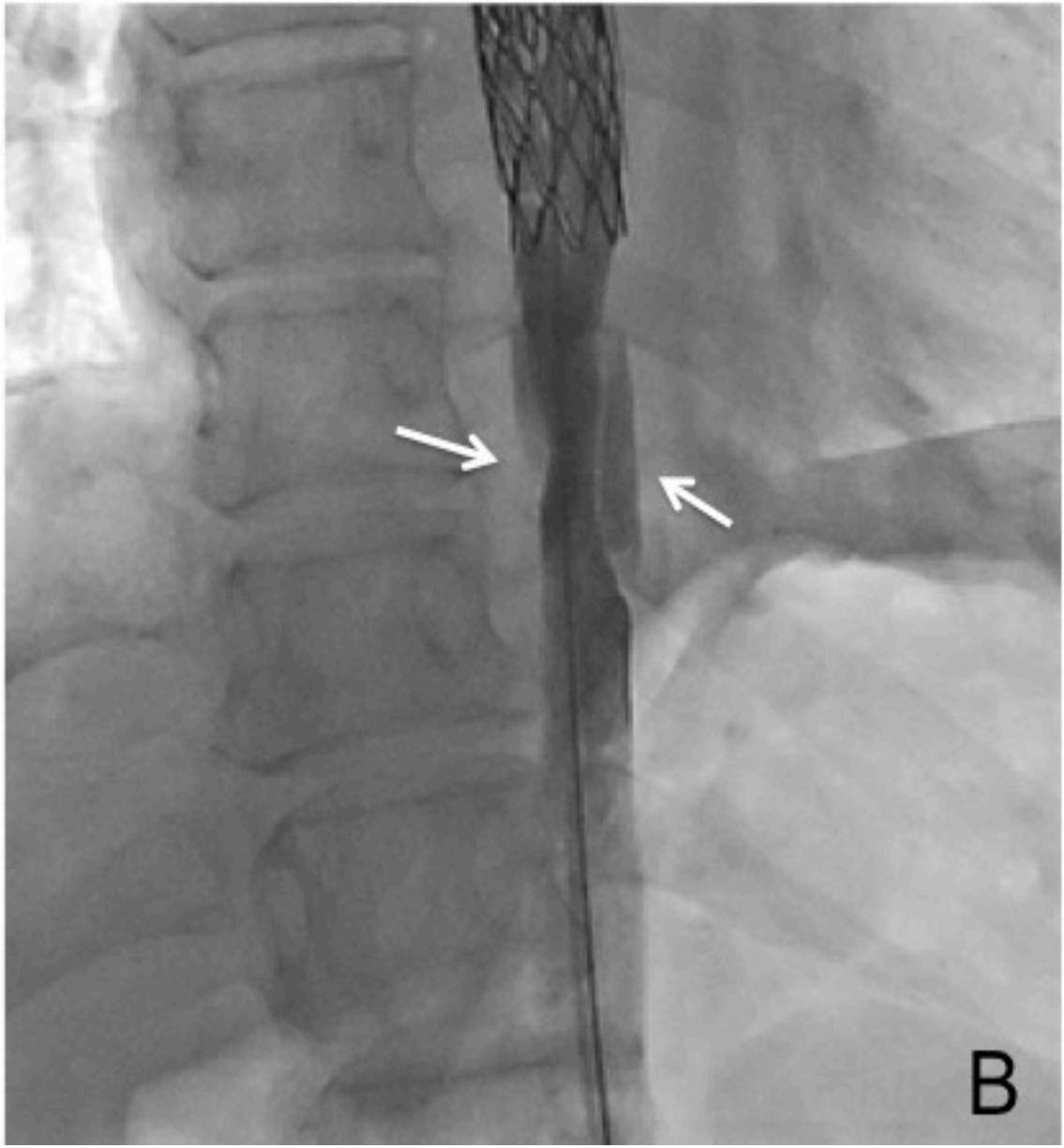
COMPLICATIONS TARDIVES