Malpositions des gros vaisseaux

Dr Régis GAUDIN
DU REANIAMTION DES CARDIOPATHIES CONGÉNITALES - PARIS

Description

CLICK TO ADD SUBTITLE

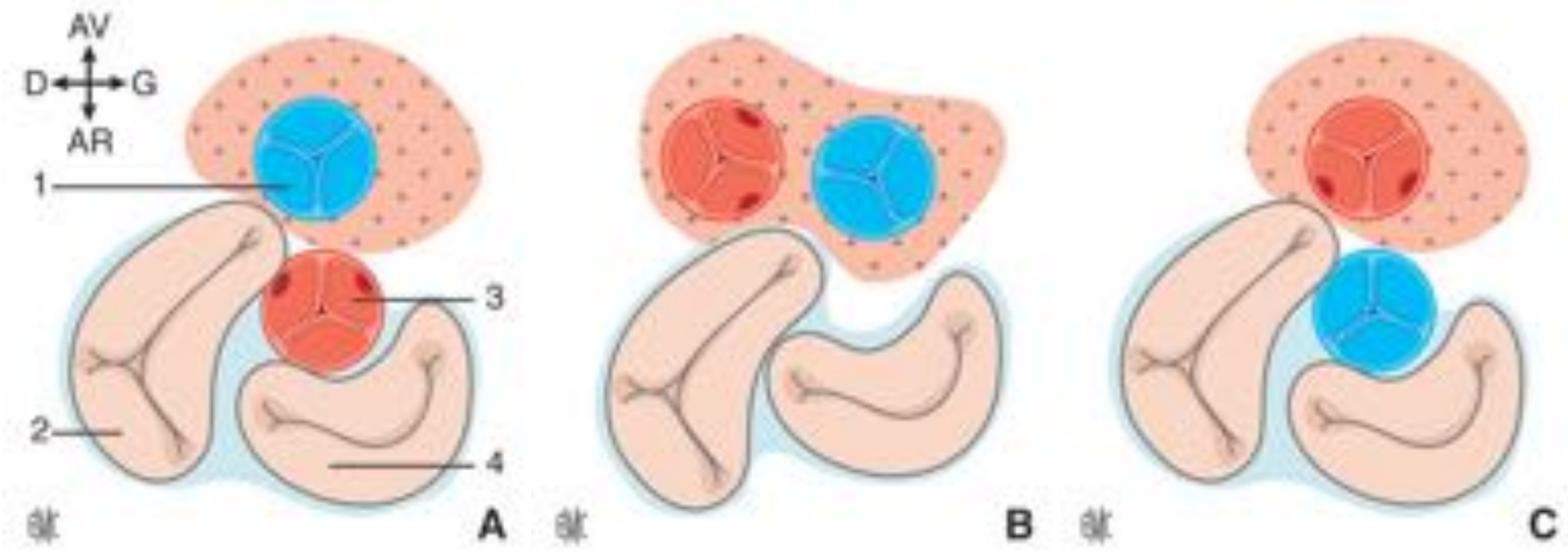

normal malpositions transposition

Description

CLICK TO ADD SUBTITLE

Sous-aortique

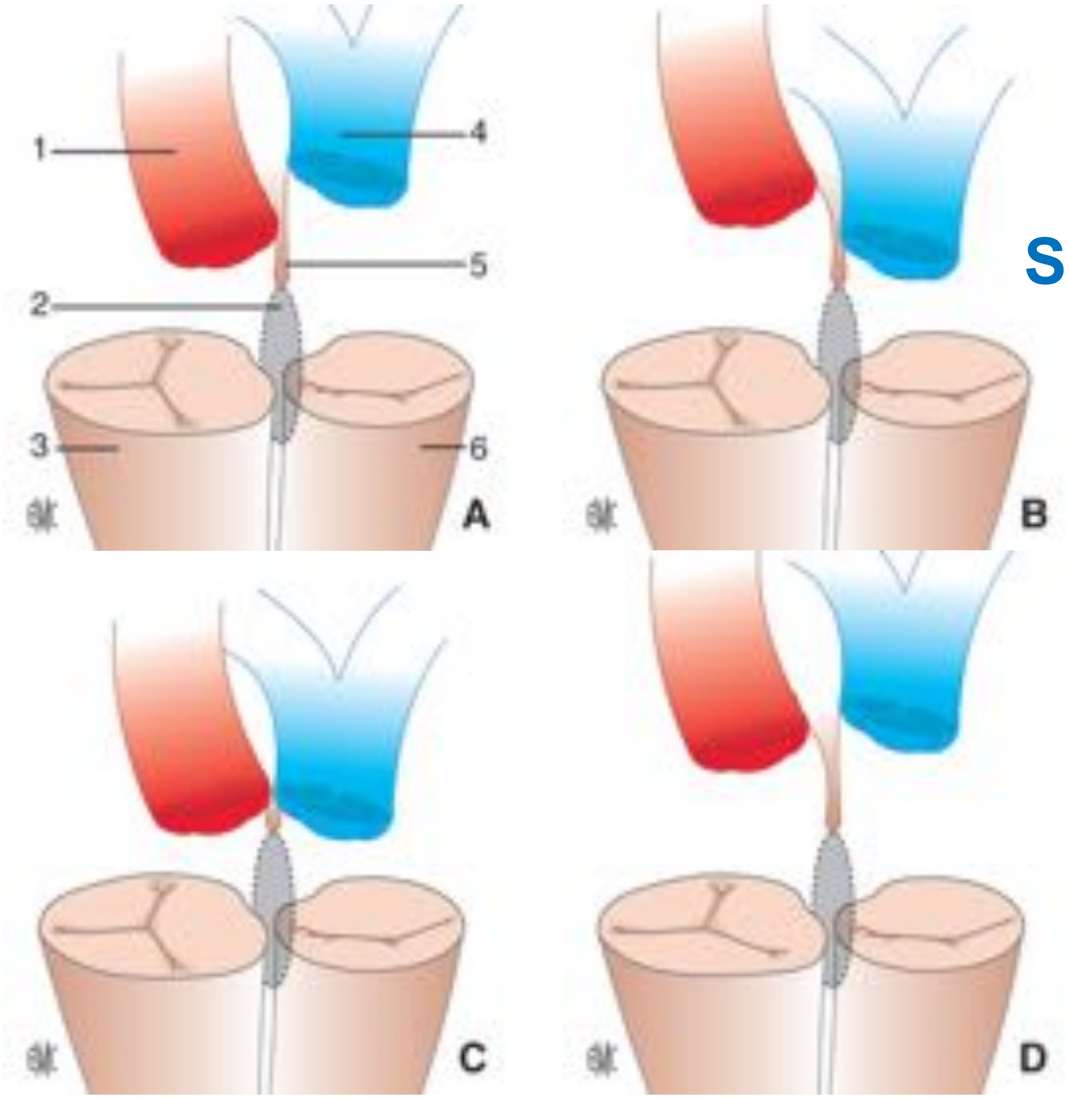

Sous-pulmonaire

doubly - commited

non - commited

Stratégie

CLICK TO ADD SUBTITLE

3 questions

1. **Réparation biventriculaire possible ?**

   « OUI »

2. **Réparation "anatomique" possible ?**

   « NON »

3. **Quelle réparation extra-anatomique est indiquée ?**

Stratégie

CLICK TO ADD SUBTITLE

Eléments de décision

1/ **distance tricuspide – pulmonaire**

2/ état de la voie pulmonaire
(normale ou sténosée)

Stratégie

CLICK TO ADD SUBTITLE

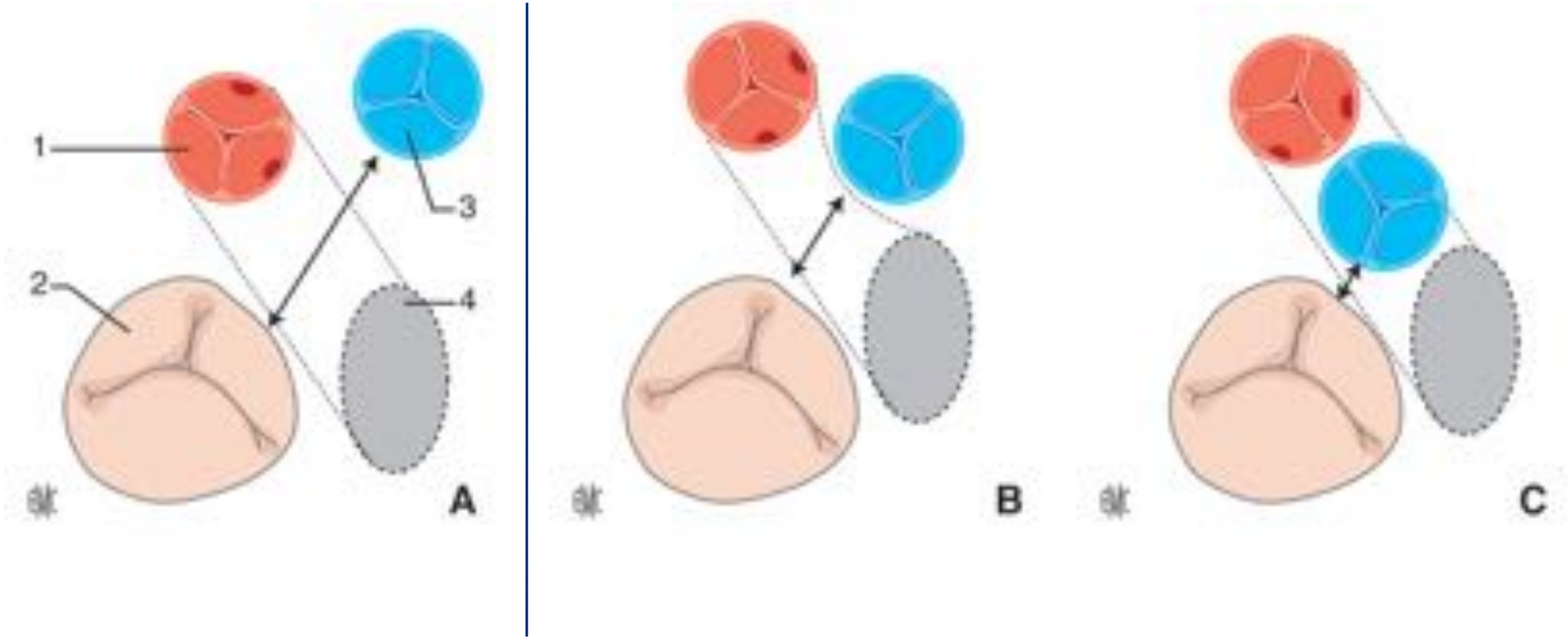

Stratégie

CLICK TO ADD SUBTITLE

Eléments de décision

1/ distance tricuspide – pulmonaire

2/ **état de la voie pulmonaire (normale ou sténosée)**

Stratégie

CLICK TO ADD SUBTITLE

	VP normale	VP sténosée
Tric – Pulm > ø Ao.	IVR	IVR + élargissement VP
Tric – Pulm < ø Ao.	- VG - AP - switch	- Rastelli - REV - Bex-Nikaïdoh

Stratégie

CLICK TO ADD SUBTITLE

- **distance tricuspide – pulmonaire « suffisante (> diamètre aorte)**

  - tunnellisation VG-aorte
  - voie VD-AP
    . rien si normale (type CIV)
    . élargissement si sténosée (type Fallot)

  = réparation intraventriculaire (IVR)

IVR

CLICK TO ADD SUBTITLE

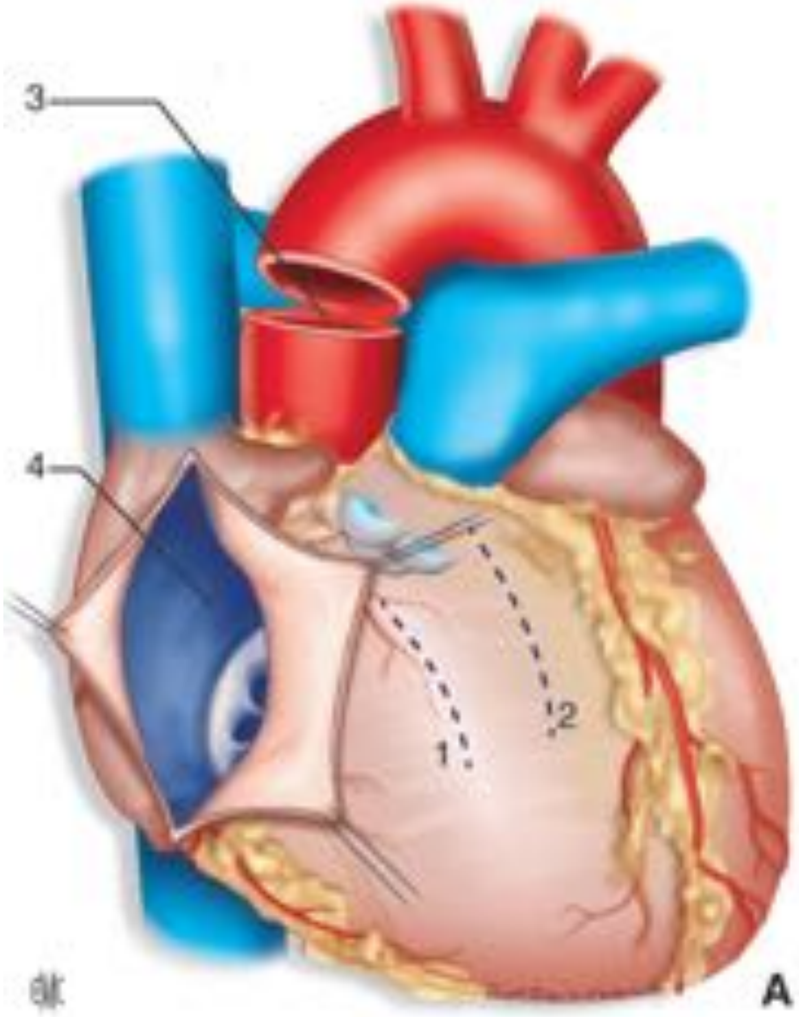

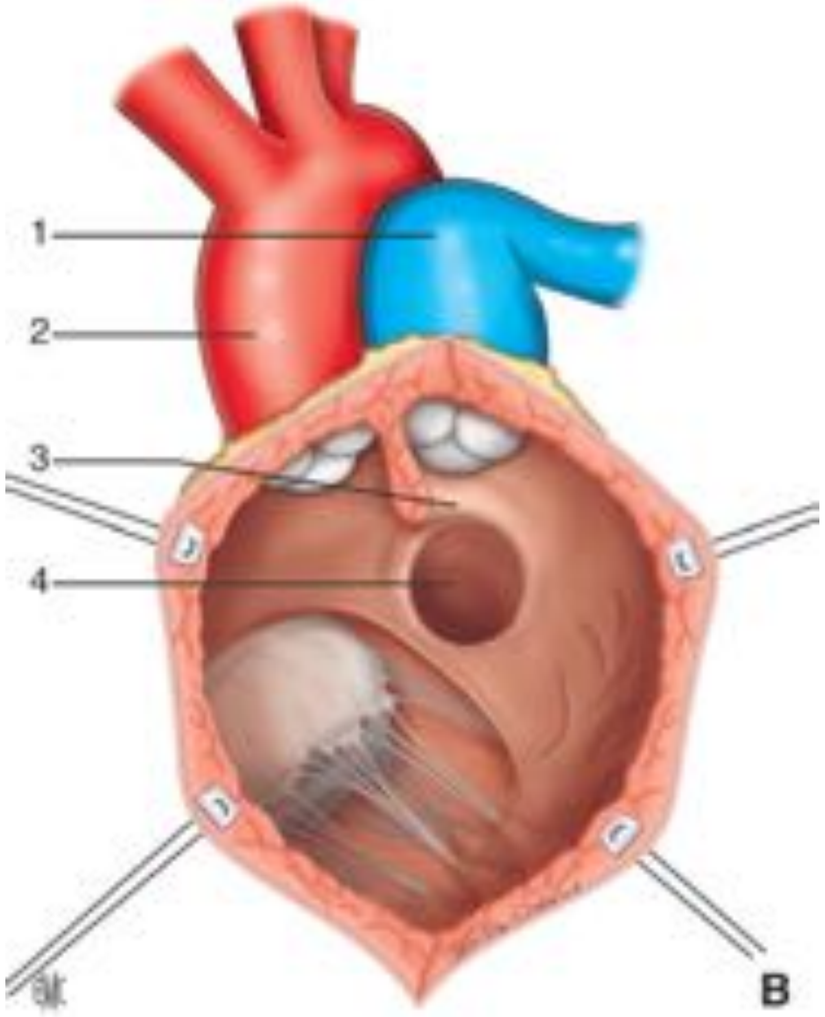

IVR

CLICK TO ADD SUBTITLE

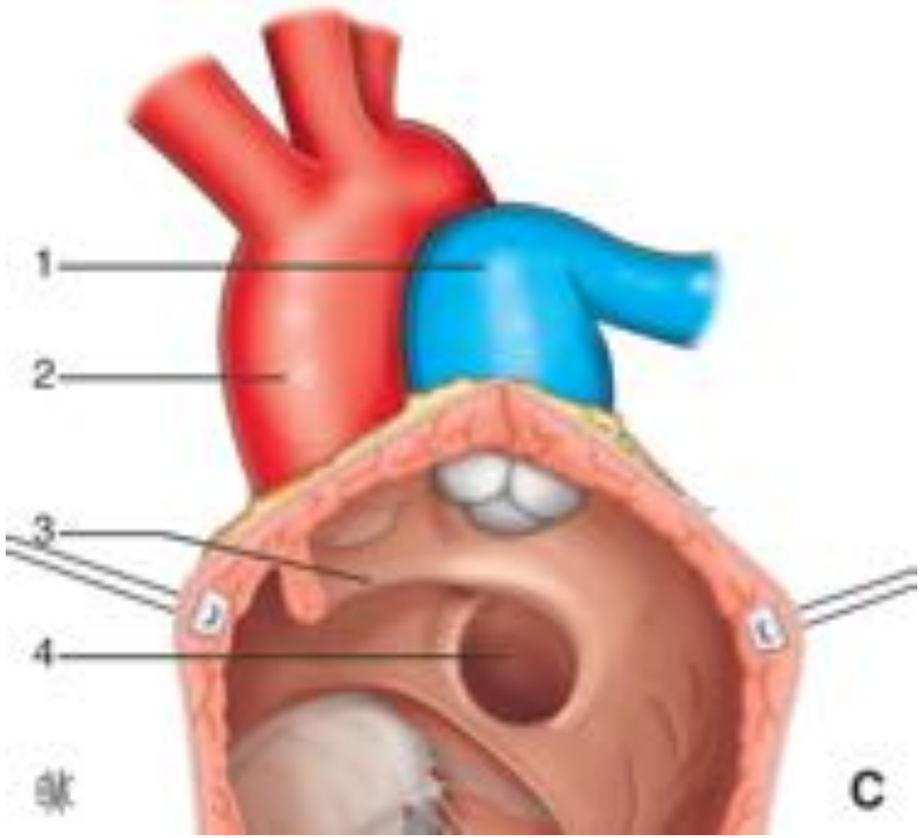

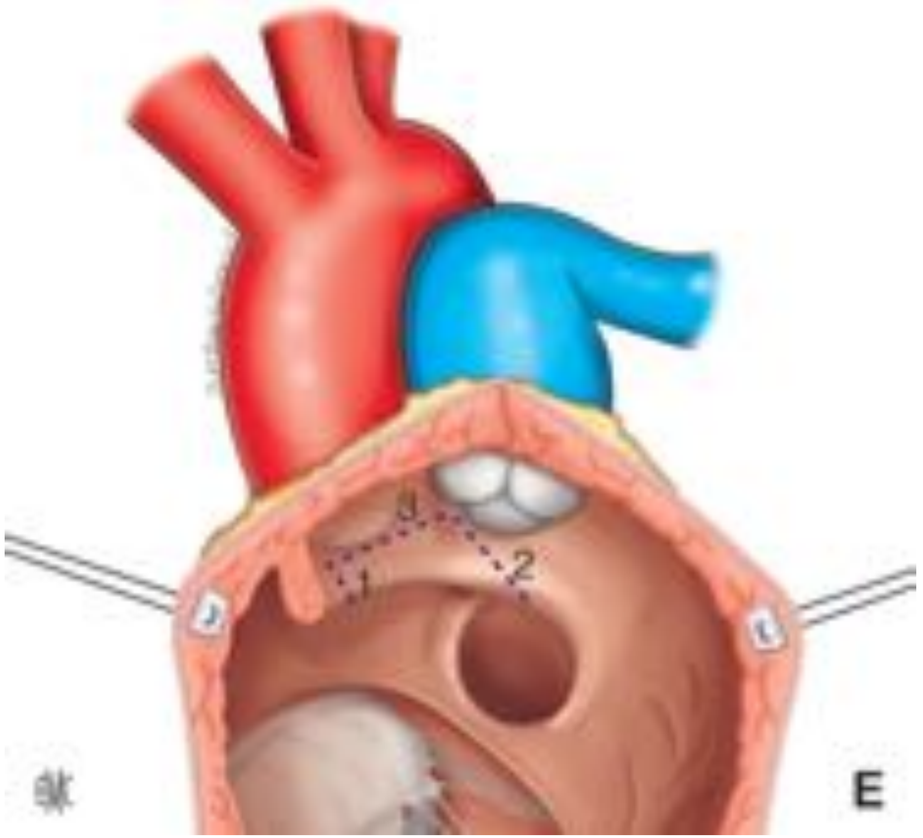

IVR

CLICK TO ADD SUBTITLE

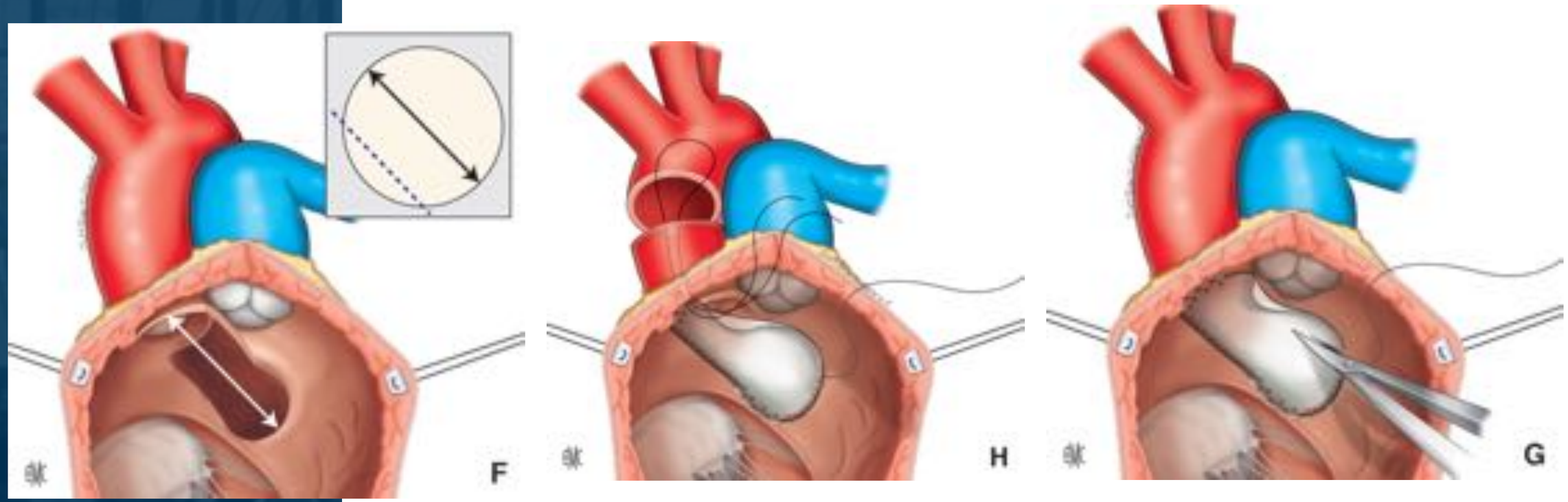

IVR

CLICK TO ADD SUBTITLE

Longueur du conus sous-aortique

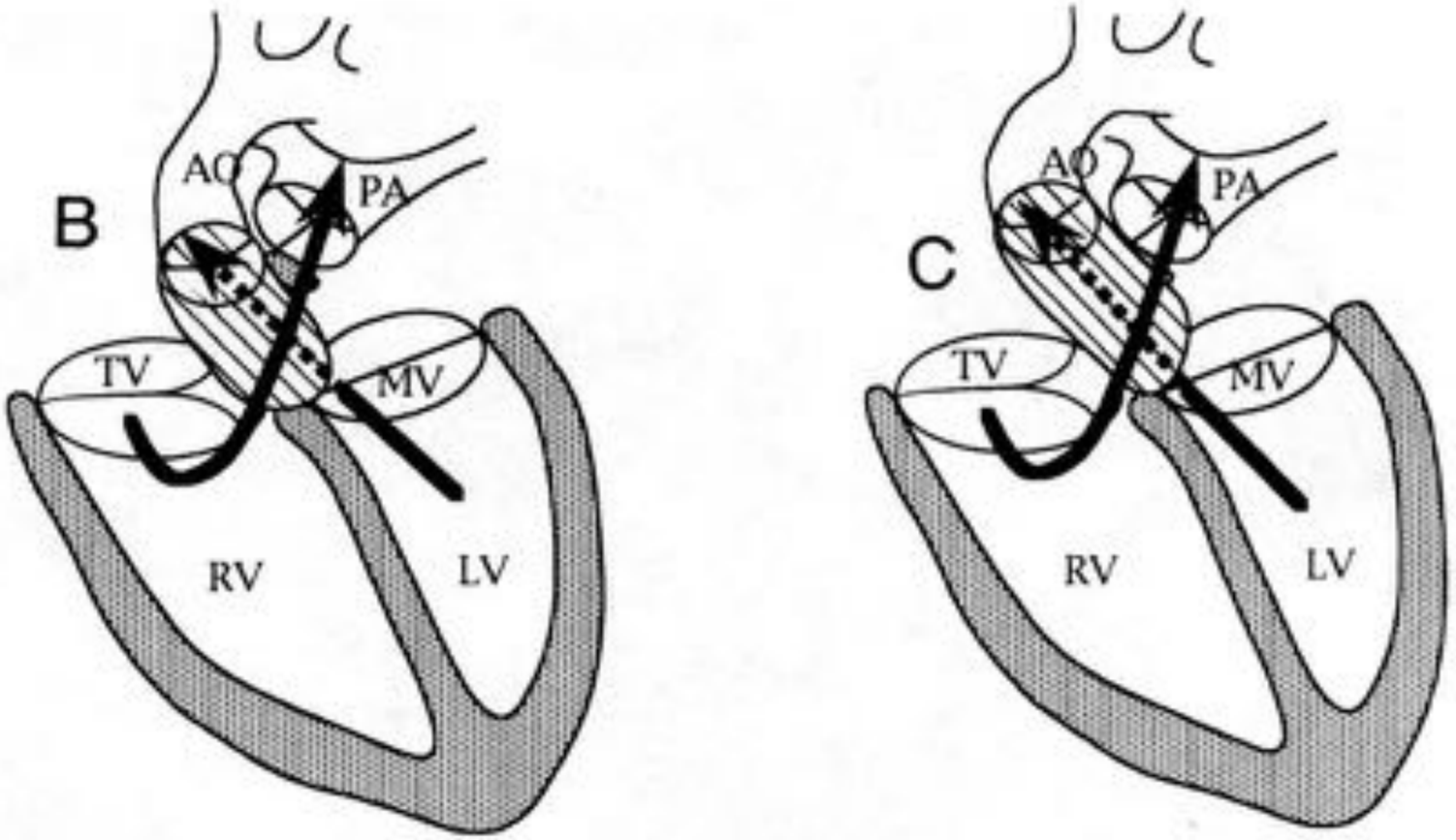

IVR

CLICK TO ADD SUBTITLE

Conus sous-aortique asymétrique

!! Distance tricuspide-pulmonaire insuffisante à la prise de décision !!

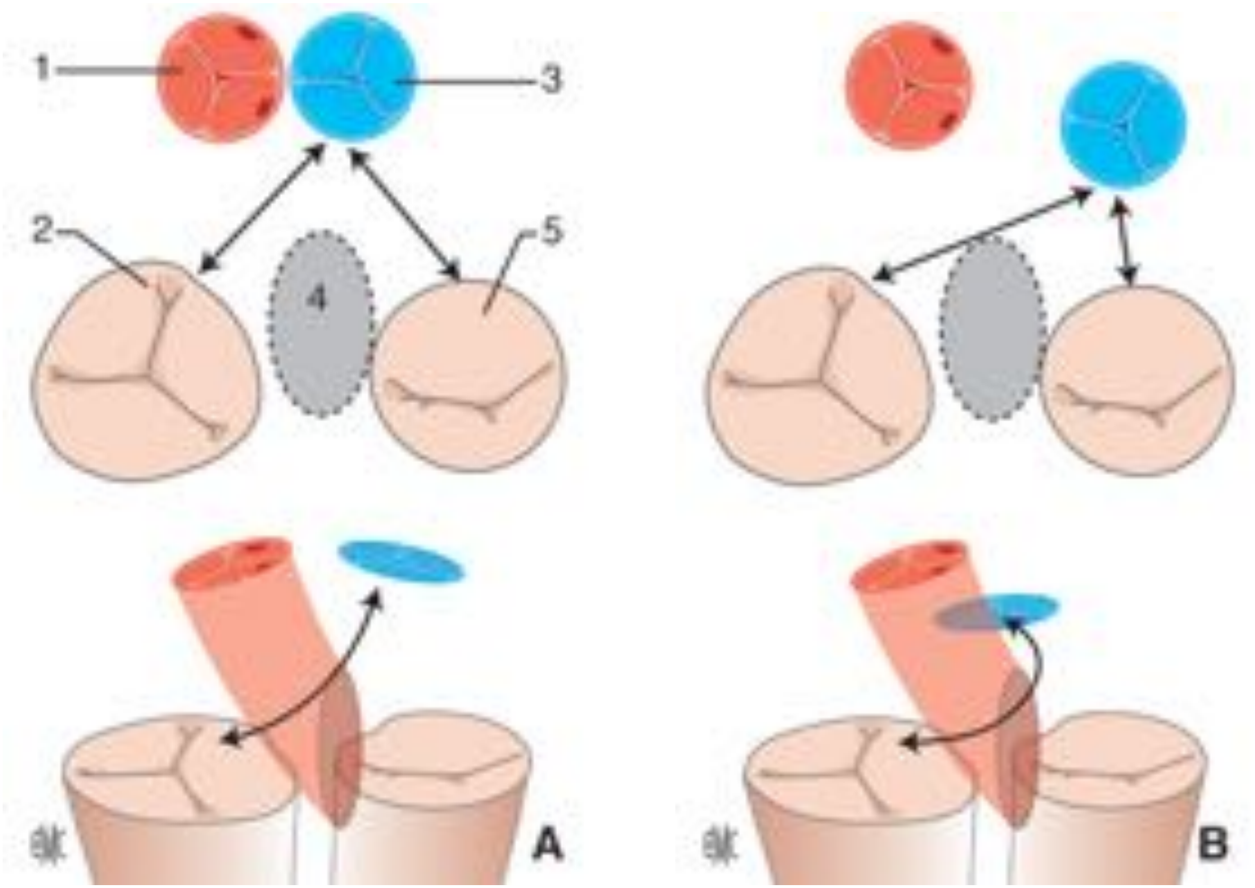

Stratégie

CLICK TO ADD SUBTITLE

- **distance tricuspide – pulmonaire «insuffisante» (< diamètre aorte)**

  - **voie pulmonaire normale**
    . tunnellisation VG-AP (TGV)
    . switch artériel

  - **voie pulmonaire sténosée**
    . tunnellisation VG-aorte
    . translocation ant. de la voie pulmonaire
    . Rastelli - REV

Tunnellisation VG-AP + Switch

CLICK TO ADD SUBTITLE

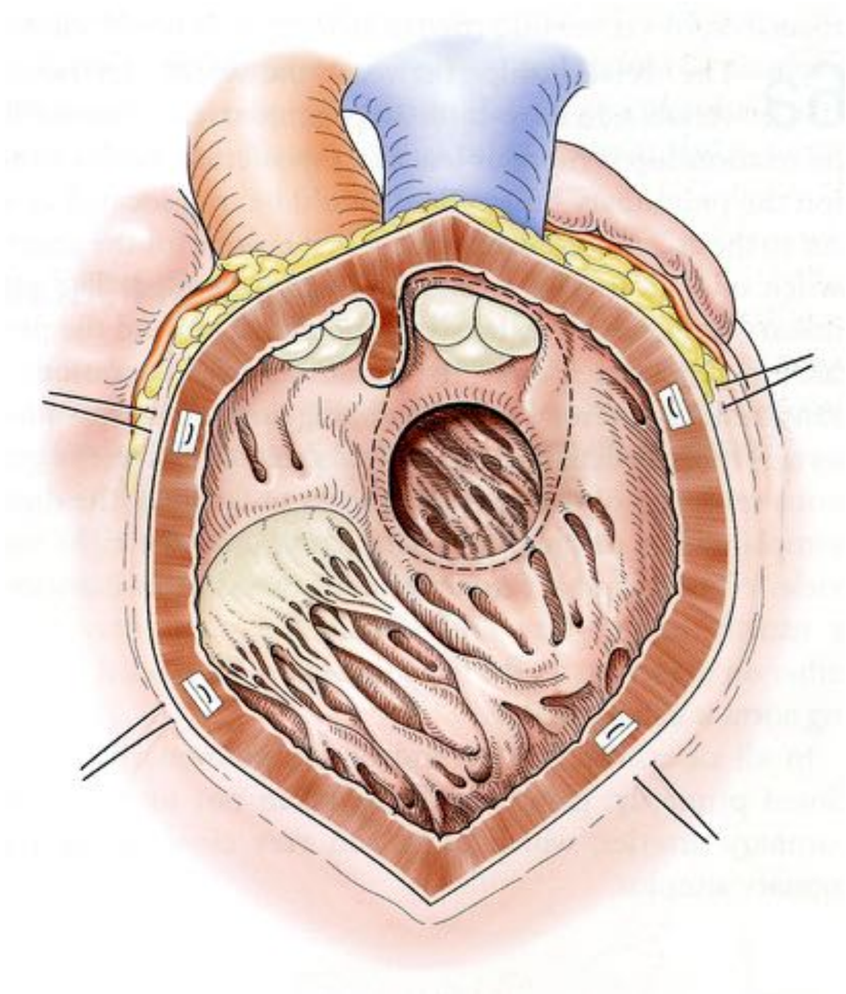

- **voie pulmonaire normale**
  . tunnellisation VG-AP (TGV)
  . switch artériel

Réparation type Rastelli

CLICK TO ADD SUBTITLE

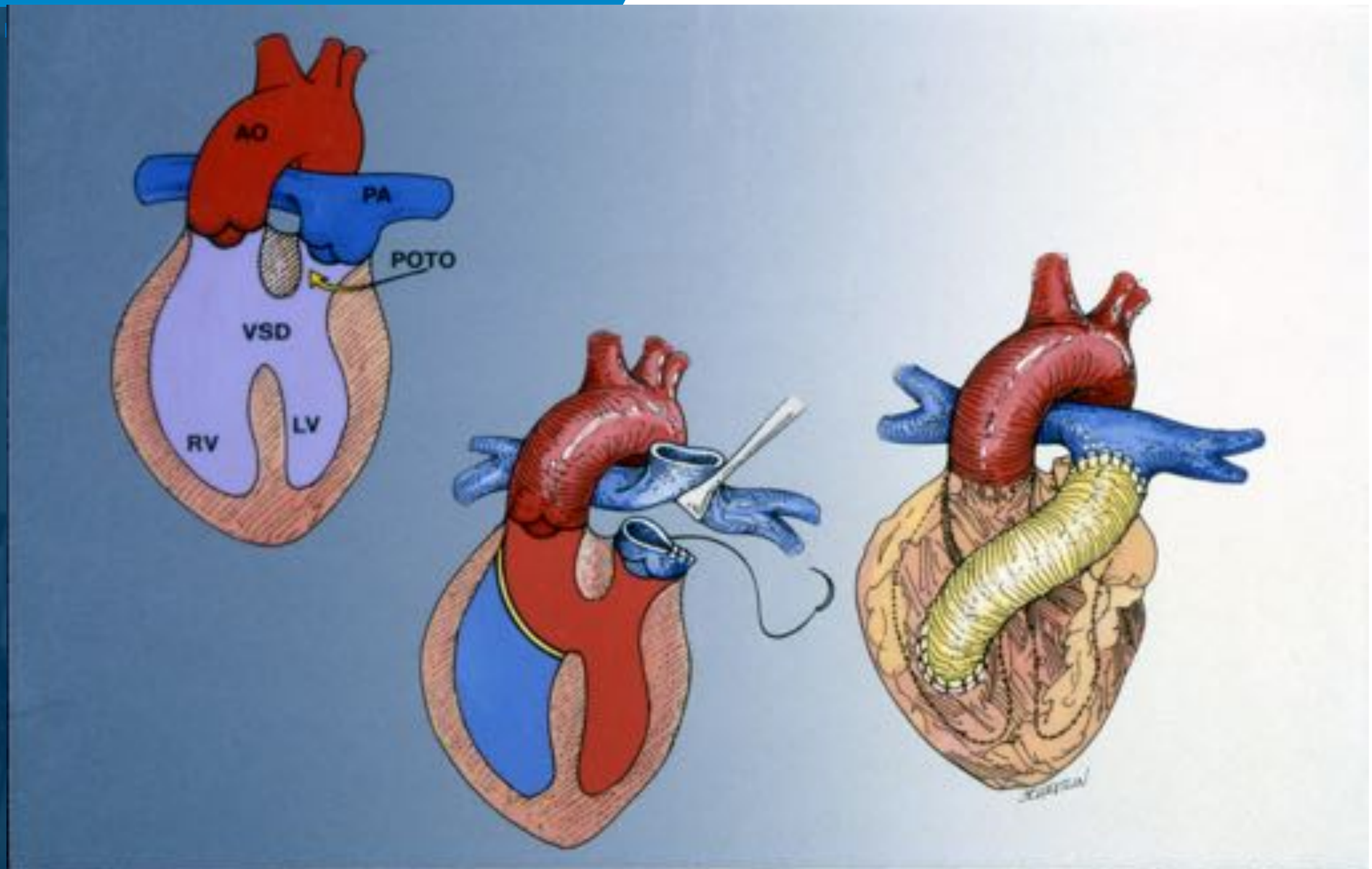

Réparation type Rastelli

CLICK TO ADD SUBTITLE

- ✓ pas toujours possible
  - CIV non committed / restrictive
  - anomalies des valves AV
  - hypoplasie VG / VD
- ✓ Risque potentiel de sténose sous-aortique
- ✓ reduction de la cavité ventriculaire droite
- ✓ Remplacements itératifs de la voie droite

Réparation type Rastelli

CLICK TO ADD SUBTITLE

- ✓ pas toujours possible
  - CIV non committed / restrictive
  - anomalies des valves AV
  - hypoplasie VG / VD
- ✓ Risque potentiel de sténose sous-aortique
- ✓ reduction de la cavité ventriculaire droite
- ✓ Remplacements itératifs de la voie droite

Réparation type Rastelli

CLICK TO ADD SUBTITLE

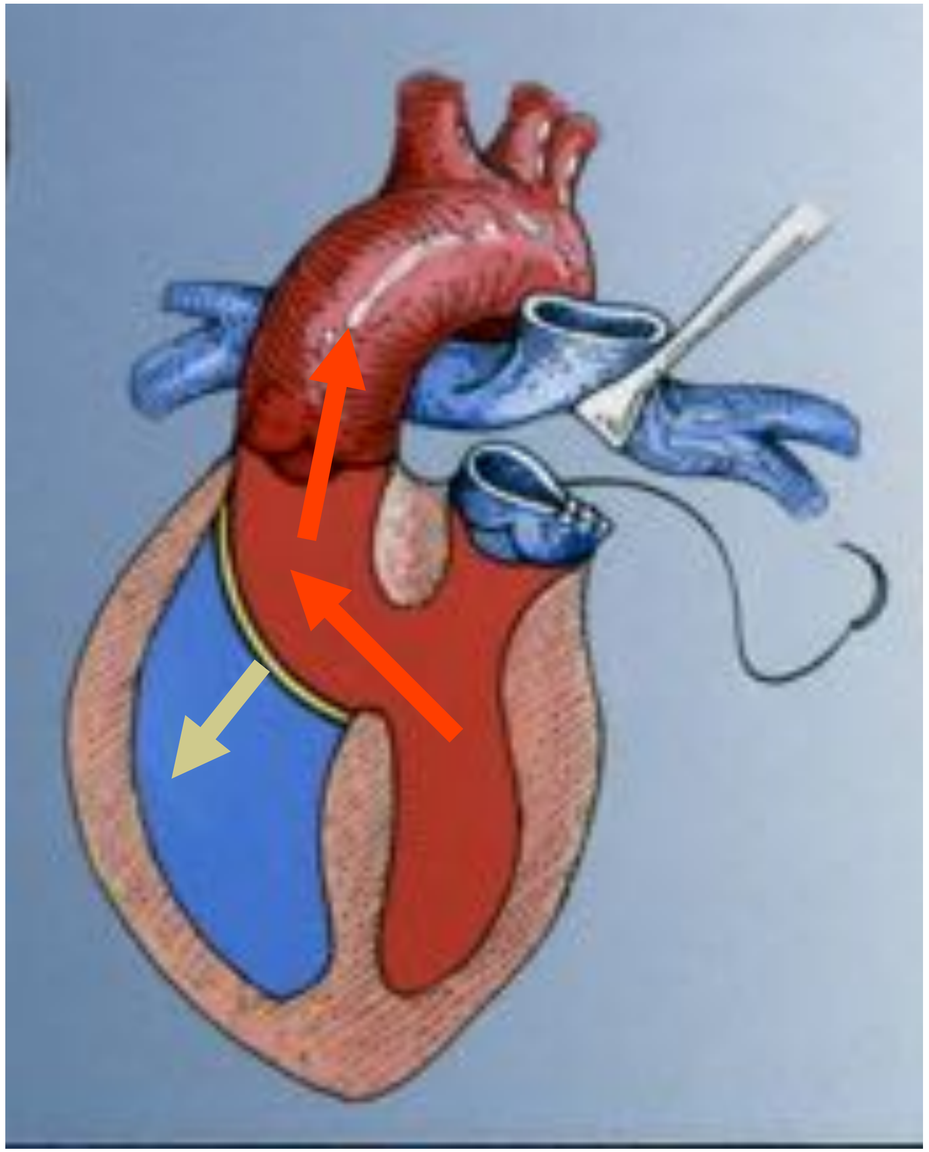

Réparation type Rastelli

CLICK TO ADD SUBTITLE

- ✓ pas toujours possible
  - CIV non committed / restrictive
  - anomalies des valves AV
  - hypoplasie VG / VD
- ✓ Risque potentiel de sténose sous-aortique
- ✓ reduction de la cavité ventriculaire droite
- ✓ Remplacements itératifs de la voie droite

Réparation type Rastelli

CLICK TO ADD SUBTITLE

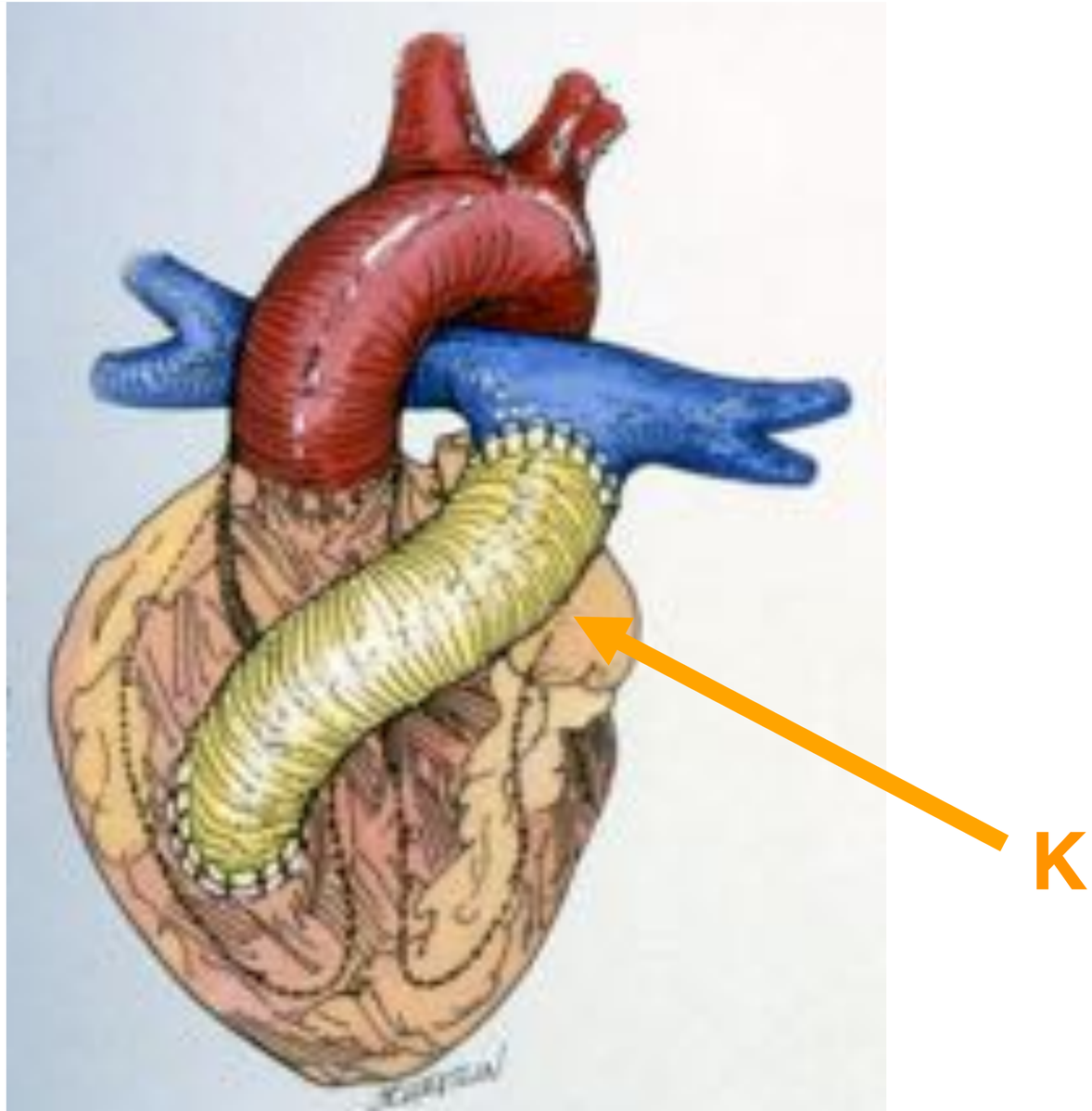

REV

CLICK TO ADD SUBTITLE

- ✓ possible dans certaines contre-indications au Ra
  CIV restrictive
  anomalies valves AV(tricuspid valve)
- ✓ Faible risque de sténose sous-aortique
- ✓ Empiète moins sur le ventricule droit
- ✓ Croissance possible de la voie pulmonaire (moins de réopérations)

REV

CLICK TO ADD SUBTITLE

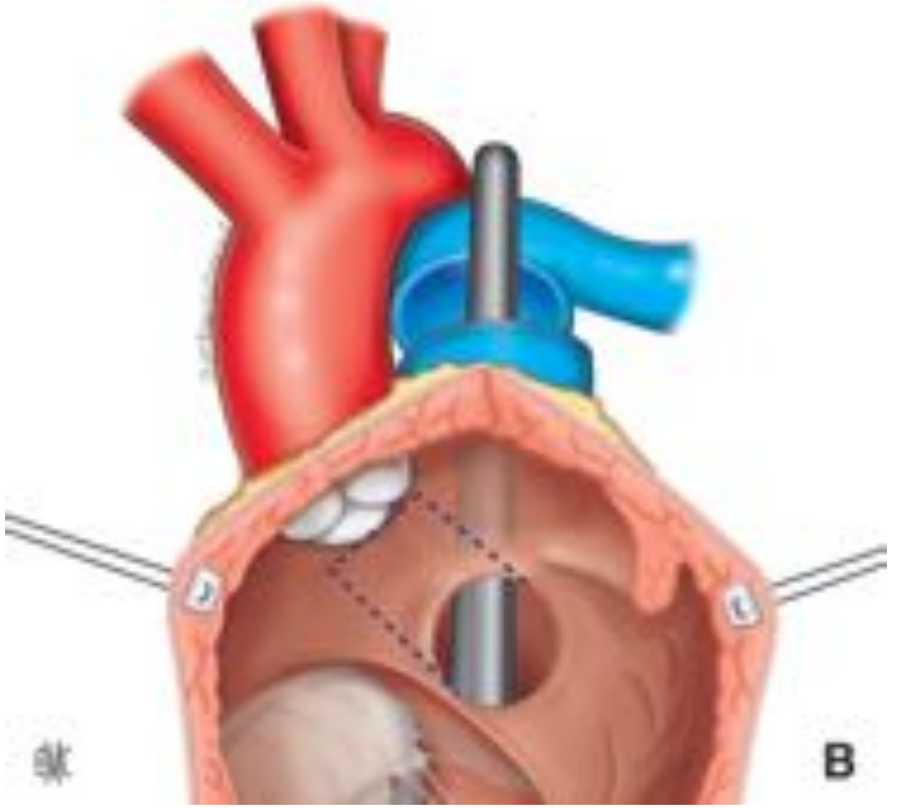

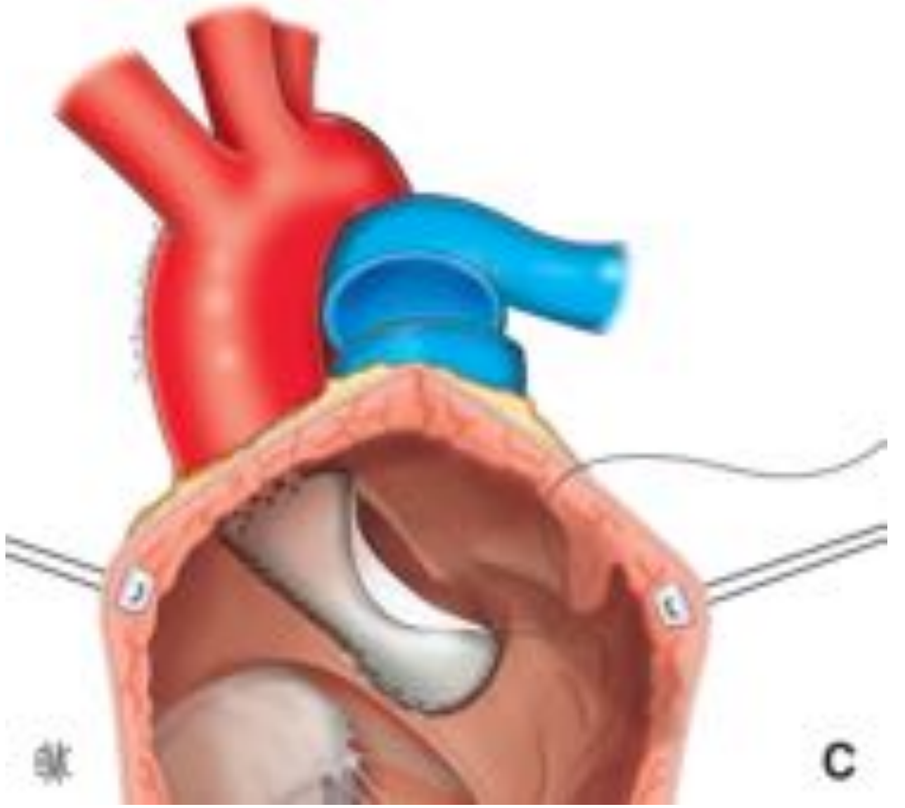

REV

CLICK TO ADD SUBTITLE

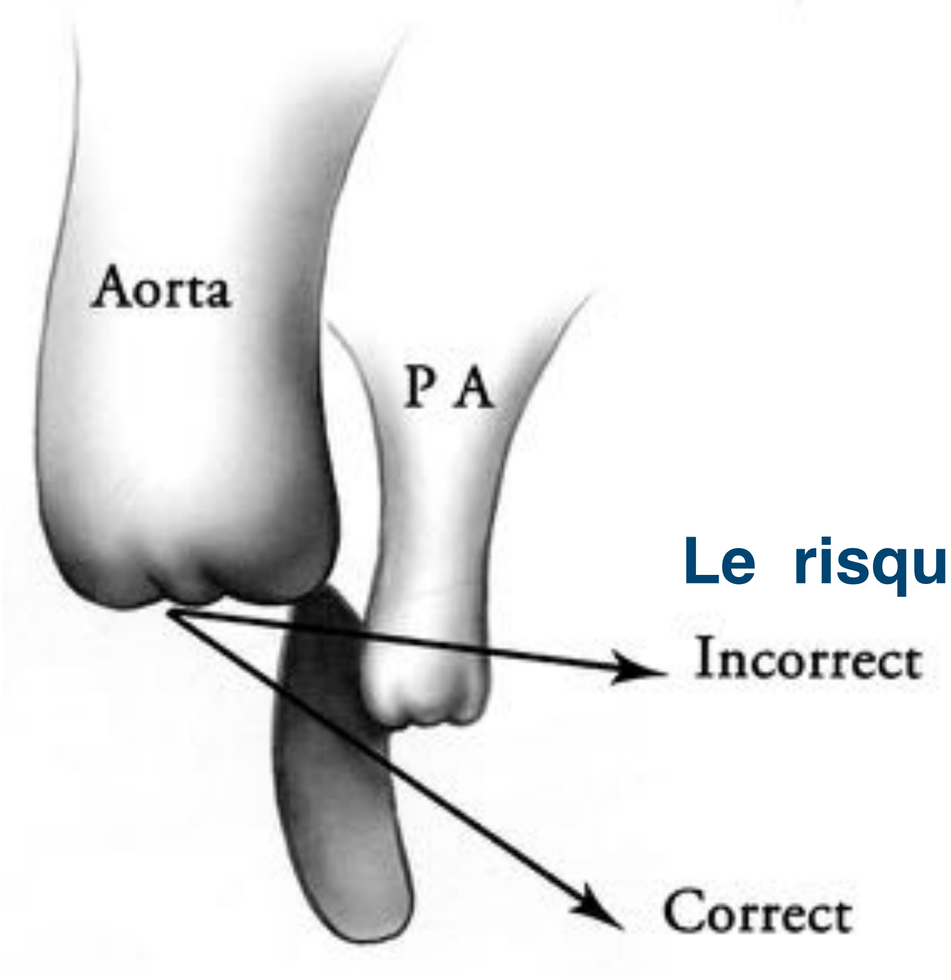

Le risque est de sortir du coeur

REV

CLICK TO ADD SUBTITLE

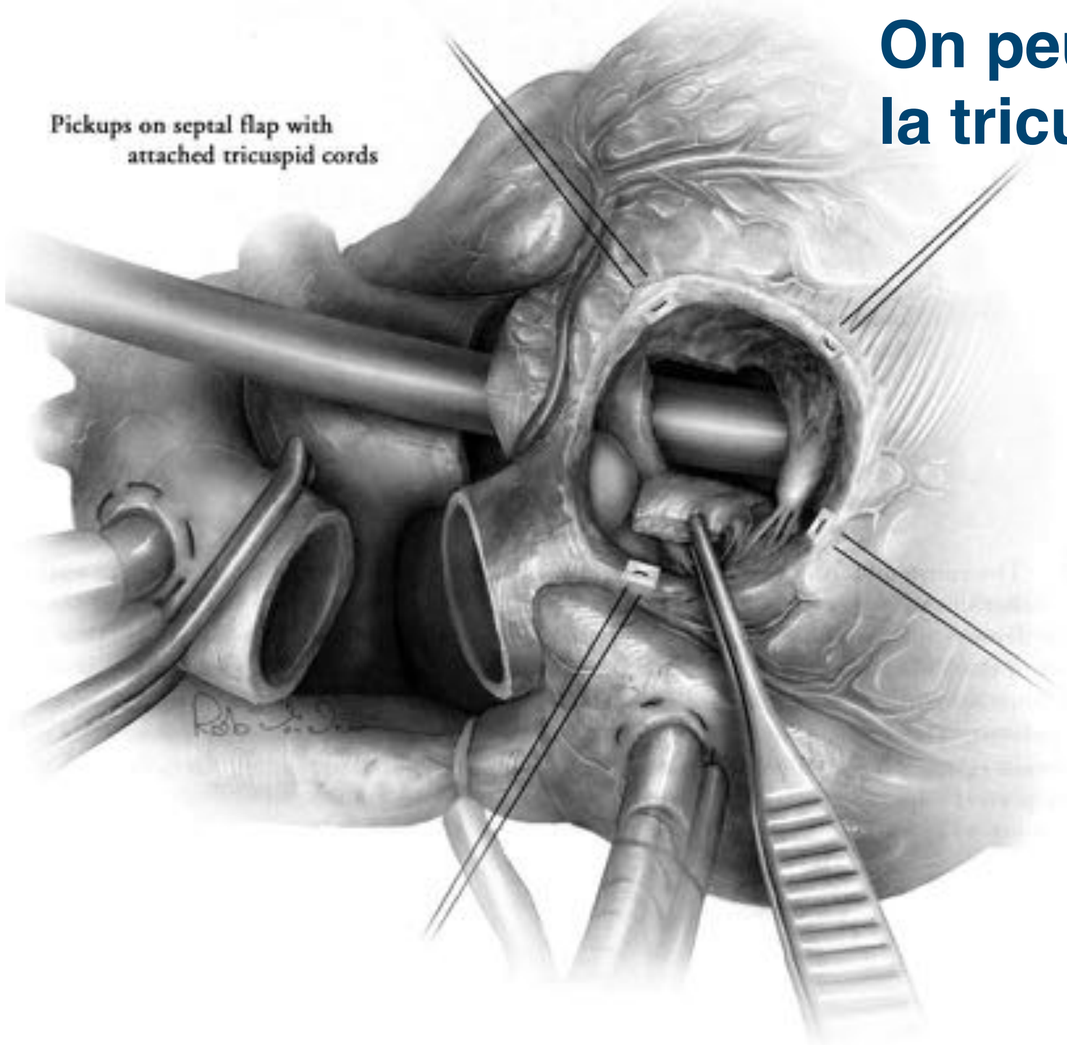

On peut déplacer l’insertion de la tricuspide

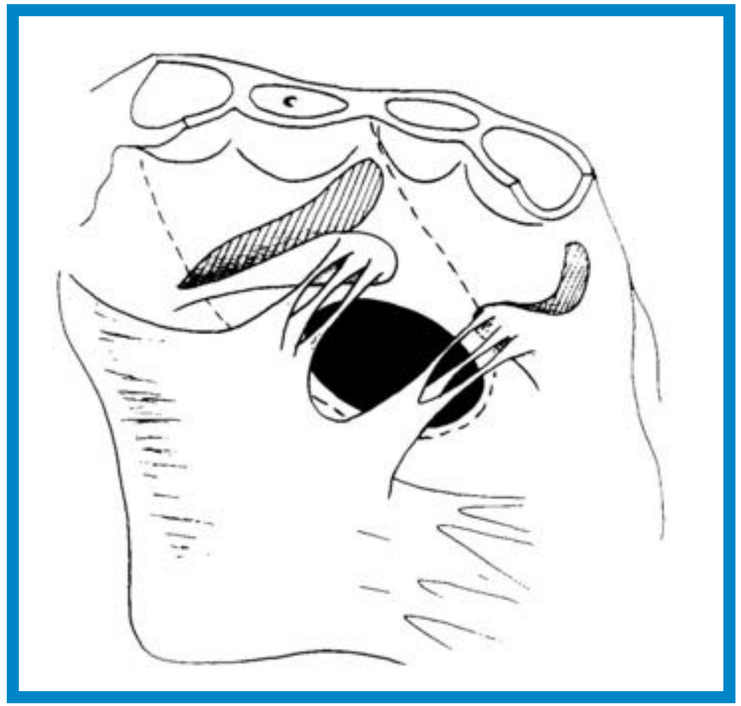

REV

CLICK TO ADD SUBTITLE

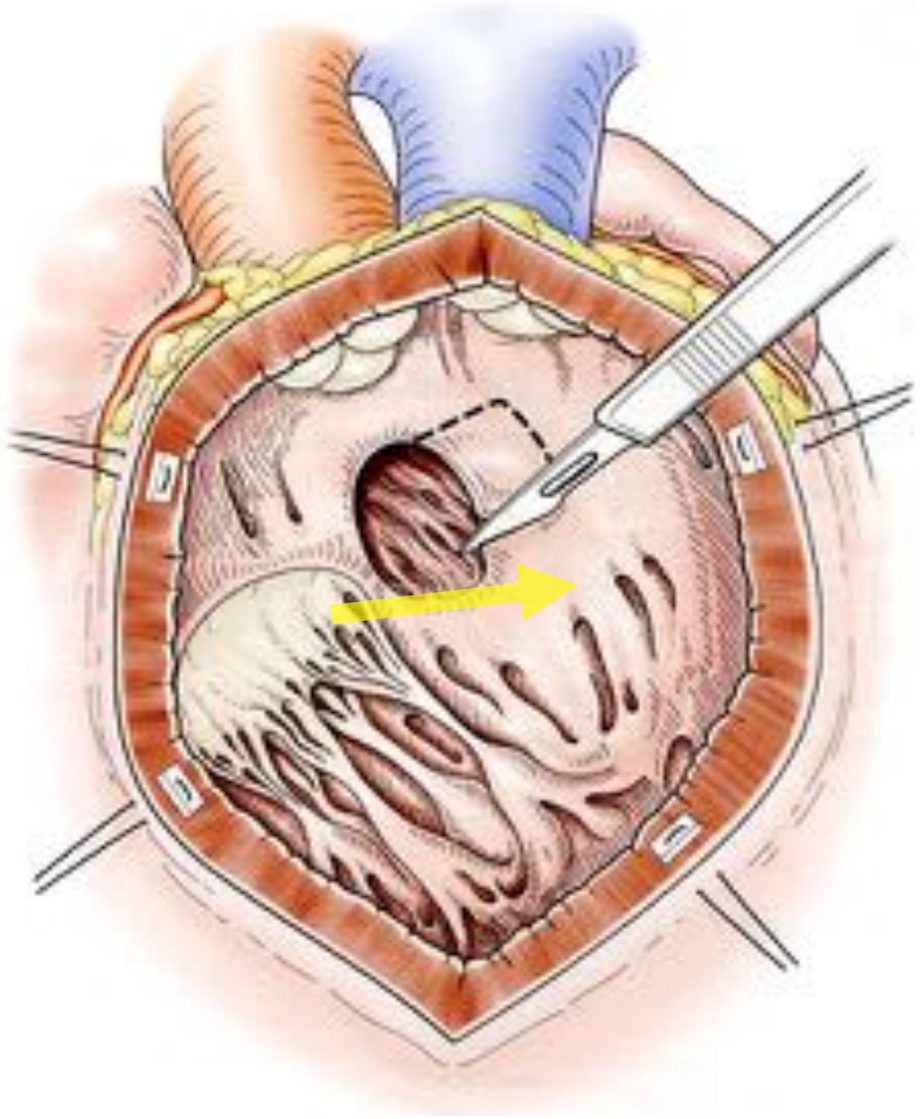

On peut élargir la CIV (vers l’avant)

REV

CLICK TO ADD SUBTITLE

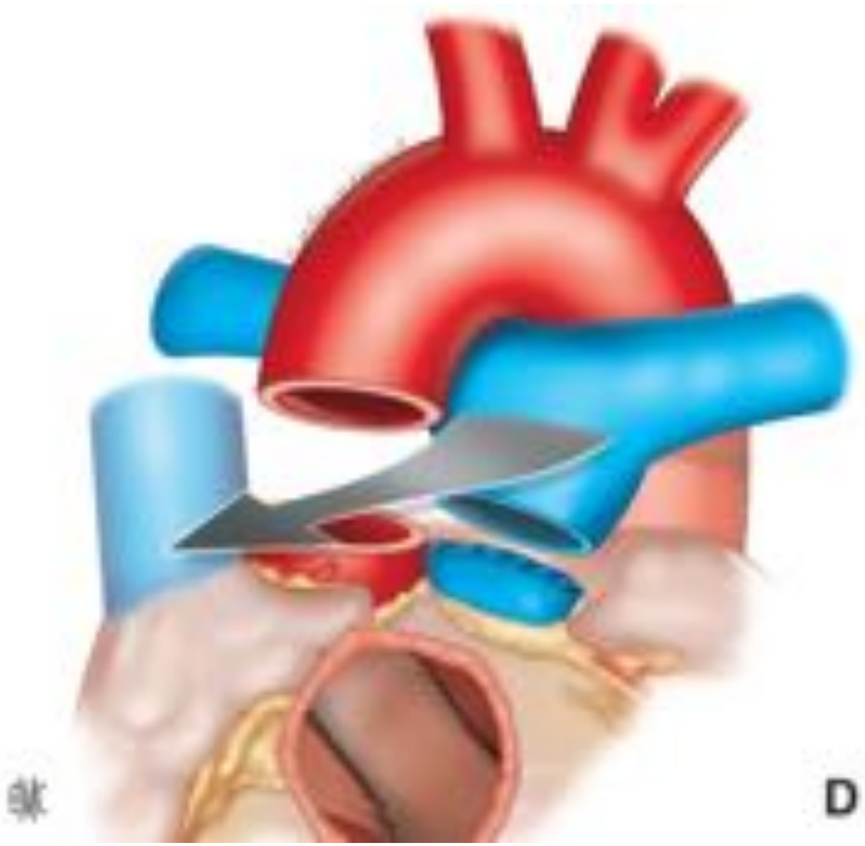

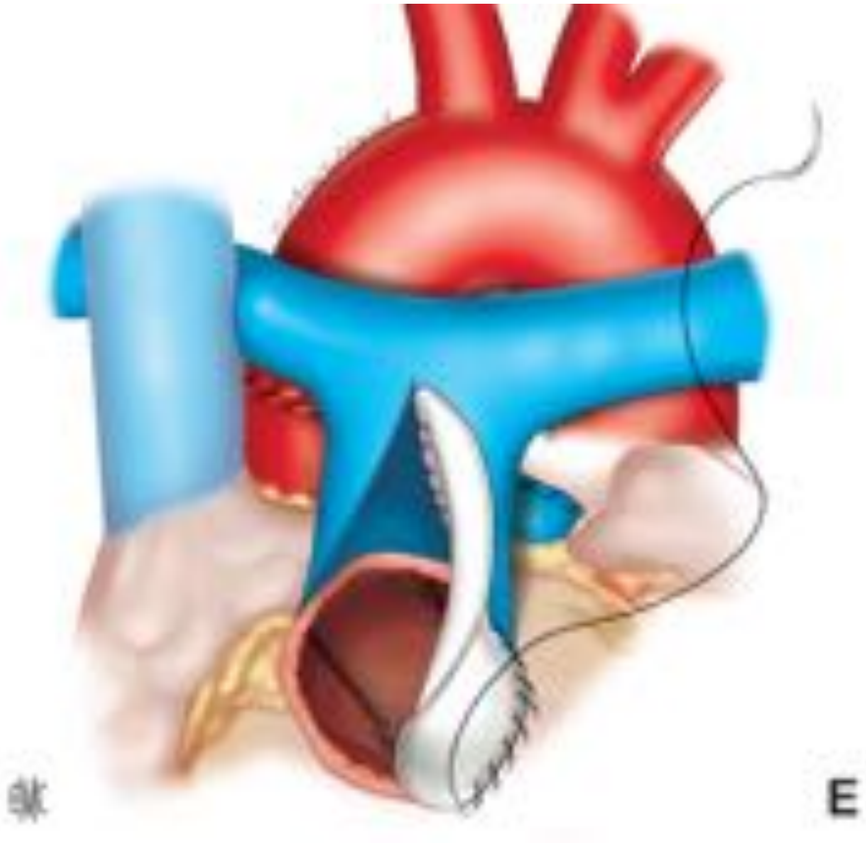

REV

CLICK TO ADD SUBTITLE

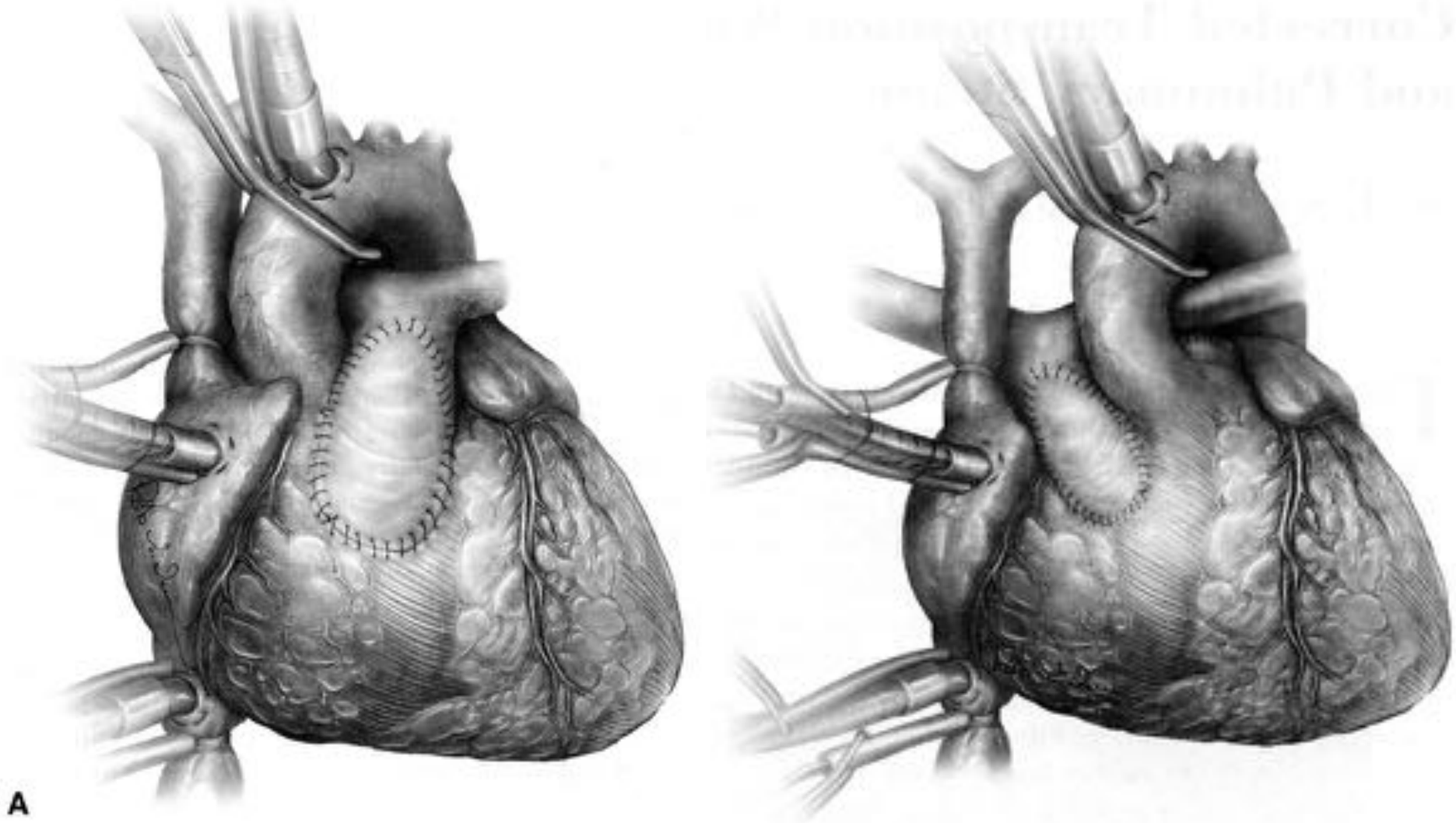

REV

CLICK TO ADD SUBTITLE

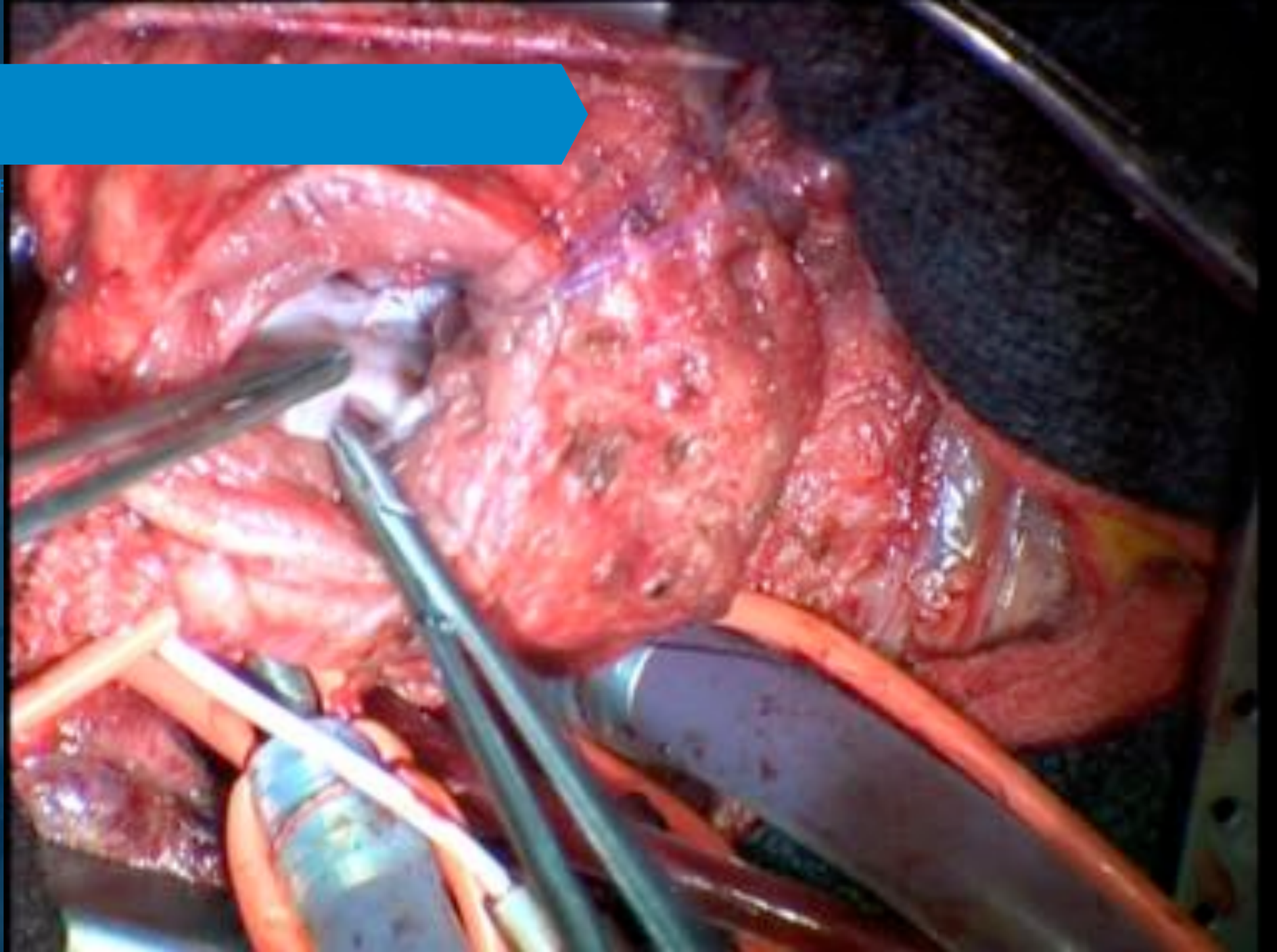

REV

CLICK TO ADD SUBTITLE

- ✓ Parfois impossible
  - CIV « non committed (inlet, trabeculée)
  - Anomalies valves AV(mitral valve)
  - hypoplasie VD
- ✓ Reduit quand même la taille du VD
- ✓ Reoperation
  - 50 % des patients à 25 ans

BEX - NIKAIDOH

CLICK TO ADD SUBTITLE

	VP normale	VP sténosée
Tric – Pulm > ø Ao.	IVR	IVR + élargissement VP
Tric – Pulm < ø Ao.	- VG - AP - switch	- Rastelli - REV - Bex-Nikaïdoh

BEX - NIKAIDOH

CLICK TO ADD SUBTITLE

	VP normale	VP sténosée
Tric – Pulm > ø Ao.	IVR	IVR + élargissement VP
Tric – Pulm < ø Ao.	- VG - AP - switch	- Rastelli - REV - Bex-Nikaïdoh

BEX - NIKAIDOH

CLICK TO ADD SUBTITLE

BEX - NIKAIDOH = Translocation aortique

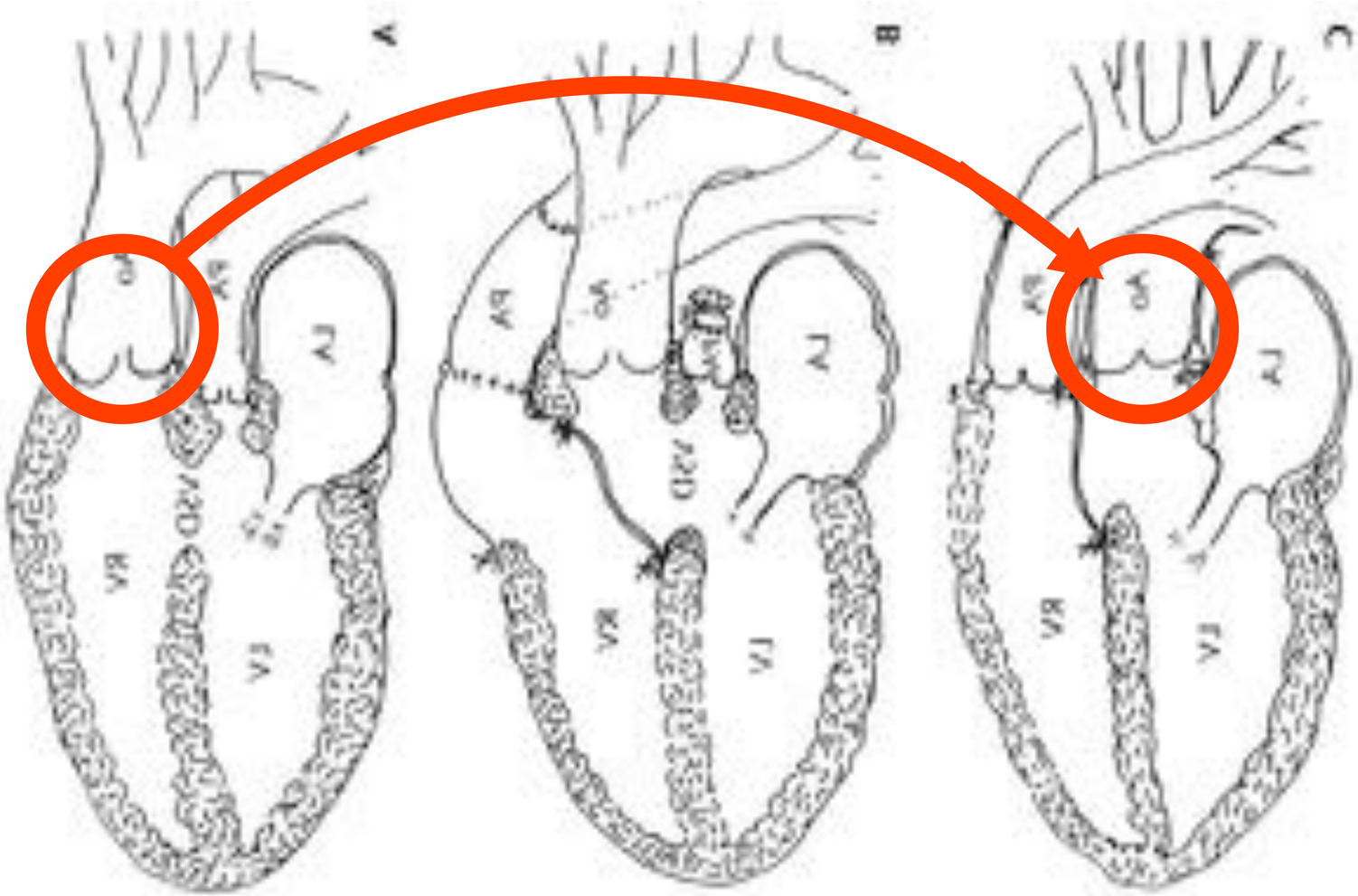

BEX - NIKAIDOH

CLICK TO ADD SUBTITLE

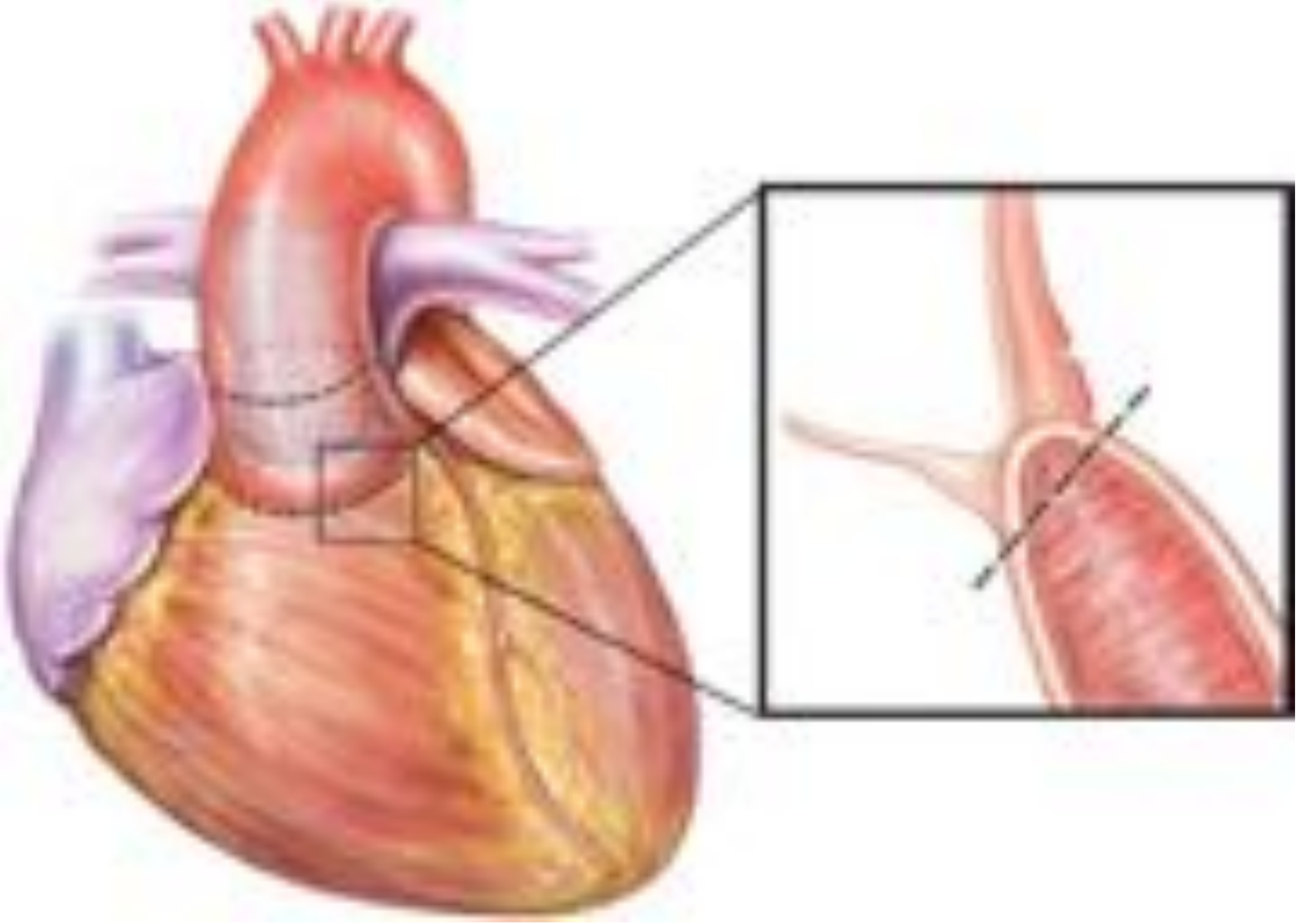

BEX - NIKAIDOH

CLICK TO ADD SUBTITLE

BEX - NIKAIDOH

CLICK TO ADD SUBTITLE

BEX - NIKAIDOH

CLICK TO ADD SUBTITLE

BEX - NIKAIDOH

CLICK TO ADD SUBTITLE

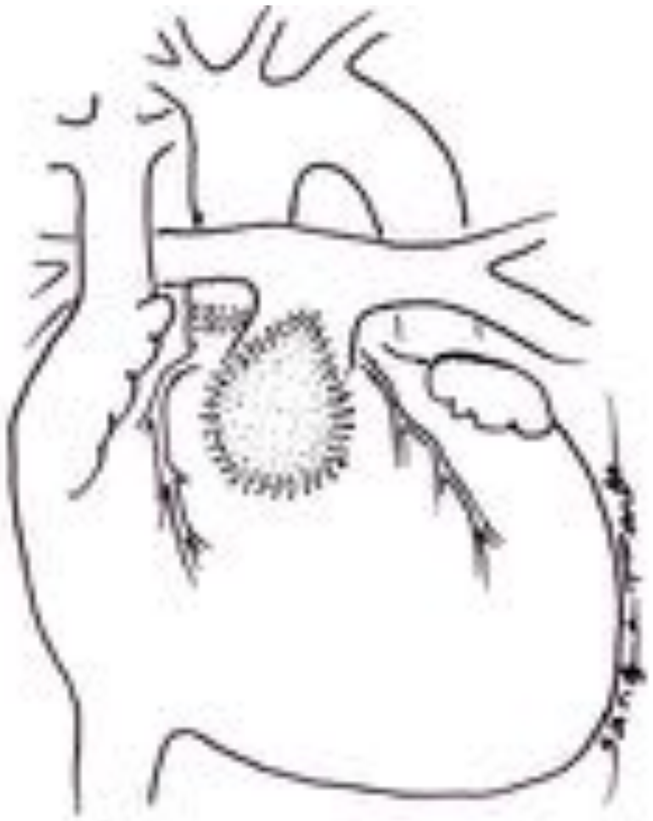

BEX - NIKAIDOH

CLICK TO ADD SUBTITLE

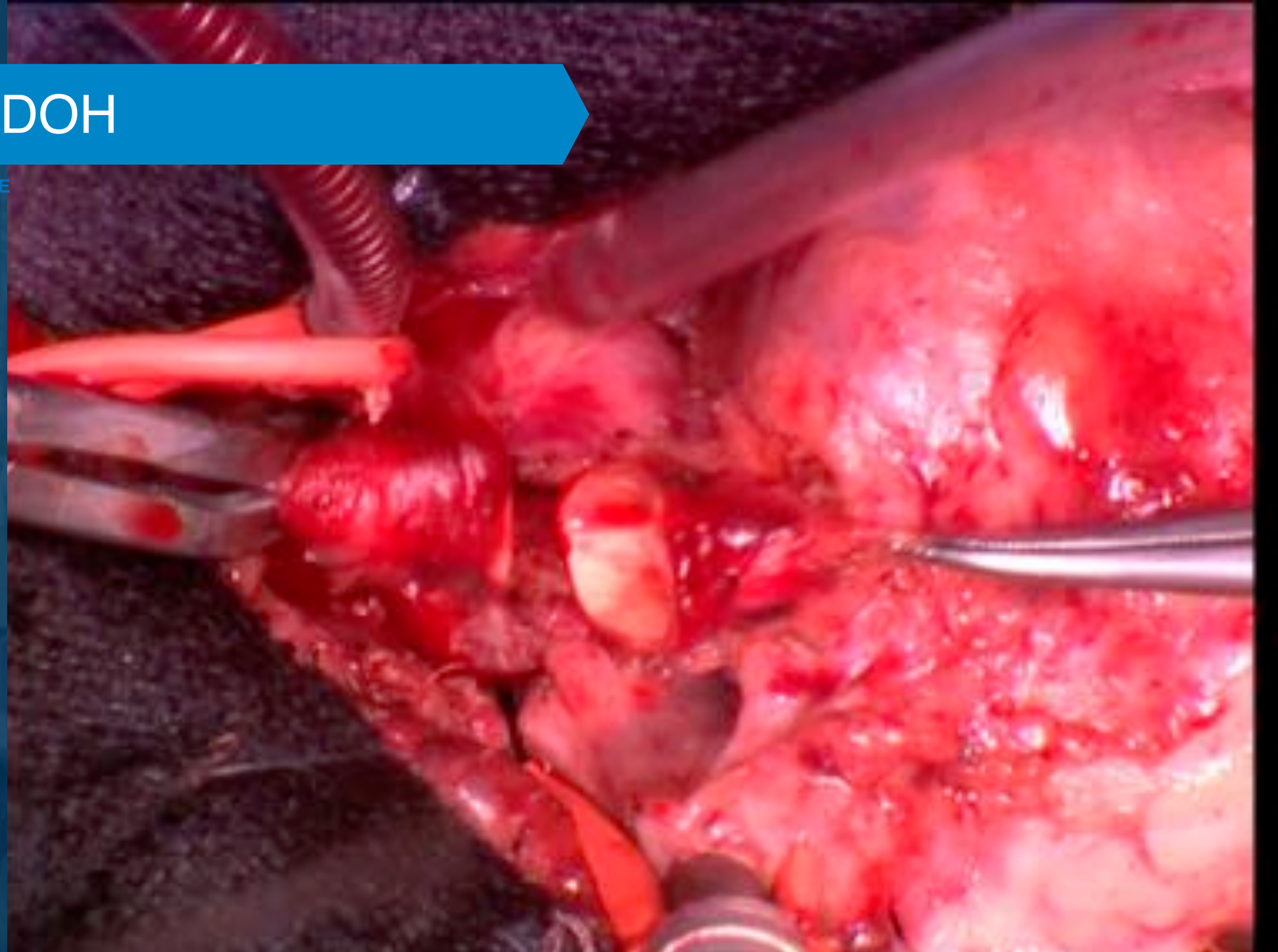

BEX - NIKAIDOH

CLICK TO ADD SUBTITLE

- ✓ possible dans certaines contre-indications du RE
  - CIV non committed
  - Pas de CIV (TGV-SP septum intact)
  - Anomalies valves AV
  - Hypoplasie VD
- ✓ Pas de risque de sténose sous-aortique
- ✓ Pas de réduction de la taille du VD

BEX - NIKAIDOH

CLICK TO ADD SUBTITLE

- ✓ Operation complexe
- ✓ impossible avec certaines anatomies coronaires
- ✓ reoperation pour la voie droite
  - Incidence élevée si conduit
  - Plus faible si réimplantation pulmonaire directe?
- ✓ problèmes potentiels à long terme ?
  - Devenir des artères coronaires réimplantées
  - Devenir de la valve aortique transloquée

Indications

CLICK TO ADD SUBTITLE

- ✓ REV indication de choix

- ✓ Indication du Bex-Nikaïdoh
  - REV difficile ou impossible (CIV, mitrale, coronaires)

- ✓ Indication du Rastelli
  - Artères pulmonaires petites ou resistance élevées ou non mobilisable

Rotation cono-troncale

CLICK TO ADD SUBTITLE

- ✓ IVR impossible
- ✓ REV et ASO impossibles
- ✓ Indication de Bex Nikaidoh
  - mais Valve pulmonaire utilisable
  - et anatomie coronaire favorable

→ Rotation cono-troncale

Rotation cono-troncale

CLICK TO ADD SUBTITLE

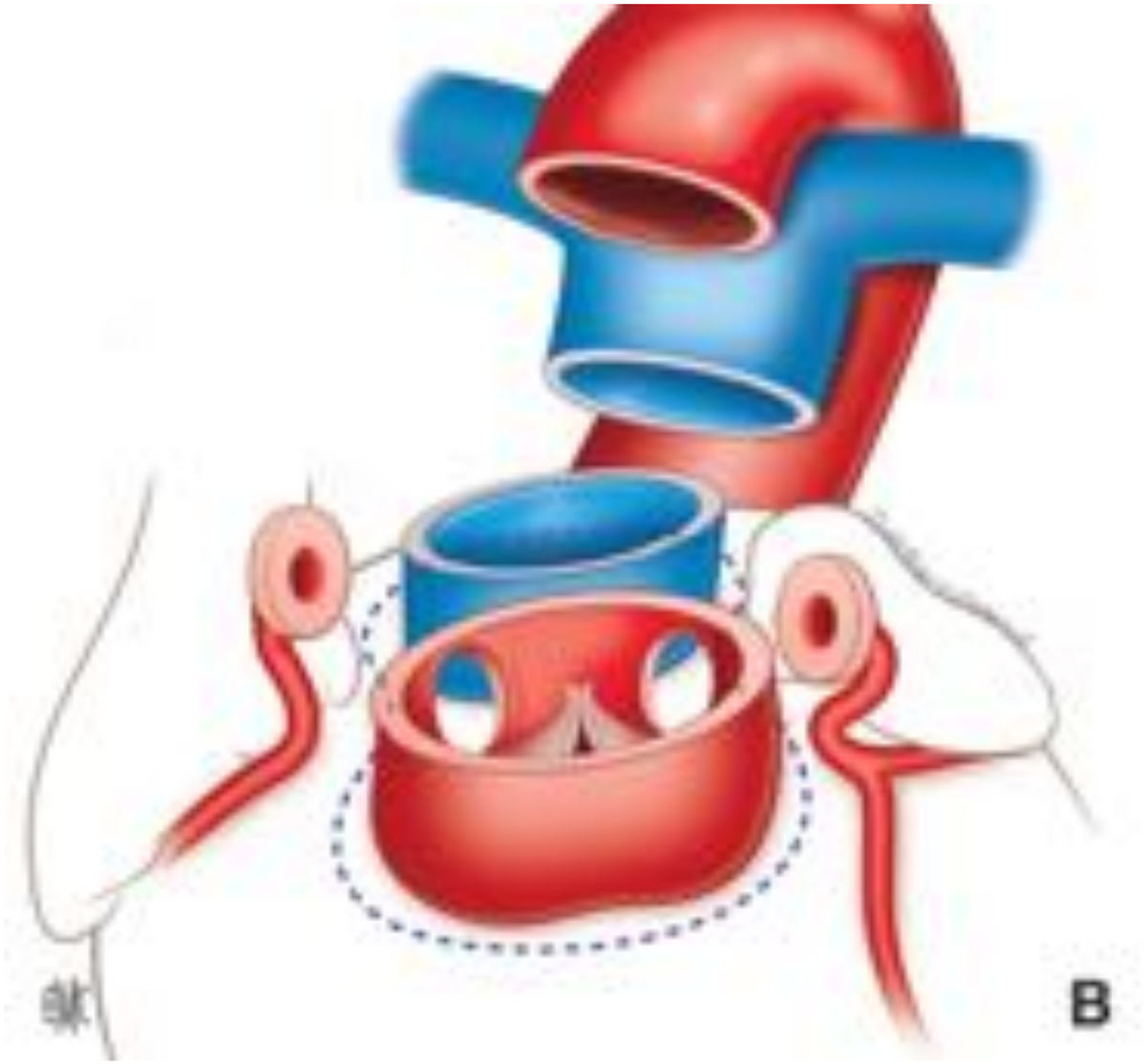

Rotation cono-troncale

CLICK TO ADD SUBTITLE

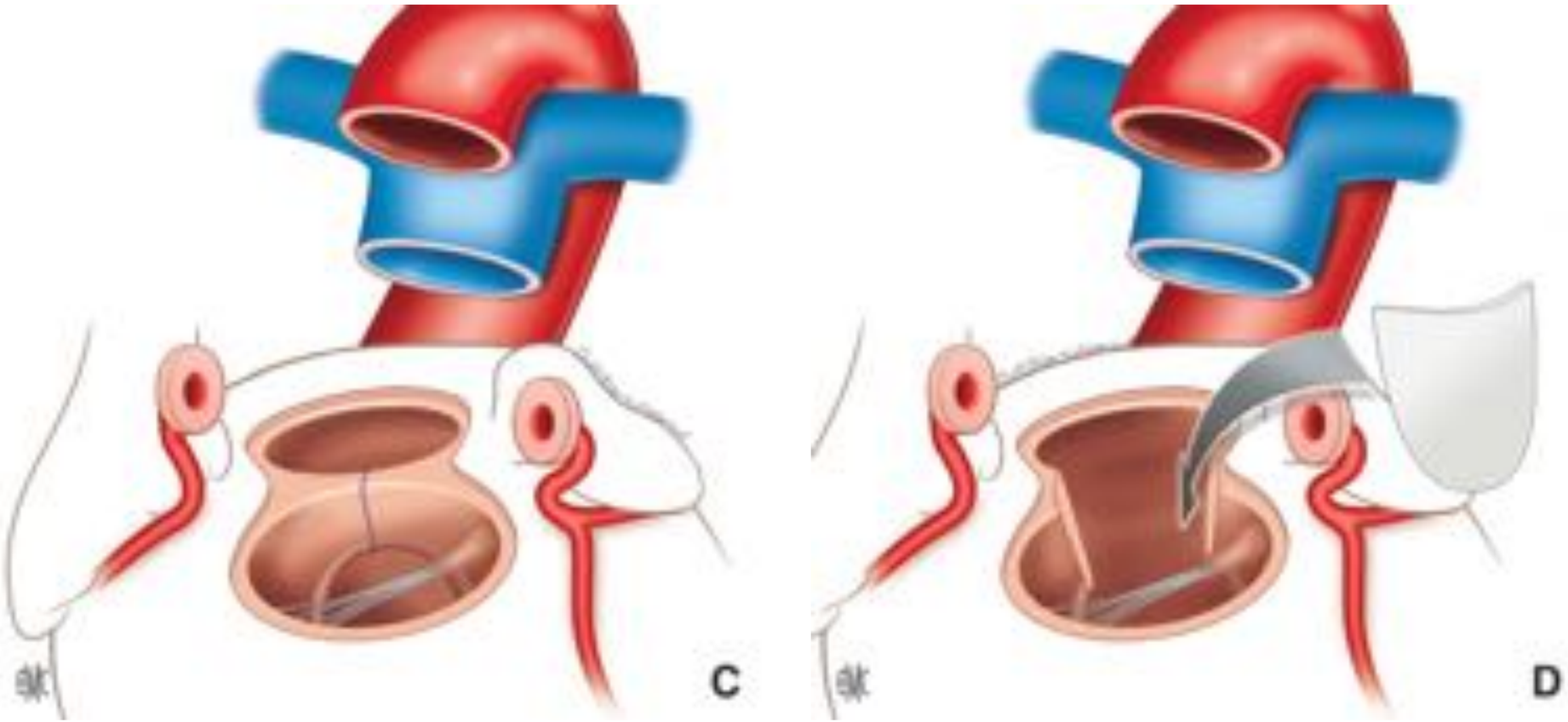

Rotation cono-troncale

CLICK TO ADD SUBTITLE

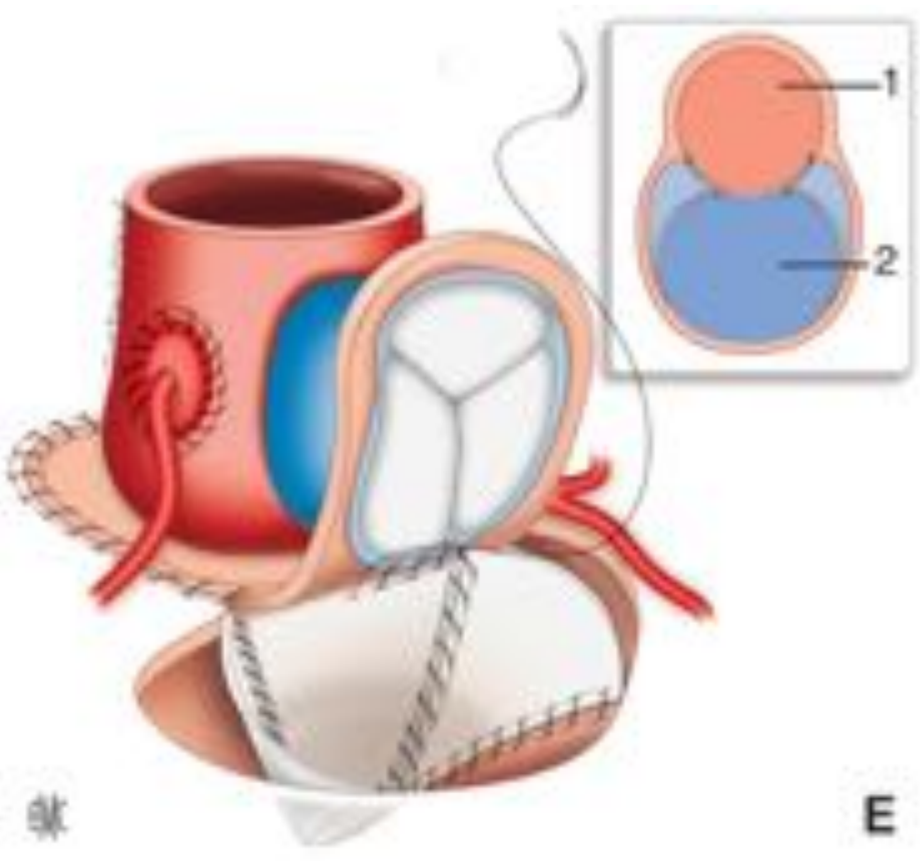

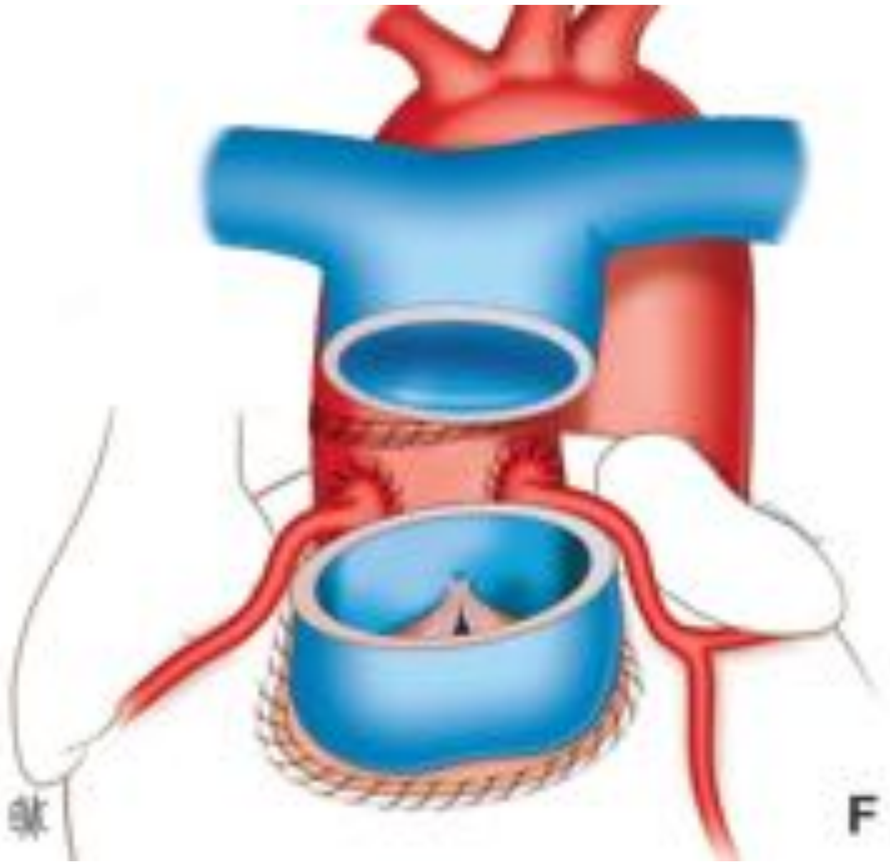

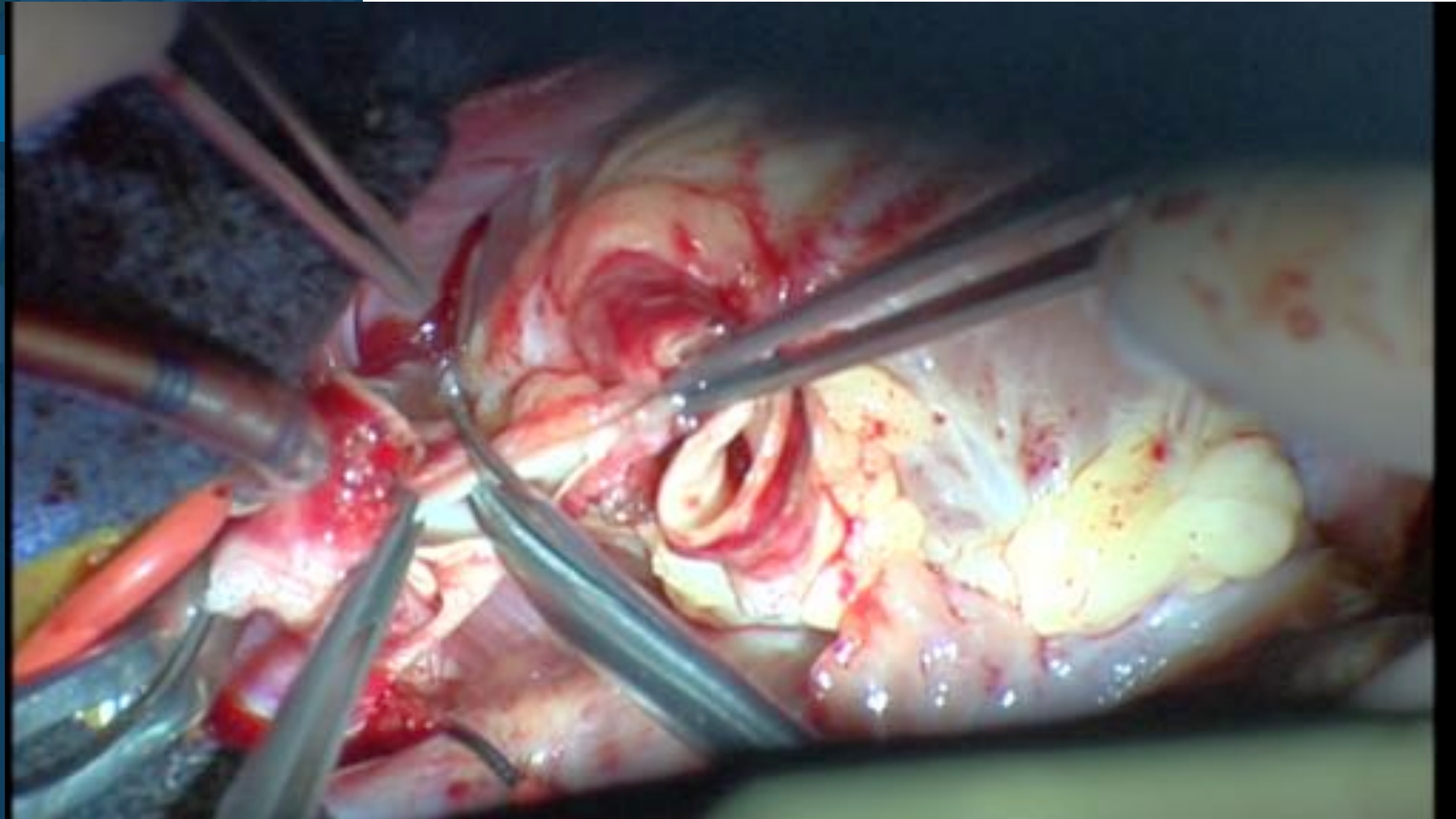

Rotation cono-troncale

CLICK TO ADD SUBTITLE

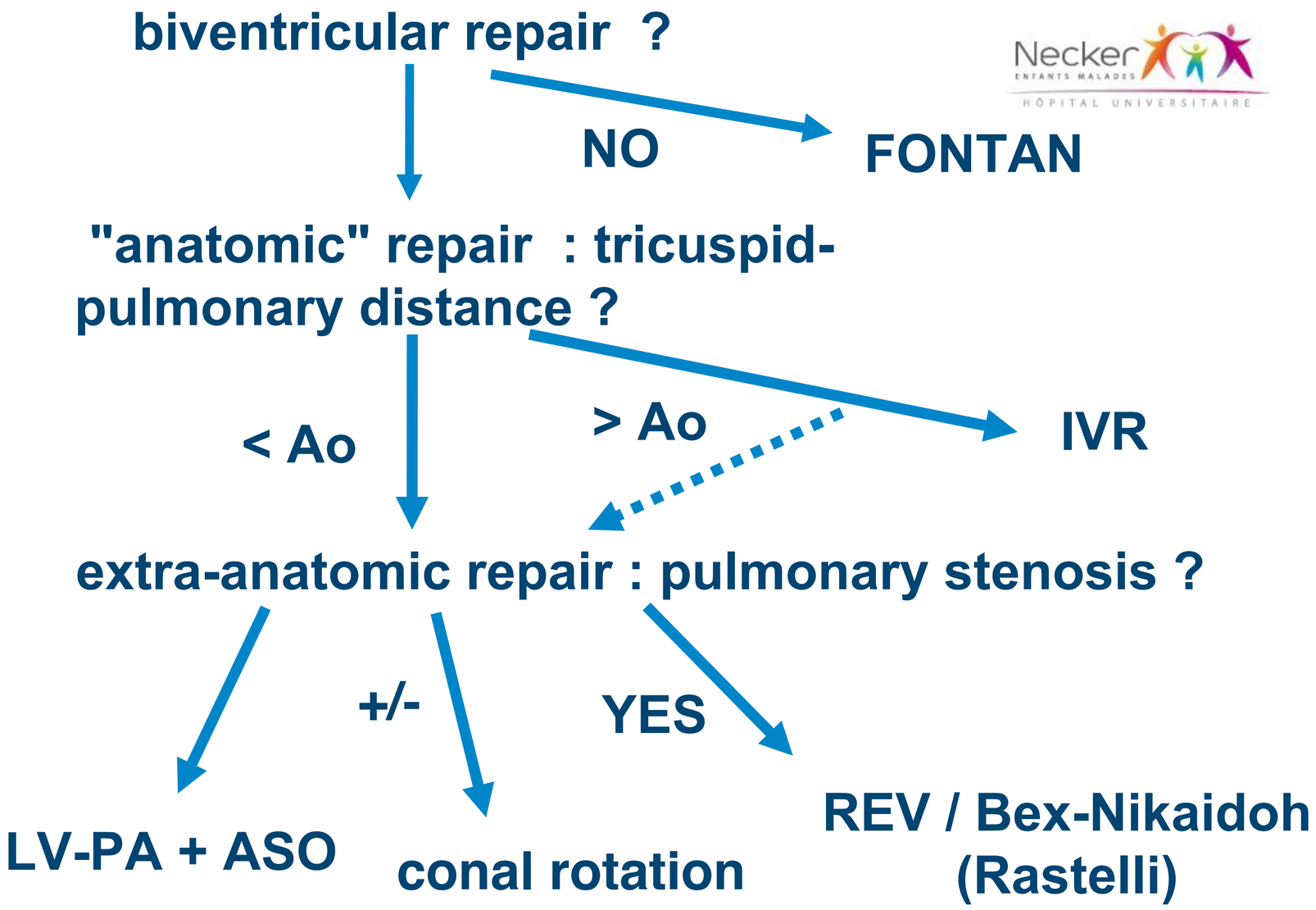

Arbre décisionnel

CLICK TO ADD SUBTITLE

Risque opératoire (2007-2014)

	NEM	EACTS
IVR	54 (0%)	530 (7%)
Rastelli	4 (0%)	105 (5.7%)
REV	41 (0%)	63 (4.8%)
Bex-Nikaïdoh	12 (8.3%)	37 (5.4%)
conal rotation	6 (0%)	---

Arigato